

Effect of Matrix Rhythm Therapy Integrated with Electrical Stimulation in Sub Acute Bell's palsy. A Case Report

Ansari Sadaf¹, Aleena Seneen², Pooja motar³

¹BPT, Student, MGM School of Physiotherapy, Aurangabad, a constituent unit of MGMIHS, Navi Mumbai, Maharashtra, India. Email.id -ansarisadaf884@gmail.com

²BPT, Student, MGM School of physiotherapy, Aurangabad, a constituent unit of MGMIHS, Navi Mumbai, Maharashtra, India. Email.id -maryamaleena111@gmail.com

³Assistant professor, MGM School of Physiotherapy, Aurangabad, a constituent unit of MGMIHS, Navi Mumbai, Maharashtra, India. Email.id -poojamotar5@gmail.com

ABSTRACT

Bell's palsy is an idiopathic condition caused by dysfunction in cranial nerve VII also known as facial nerve leading to unilateral lower motor paralysis of facial muscles. Many studies were published which showed conventional and recent advance treatment protocols for acute bell's palsy as compared to sub-acute bell's palsy. As, there was dearth in the literature for Matrix rhythm therapy in sub-acute Bell's Palsy. The present study aimed to evaluate the effect of matrix rhythm therapy combine with electrical stimulation in sub-acute Bell's palsy using House-Brackmann Scale. Matrix rhythm therapy is a recent advance modality which (MRT) helps to renew more Cellular logistics that is removal of waste products, embellish microcirculation of oxygenated blood, relaxes muscles and amplify the process of regeneration and healing. The intervention was given for 6 days which included patient education, matrix rhythm therapy with neuromuscular electrical stimulation. The study showed reduced scores in House - Brackmann scale indicating faster recovery in sub-acute bell's palsy..

Keywords:

Bell's Palsy, Matrix Rhythm Therapy (MRT), Electrical Stimulation, Physical Therapy

1.Introduction

Bell's palsy is named after Sir Charles Bell in 1774-1842.

Bell's palsy is an idiopathic condition caused by a dysfunction in cranial nerve VII also known as facial nerve, which supplies all the muscles of facial expressions. ^[1, 2]

The prevalence of Bell's palsy is about 23 per 100,000 annually accompanied by 40,000 new cases each year or about 1 in 60 to 70 people in a lifetime. There is equal incidence of both the gender (male/female).It can occur at any age, but most commonly seen in mid and late life with median age of onset at 40 years. Predisposing factors include Diabetes, Pregnancy, Obesity and Hypertension. ^[3]

Bell's palsy leads to vascular Distension, Inflammation and Edema with Ischemia of the facial nerve. The etiology remains unclear, various sources includes Viral, Inflammatory, Autoimmune and Vascular. ^[4]

Bell's palsy result in facial muscle paralysis on affected side of the face with features like resting asymmetry due to muscle weakness, drooping of eyelid, hyperacusis, painful auricle area and changes in taste. ^[5]

Literature showed many Conventional and Recent Advances in acute bell's palsy like electrical stimulation, tapping, PNF, Facial exercise, laser therapy, Acupuncture, Matrix rhythm therapy but there was dearth in literature for Sub-acute bell's palsy.

Dr. Randoll developed Matrix rhythm Therapy, Which has been a modern evolution in rehabilitation. Human cells are rhythmically pulsating in frequency of 8-12 Htz and maintain the physiological functions of the body. This alpha rhythm is basic requirement for ATP formation to initiate process of healing and tissue regeneration.MRT has shown to be effective in treatment of

movement dysfunction and pain. However, its potency in treating symptoms of sub acute Bell's Palsy is missing.^[6,7]

Thus Present study aimed to evaluate the effect of matrix rhythm therapy combine with electrical stimulation in sub-acute Bell's palsy using house-brackmann scale.

2. Case Description

Mr. Shaikh Irfan is a 42 years old male who works as a manager in company and spends 7-8 hours in an AC environment on computer.

The Patient came to hospital 2 months back with facial drooping on left side, difficulty in closing left eye, difficulty in flaring left side of nose and smiling .Also the taste sensations was absent at anterior two third of tongue. The patient had a positive family history (2 cases in Blood Relation, Father and Sister). The MRI brain revealed Tympanic and mastoid segments of left facial showed abnormal enhancement on post contrast study. The SD curve showed partial Denervation of left Orbiculari Occuli Muscle muscles. The Outcome measures was assessed pre and post intervention which are Strength duration curve and House -Brackmann facial nerve scale. The informed consent was taken before the study.

3. Intervention

A 6 days protocol was planned which included

1.Patient education -Mr. Shaikh Irfan was educated about his condition, the possible prognosis and the whole treatment protocol. The patient was instructed to wear protective goggles to prevent the foreign bodies into eye and to cover the ears to prevent the exposure to cold.

1. Matrix Rhythm Therapy-MRT was given for 45 minutes over the following areas

- From Frontalis muscle towards facial nerve junction on the affected side.
- From Nose towards the facial nerve junction.
- From Mentalis towards facial nerve junction.
- From Back of the ear towards the upper Trapezius muscle and drained into Axillary lymph nodes.

3. Electrical stimulation:-

The Interrupted galvanic current was given on the left facial muscles. [TABLE-1]

MUSCLES	NO. OF CONTRACTIONS	NO. OF SET
Frontalis	45	3
Corrugator	45	3
Orbicularis Oculi	45	3
Nasalis	45	3
Buccinators	45	3
Orbicularis Oris	45	3
Mentalis	45	3

The Surged faradic current was given on upper, middle and lower trunks of left facial nerve.

[TABLE-2]

TRUNK	NO. OF CONTRACTIONS	NO. OF SET
Upper	10	3
Middle	10	3
Lower	10	3

4. Results

The pre-intervention grade for House Brackmann scale was 5 which reduced to grade 3 post-Intervention. **[TABLE NO: 3]**

PRE-TREATMENT	POST- TREATMENT
<input type="checkbox"/> GRADE 5-SEVERE ✓ Gross: only slight barely noticeable movement. ✓ At rest : Asymmetrical facial appearance ✓ Motion: forehead no movement, incomplete eye closure, mouth slight movement	<input type="checkbox"/> GRADE 3-MODERATE ✓ Gross: obvious but not disfiguring facial asymmetry. ✓ At rest: normal tone and symmetry. ✓ Motion: forehead slight and moderate movement complete closure of eye with effort. ✓ Mouth slight weakness with maximum effort.

The improvement was also seen in SD-curve for left orbicularis oculi which was partially innervated pre intervention to innervated in post intervention. **[FIGURE:-1] [FIGURE:-2]**



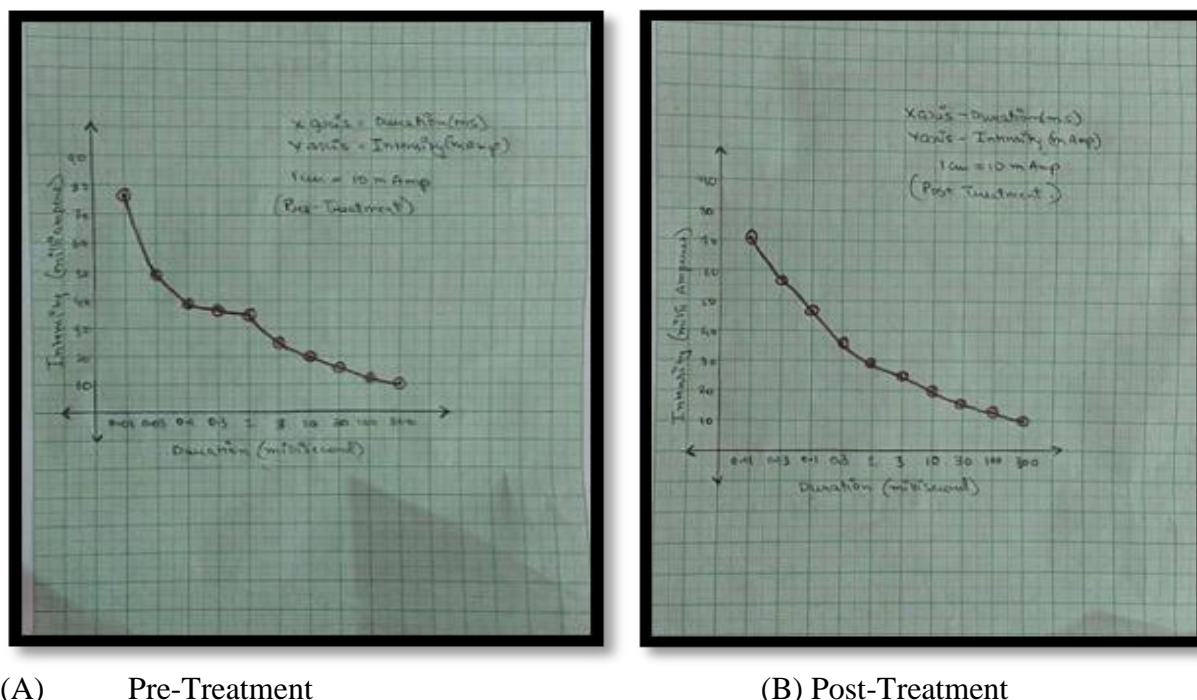
Treatment day 1



Treatment day 2

Figure:-1 Pre And Post Treatment

Figure:-2 Pre -Post Sd-CurveFor Left Orbicularis Occuli.



5. Discussion

In the present study patient was treated with Neuromuscular Stimulation with Interrupted Galvanic current for muscles and Surge Faradic current for trunk of the Facial Nerve respectively. The intensity of the Nerve stimulation was given as per the patient tolerance. As Matrix Rhythm Therapy is a recent advance in the field of Neuro-Physiotherapy which has shown to be effective in treating the weak muscles and restoring the function of muscles in Neuromuscular System. Hence, The recent case report addressed to evaluate the effect of Matrix Rhythm Therapy combined with Neuromuscular stimulation in Sub-acute Bells Palsy. In this study the treatment was administered for restoring the function of facial muscles due to Sub-acute Palsy and the present study showed improvement in-closure of eyelid's , raising of eyebrow and deviation of mouth .

A parallel Finding's was found in a study done on Acute Bells Palsy patient where Matrix Rhythm Therapy was combined with Conventional Physiotherapy. The study showed improvement in functions of facial muscles was faster as compared to others studies in which only Conventional Physiotherapy was given. ^[8]

A study was done by Tuncay F.et.al in which Neuromuscular Electrical Stimulation was given to 60 patients with Bells Palsy for 3 weeks and study showed improvement in function facial muscles. ^[9]

A Prospective Randomized study was done by Kim J et.al in which 60 patients was randomized into Electrical Stimulation and Medical Group. The study showed significant improvement in Electrical Stimulation group as compared with Medical Group. ^[10]As Neuromuscular training for facial muscles was also given at end of the intervention which could also be the reason for improvement in the functions of facial muscle . Brach JS et.al conducted a study in which

patients with unilateral Facial Nerve Disorders and Oral Synkinesis was included and neuromuscular training was given. The study showed significant improvement in Functions of facial muscles.^[11]

6. Conclusion

The present case report of Sub acute Bells palsy treated with combination of Matrix rhythm therapy and conventional physiotherapy showed an adequate improvement in functions of facial muscles .The matrix rhythm therapy can be considered as effective therapeutic intervention in case of sub acute Bells palsy for faster recovery .

List of abbreviations

MRT - Matrix Rhythm Therapy

PNF- *Proprioceptive Neuromuscular Facilitation*

ATP-*Adenosine Triphosphate*

SD curve- Strength Duration Curve

Acknowledgement The authors thank all the participants of the study for their co-operation.

Source of Funding None.

Conflict of Interest The authors declare no conflict of interest.

References

- [1] Physiopedia Bell's palsy. Available from: https://www.physio-pedia.com/Bell%27s_Palsy (accessed 8 May 2020).
- [2] Jeffrey D. Tiemstra, MD, and Nandini Khatkhate MD. Bell's Palsy: Diagnosis and Management University of Illinois at Chicago College of Medicine, Chicago, Illinois Am fam Physician. 2007 Oct 1; 76(7):997-1002.
- [3] Zhao H, Zhang X, Tang YD, Zhu J, Wang XH, Li ST. Bell's Palsy: Clinical Analysis of 372 Cases and Review of Related Literature. Eur Neurol. 2017; 77(3-4):168-172. [Pub-Med].
- [4] Dhruvashree Somasundara, General practitioner¹ and Frank Sullivan, Gordon F Cheesbrough research chair, Director of Utopian FMTU², Professor³ and Adjunct scientist⁴. Aust preser. 2017.jun, 40(3):94-97.
- [5] Cotton BA. Chiropractic care of a 47-year-old woman with chronic Bell's palsy: A case study. J Chiropr Med, 2011; 10: 288-93.
- [6] FAQ | Matrix Rhythm Therapy, India <http://marhythe.in/faq/>.
- [7] Varunnaik, Basavarajmotimath, Tanvipathania .Application of matrix rhythm therapy as a novel treatment in trigeminal neuralgia. KAHAR institute of physiotherapy, Nehru nagar, Belagavi, Karnataka, India. 2020.nov.vol :2 issue:2:141-143.
- [8] Dr. Ketan Bhatikar. Effect of matrix rhythm therapy and facial neuromuscular retraining program in Bell's Palsy: case report, Medical Director, Dr. K. B Sports Physiotherapy and Aqua Rehabilitation Center, European journal of pharmaceutical and medical research, 2018,5(11),280-283.
- [9] Tuncay F, Borman P, Taser B, Ünlü I, Samim E. Role of electrical stimulation added to

- conventional Therapy in patients with idiopathic facial Bell's palsy. American journal of physical medicine & Rehabilitation, 2015 Mar 1; 94(3): 222-8
- [10] Kim J, Choi JY. The effect of subthreshold continuous electrical stimulation on the facial function of patients with Bell's palsy. Acta oto laryngologica , 2016 Jan 2; 136(1): 100-5.
- [11] Brach JS, Van Swearingen JM, Lenert J, Johnson PC. Facial neuromuscular retraining for oral synkinesis. Plastic and reconstructive surgery, 1997 Jun; 99(7): 1922-31)