

Physical Assessment of Keratometric(k1.k2)Outcomes after Crosslinking Followed by Intrastromal Ring Implantation by using Femtosecond Laser in Patients withKeratoconus

ShymaaKawamKhodaier¹, Dr. RashaSabeeh Ahmed², Dr. Aber Abdul Amir Mohamad³

¹B. S. Optician at Health and Medical Technical College, Baghdad,Iraq

²PhDLecturer Medical physics, College of Medicine, Al-Nahrain University, Iraq

³ F.I.C. M.S (Ophthalmology),Lecturer at College of Medicine, Al-Nahrain University, Iraq

E-mails:altaeemastersh@gmail.comrasha.sabeeh.ahmed@colmed-alnahrain.edu.iq, aabl_81@yahoo.com

Abstract

Background: Keratoconus is a disorder involving the cornea, presenting with central or paracentral corneal thinning progressively, the steepened cornea causes irregular astigmatism. For progressive cases of keratoconus, the primary treatment consists of corneal collagen cross-linking (CXL), this minimal invasive procedure aims to stabilize the coning by inducing stiffness of corneal stroma through fashioning of more cross-link bonds between the stromal collagen fibers. However, in order to correct the visual acuity, additional options should be sought, that includes refractive surgeries like intra-corneal rings segment (ICRS).

Aims: To physically assess the changes in corneal curvature (K readings) after 3 months of the cross-linking procedure and then after 3 months of intrastromal corneal segment ring implantation by femtosecond laser in a sample of Iraqi patients with keratoconus.

Methodology: The study was done in Dar Alsalam Private Hospital in Iraq/ Baghdad from 1-September-2019 to 1-October-2020. The study enrolled 40 patients (40 eyes) with keratoconus who had under gone corneal crosslinking then followed-up for three months, then had underwent intra-stromal corneal Keraring implantation with the aid of femtosecond laser, then followed-up for another three months, and after each time-interval the assessment included changes in corneal curvatures (K1 and K2).

Results: The mean age of participants was 25.58 ± 6.08 years, with 18 (45%) males and 22 (55%) females. There was a statistically significant difference decrease in K1 and K2 reading following CXL by 0.5% (0.24 D) and 0.53% (0.28 D), respectively, while three

months after ICRS K1 and K2 significantly decreased by 1.28% (0.60 D) and 8.69% (4.57 D).

Conclusions: Collagen crosslinking offered significant stabilization of corneal curvature and refraction and prevent further progression of the condition. Femtosecond laser can effectively create corneal incisions on corneas that had collagen crosslinking before three months. Intra stromal corneal rings (Keraring) can safely be done after collagen crosslinking with excellent outcomes regarding keratometry and refraction.

Keywords: Keratoconus, crosslinking, femtosecond laser, intracorneal ring segments

Introduction:

Keratoconus is a non-inflammatory degenerative condition in which collagen fibres within the cornea weaken and progressively thin ⁽¹⁾. The breakdown of the fibres means that the normal corneal structure will no longer be preserved. It is helpful to note here that this disorder is also Known as bulging cornea, conical cornea and KC. In general, these unusual conditions worse overtime, causing many side effects, such as: blurred vision, sensitivity to light, glare, myopia, astigmatism, diplopia ⁽²⁾. Treatment options could include glasses or even contact lenses are adequate for non-developed cases, while for higher astigmatism degrees, contact lenses rigid type, sometimes, are needed to give a uniform refracting surface. Collagen cross-linking may stop ectasia, but is not without side effects. Sometimes, cross-linking can be combined with ring segment insertion and it is usually used only for developed to improve visual function⁽³⁾.

Aims of the study: To physically assess the changes in corneal curvature (K readings) after 3 months of the cross-linking procedure and then after 3 months of intrastromal corneal segment ring implantation by femtosecond laser in a sample of Iraqi patients with keratoconus.

Patients and methods: A follow up study (cohort study) that took place in Dar Alsalam Private Hospital in Iraq/ Baghdad from first of September, 2019 to 1 October 2020. The study enrolled 40 patients (40 eyes) with keratoconus who had corneal crosslinking then followed-up for three months (first time interval) and had underwent intra-corneal ring segment “Keraring” (Mediphacos Inc., Belo Horizonte, Brazil) implantation by femtosecond laser (Ziemer Z8 Machine) then followed-up for another three months (second time interval), and after each time-interval the assessment included changes in corneal curvatures (K1 and K2), refraction. The target population for this study were patients already diagnosed with keratoconus and prepared for corneal crosslinking and intra-stromal corneal Keraring. In the current study, refraction and keratometry were examined by Auto Refraction Keratometer (ARK) (Nidek, Made in Japan, 2019) for manifest refraction and Sirius (Costruzione Strumenti Oftalmici, Florence, Italy) that

combines placid disk topography with Scheimpflug tomography for measuring keratometry and corneal astigmatism.

Inclusion criteria: Patients aged 18-36 years. Both genders. Diagnosed with progressive KCN stages mild (<48 D) and moderate (48-54 D). Thinnest corneal thickness of at least 400 μ m. No corneal scar. Intolerance of contact lenses. No history of ocular surgery

Exclusion criteria: Cataract, retinal diseases, corneal scarring, pregnant women, diabetic patients. Vogt striate. Herpetic keratitis or/and other active ocular infection. Patients with dry eye disease.

Statistical analysis: All statistical analysis done by using SPSS 22, mean, standard deviation and frequency of all descriptive data done by it. Analysis of data done by using Wilcoxon Test for continuous variables with not had normal distribution. Pearson Correlation also used to show correlation between variables if positive or negative. P-value considered significant if equal or less than 0.05.

Results:

A total of 22 (55%) females and 18 (45%) males, with mean \pm SD age of (25.58 \pm 6.08) ranging from 16- to 43-year-old, 8 (20%) of them had an age below 20 years (16-19 years), 10 (25%) patients aged 20-24 years, 12 (30%) aged 24-29 years, and 10 (25%) patients aged \geq 30 years, as shown in Table 1.

Table (1): Basic characteristics of the study sample

Variables	Statistics	
Age		
Mean± SD	25.58±6.08	
Median	25	
Min	16	
Max	43	
Age groups	Number	%
<20 years	8	20.0
20-24 years	10	25.0
24-29 years	12	30.0
≥30 years	10	25.0
Gender		
Males	18	45.0
Female	22	55.0
Total	40	100.0

The mean \pm SD value of corneal curvature (K1) before correction was found to be 46.32 ± 3.1 Diopter (D) with minimum value of 42.0 D and maximum value of 54.4 D. After 3 months of keratoconus correction, the mean value of K1 was found to be 46.08 ± 3.1 with minimum value of 42.0 D and maximum value of 54.1 D ($p=0.001$). After 3 months of ring implantation a significant improvement was observed as the mean value was found to be 45.48 ± 3.0 with minimum value of 41.7 D and maximum value of 53.0 D ($p=0.001$) as seen in Table 2.

Table (2): Keratometry (K1) pre- and post-surgery

Variables	Baseline	After CXL	After ICRS	P-value		
	Mean ±SD	Mean ±SD	Mean ±SD	Baseline/ after CXL	After CXL/ after ICRS	Baseline/ after ICRS
K1	46.32±3.1	46.08±3.1	45.48±3	<.001	<.001	<.001
				Difference= 0.24 D	Difference= 0.60 D	Difference= 0.83 D
Paired Samples T-test						

The mean \pm SD value of corneal curvature (K2) before correction was found to be 52.36 ± 4.0 D with minimum value of 47.0 D and maximum value of 60.5 D. After 3 months of keratoconus correction, the mean value of K2 was found to be 52.08 ± 4.0 with minimum value of 47.0 D and maximum value of 60.4 D ($p=0.001$). After six months of ring implantation a significant improvement was observed as the mean value was found to be 47.51 ± 3.1 with minimum value of 43.0 D and maximum value of 55.1 D ($p=0.001$) as seen in Table (3). Figure 1 summarizes the results obtained in tables 2 and 3 and illustrated the improvement in k1 and k2 values and illustrate clearly the improvement in K2 values.

Table (3): Keratometry (K2) pre- and post-surgery

Variables	Baseline	After CXL	After ICRS	P-value		
	Mean ±SD	Mean ±SD	Mean ±SD	Baseline/ after CXL	After CXL/ after ICRS	Baseline/ after ICRS
K2	52.36±4.1	52.08±4	47.51±3.2	<.001	<.001	<.001
				Difference= 0.28 D	Difference = 4.57 D	Difference= 4.85 D
Paired Samples T-test						

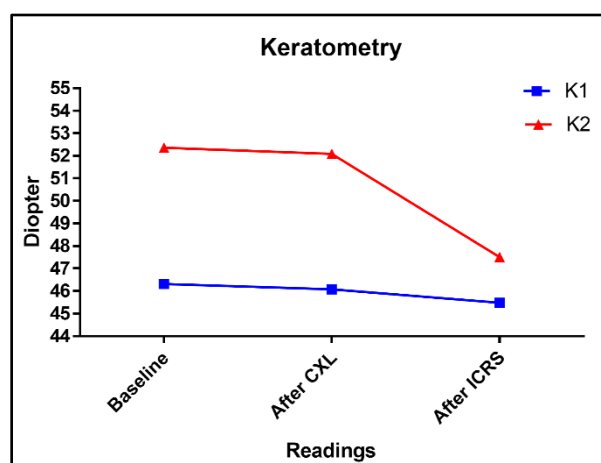


Figure (1): Follow-up of patients according to the mean keratometry readings

The mean percent of change in K1 and K2 after CXL was a reduction of 0.51% and 0.53%, respectively, however after ICRS K1 decreased by a 1.28% compared to K1 after CXL, and by 1.79% compared to baseline-K1. K2 decreased more than K1, as after ICRS K2 decreased by 8.69% compared to K2 after CXL and 9.23% compared to baseline-K2. As shown in Table 4.

Table (4) Keratometry percent of change throughout the study period

Variables	Mean	Median	Min, Max	P-value
K1				
Baseline/ after CXL	0.51	0.44	-0.23, 1.8	<.001
After CXL/ after ICRS	1.28	1.14	0.00, 2.29	
Baseline/ after ICRS	1.79	1.75	0.00, 3.37	
K2				
Baseline/ after CXL	0.53	0.41	-0.21, 1.63	<.001
After CXL/ after ICRS	8.69	8.47	5.36, 12.94	
Baseline/ after ICRS	9.23	8.90	5.58, 13.77	
Friedman Test				

Discussion:

ICRS imbedding considered being less invasive, harmless and effective technique that may postponement or even evade the necessity for keratoplasty in patients with KC with an important improvement in UCVA ^(4, 5). ICRS imbedding centrally to give more corneal flattening at 5 mm diameter all this lead to high effective improvement of KC ⁽⁶⁾. During ICRS, imbedding for tunnel formation used Femtosecond laser besides mechanical segmentation ⁽⁷⁾.

In our study 22 (55%) females and 18 (45%) males, with mean age of (25.58 ± 6.08) years ranging from 16 to 43 years, these results were consistent with results of a study done by Alio et al. (2014) in Spain, that reported a mean age of 29.76 ± 8.84 years ranging from 15 to 56 years for 35 patients with stable KC⁽⁸⁾. In another study done by Heikal et al. (2017) in Egypt the mean age of the 20 patients enrolled in their studies was (27.43 ± 3.57) years with 55% females and 45% males⁽⁹⁾. Also, in Egypt, Mounir et al. (2018) studied 417 patients with KC undergoing Keraring implantation, and reported a mean age of 22.27 ± 4.54 years ranging from 18 to 37 years, with 50.6% females and 49.4% males. This is attributed to the natural age of KC onset and progression, as it usually onset in early adolescence and progress during third and fourth decade of life⁽¹⁰⁾, rarely it start in older age⁽¹¹⁾. The role of gender in KC is still not clear, with different reports stating different results, for example, Fink et al. (2010) reported that gender does not influence the progression of KC⁽¹²⁾, while others reported female predominance and others reported male predominance⁽¹³⁾. In addition, external factors could be the culprit in observed differences between males and females, for example, Hodge et al. (2018) in Australia reported that male patients practice eye rubbing and suffer from atopy significantly more than females⁽¹⁴⁾.

There was a statistically significant difference decrease in K1 and K2 reading following CXL by 0.5% (0.24 D) and 0.53% (0.28 D), respectively, while after ICRS K1 and K2 significantly decreased by 1.28% (0.60 D) and 8.69% (4.57 D) three months after CXL. These results were not consistent with results of Henriquez et al. (2012) in Peru, who reported that after 6 months from CXL, the K1 and K2 showed no statistically significant changes, however, similar to our results, they showed that 6 months after ICRS the K1 significantly decreased by 5.58 D and K2 by 4.17 D⁽¹⁵⁾. Also, Saib et al. (2015) in France reported that CXL followed by ICRS after 4.3 months resulted in significant improvement of mean K reading from 44.8D to 42.5 D⁽¹⁶⁾. Our results were very consistent with a study done by Renesto et al. (2012) in Brazil, and reported that three months after ICRS with prior CXL the flat reading reduced by 2.07D for flat K, 4.13D for steep K, and 1.04D for mean K⁽¹⁷⁾. In Egypt by Saleem et al. (2018) studied 43 eyes of 38 individuals with KC, and did femtosecond laser guided Keraring insertion followed by CXL directly at the same session, and reported that after 36 months (three years) K1 significantly decrease from $46.94 \pm 0.26D$ to $46.45 \pm 0.98D$, and K1 significantly decreased from $54.38 \pm 1.17D$ to $47.39 \pm 0.62D$ ⁽¹⁸⁾. The CXL causes structural changes to corneal stroma, and it might require to increase the power of femtosecond laser in order to overcome the closely-packed collagen fibers after CXL, and this was reported by El-Raggal (2011) in Egypt, stating that femtosecond laser power should be increased from 1.5 to 1.6 mJ or 1.7 mJ in order to fashion the tract for ICRS efficiently⁽¹⁹⁾, and the same investigator latter in that year undertook a study implanting Kerarings and after 6 months done CXL in comparison same session operation, however, he reported that same-session resulted in better corneal topography outcomes⁽²⁰⁾. ICRS

has some stabilizing effects upon corneal biomechanics, however this effects last only about 6 months, and it's role is mainly to correct refraction and improve vision (21), which is not enough to halt the progression of KC, which necessities CXL, that stiffens the otherwise weak and flaccid corneal stroma⁽¹⁰⁾.

Limitations:

1. The main limitation of this study is the lack of complete follow-up for some patients due to the covid-19 pandemic, which led to a shortage in the sample size for this research.
2. KC considered as a rare disease
3. The duration between two procedures was three months, and some patients didn't come back for examination. And in some times they didn't do the other procedure

Conclusions:

1. Collagen crosslinking offered significant stabilization of corneal curvature and refraction and prevent further progression of the condition.
2. Femtosecond laser can effectively create corneal incisions on corneas that had collagen crosslinking before three months.
3. Intra corneal ring segment (Keraring) can safely be done after collagen crosslinking with excellent outcomes regarding keratometry and refraction.

Conflict of interests: The authors declare no conflict of interests.

References

1. Volatier TLA, Figueiredo FC, Cannon CJ. Keratoconus at a Molecular Level: A Review. 2020;303(6):1680-8.
2. Belin MW, Boyd BM, Ambrosio R. Pellucid marginal degeneration vs inferior keratoconus: why it matters. Journal of cataract and refractive surgery. 2020;46(2):325-6.
3. Andreanos KD, Hashemi K, Petrelli M, Droutsas K, Georgalas I, Kymionis GD. Keratoconus treatment algorithm. Ophthalmology and therapy. 2017;6(2):245-62.
4. Giacomini NT, Mello GR, Medeiros CS, Kiliç A, Serpe CC, Almeida HG, et al. Intracorneal ring segments implantation for corneal ectasia. Journal of Refractive Surgery. 2016;32(12):829-39.
5. Koh IH, Seo KY, Park SB, Yang H, Kim I, Kim JS, et al. One-year efficacy and safety of combined photorefractive keratectomy and accelerated corneal collagen cross-linking after Intacs SK intracorneal ring segment implantation in moderate keratoconus. BioMed research international. 2019;2019.

6. Khorrami-Nejad M, Aghili O, Hashemian H, Aghazadeh-Amiri M, Karimi F. Changes in Corneal Asphericity after MyoRing Implantation in Moderate and Severe Keratoconus. *Journal of ophthalmic & vision research*. 2019;14(4):428.
7. Mounir A, Radwan G, Farouk MM, Mostafa EM. Femtosecond-assisted intracorneal ring segment complications in keratoconus: from novelty to expertise. *Clinical Ophthalmology (Auckland, NZ)*. 2018;12:957.
8. Alio JL, Vega-Estrada A, Esperanza S, Barraquer RI, Teus MA, Murta J. Intrastromal corneal ring segments: how successful is the surgical treatment of keratoconus? *Middle East Afr J Ophthalmol*. 2014;21(1):3-9.
9. Heikal MA, Abdelshafy M, Soliman TT, Hamed AM. Refractive and visual outcomes after Keraring intrastromal corneal ring segment implantation for keratoconus assisted by femtosecond laser at 6 months follow-up. *Clin Ophthalmol*. 2017;11:81-6.
10. Asbell PA, Petratos T, Kozak A, Feldman BH, Sheth S, Ortiz-Morales G, et al. Keratoconus 2020 [cited 2021 March 26]. Available from: <https://eyewiki.org/Keratoconus>
11. Tenkman Lawrence R, Price Marianne O, Price Francis W. Keratoconus Onset After Age 50. *Journal of Refractive Surgery*. 2012;28(6):436-8.
12. Fink BA, Sinnott LT, Wagner H, Friedman C, Zadnik K. The influence of gender and hormone status on the severity and progression of keratoconus. *Cornea*. 2010;29(1):65-72.
13. Alió JL. *Keratoconus: Recent Advances in Diagnosis and Treatment*: Springer International Publishing; 2016.
14. Hodge C, Aggarwala A, D'Souza M, Sutton G, You J. Gender could play an important part in the onset of keratoconus-insights from characterizing an Australia keratoconus cohort. *Investigative Ophthalmology & Visual Science*. 2019;60(9):6505-.
15. Henriquez MA, Izquierdo L, Jr., Bernilla C, McCarthy M. Corneal collagen cross-linking before Ferrara intrastromal corneal ring implantation for the treatment of progressive keratoconus. *Cornea*. 2012;31(7):740-5.
16. Saib N, Bonnel S, Fenolland JR, Abrieu M, Rambaud C, Berguiga M, et al. Intrastromal corneal rings and corneal collagen crosslinking for progressive keratoconus: comparison of two sequences. *Eye (London, England)*. 2015;29(2):294-5.
17. Renesto Ada C, Melo LA, Jr., Sartori Mde F, Campos M. Sequential topical riboflavin with or without ultraviolet a radiation with delayed intracorneal ring segment insertion for keratoconus. *Am J Ophthalmol*. 2012;153(5):982-93.e3.
18. Saleem MIH, Ibrahim Elzembely HA, AboZaid MA, Elagouz M, Saeed AM, Mohammed OA, et al. Three-Year Outcomes of Cross-Linking PLUS (Combined

- Cross-Linking with Femtosecond Laser Intracorneal Ring Segments Implantation) for Management of Keratoconus. J Ophthalmol. 2018;2018:6907573.
19. El-Raggal TM. Effect of corneal collagen crosslinking on femtosecond laser channel creation for intrastromal corneal ring segment implantation in keratoconus. Journal of cataract and refractive surgery. 2011;37(4):701-5.
 20. El-Raggal TM. Sequential versus concurrent KERARINGS insertion and corneal collagen cross-linking for keratoconus. 2011;95(1):37-41.
 21. Bamdad S, Sedaghat MR, Yasemi M, Maalhagh M. Intracorneal Stromal Ring Can Affect the Biomechanics of Ectatic Cornea. J Ophthalmol. 2020;2020:4274037.