

## A Review On Periodontal Pocket – The Pathologically Deepened Sulcus

Kowsalya S<sup>1</sup>, Anil Kumar Kanakamedala<sup>2\*</sup>, Jaideep Mahendra<sup>3</sup>, Ambalavanan N<sup>4</sup>

Department of Periodontics, Meenakshi Ammal Dental College, Faculty of Dentistry,

Meenakshi Academy of Higher Education and Research, Chennai, India.

Higher Education and Research, Chennai, India.

dranil.perio@madch.edu.in

### ABSTRACT

One of the most important clinical aspects of periodontal disease is the periodontal pocket. It is bounded on one side by the tooth, on the other by ulcerated epithelium, and at its base by the junctional epithelium. A periodontal pocket is a region of the mouth that is difficult to reach for plaque clearance. In order to design a more precise treatment strategy and avoid the advancement of periodontal disorders, a full understanding of periodontal pocket aetiology is required.

**Keywords:** *Periodontal pocket, pathogenesis, Periodontal therapy.*

### I. Introduction

The anatomic space between the tooth's neck and the circumferential gingival tissue is known as the gingival sulcus. The formation of a pathologically deepened pocket referred to as periodontal pocket occurs when this shallow crevice deepens due to apical migration of junctional epithelium accompanied by attachment loss as a result of the periodontal disease process.<sup>[1]</sup> In order to establish better preventive measures and therapeutic outcomes for the treatment of this disease process, this article gives a comprehensive insight into the development and advancement of periodontal pockets.

### II. Classification of periodontal pockets

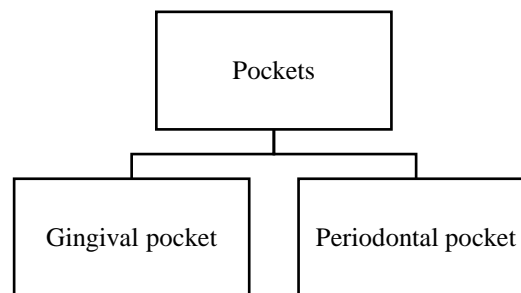


Figure1: Classification of pathological pockets

#### Gingival Pocket <sup>[2]</sup>

In gingivitis, a pseudo pocket is developed by gingival enlargement and sulcus deepening without affecting the underlying periodontal tissues.

### Periodontal pocket <sup>[3]</sup>

In periodontitis, a deepening of the gingival sulcus with the loss of underlying periodontal tissues is known as a true or absolute pocket.

### Suprabony pocket

The pocket's base is coronal to the alveolar bone, with a horizontal pattern of bone loss.

### Infrabony pocket<sup>[4]</sup>

The base of the bone is apical to the crest, and the bone is adjacent to the soft tissue wall; the destruction pattern is vertical or angular. Pockets can involve one, two, or more tooth surfaces, and they can be of varying depths; they can also be spiral (i.e., starting on one tooth surface and twisting around the tooth to involve one or more other surfaces); and they are most prevalent in furcation areas.

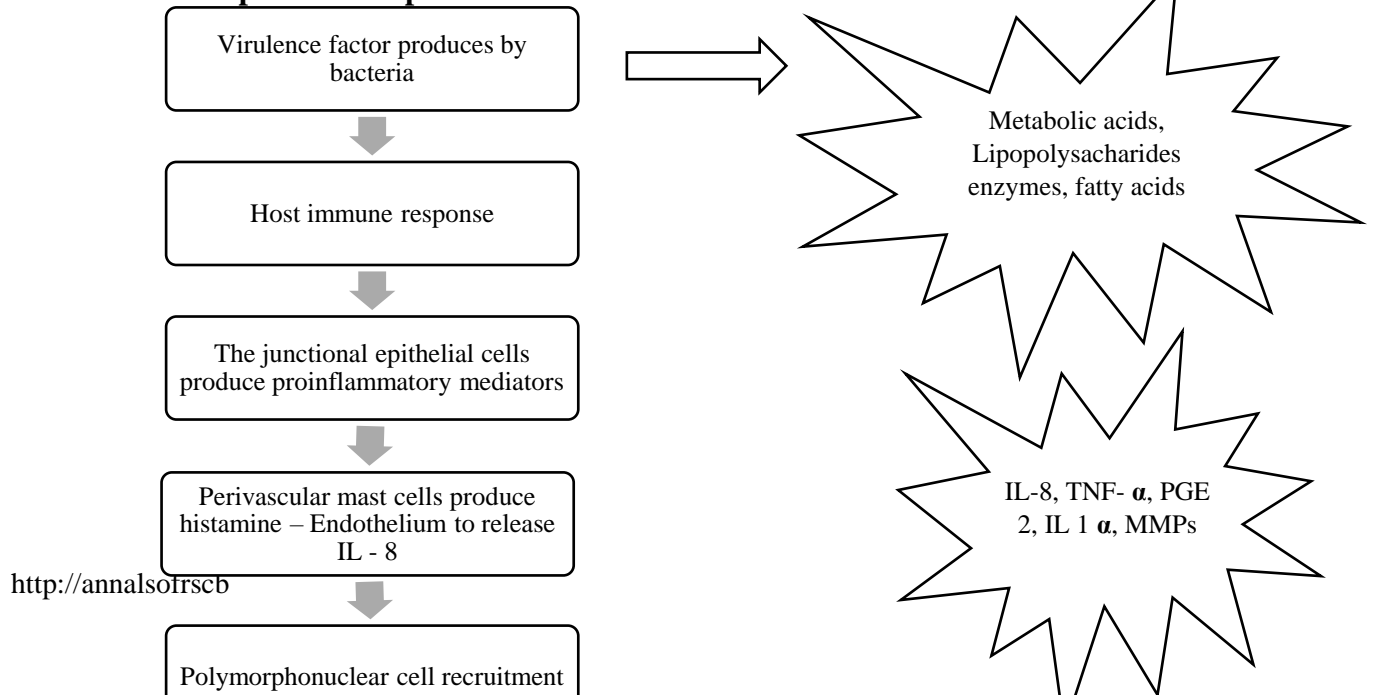
### III. Clinical features of periodontal pocket <sup>[5]</sup>

On probing - gingival haemorrhage and suppuration, in deep chronic pockets - tooth movement and diastema development, bluish red discoloration of pocket wall extending from gingival margin to alveolar mucosa, flaccid with smooth shiny surface, pain in periodontal pocket on examination with probe.

### IV. Contents of the periodontal pocket<sup>[6]</sup>

Debris, microorganisms and their products (enzymes, endotoxins, and other metabolic products), gingival fluid, food remnants, salivary mucin, desquamated epithelial cells, leukocytes, plaque covered calculus, purulent exudate

### V. Formation of periodontal pocket



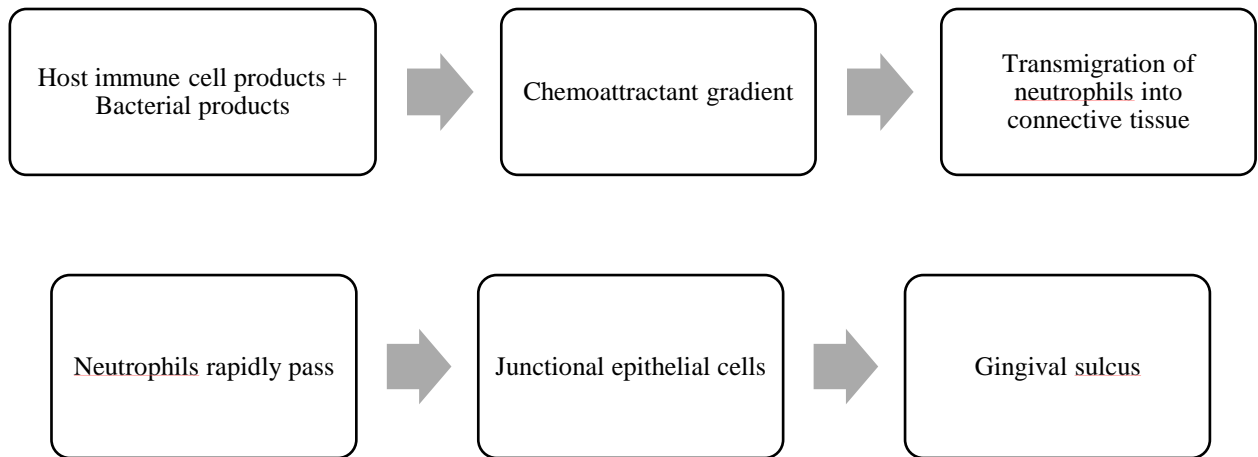



Figure2: Initial lesion

Over the subgingival plaque, neutrophils form a dense layer. They use antimicrobial mechanisms like phagocytosis to prevent bacteria from invading further. As the inflammation worsens, connective tissue and gingival fibres deteriorate. Due to the loss of collagen, the junctional epithelium's apical cells proliferate along the root surface and develop finger-like projections that are two or three cells thick. <sup>[7]</sup>

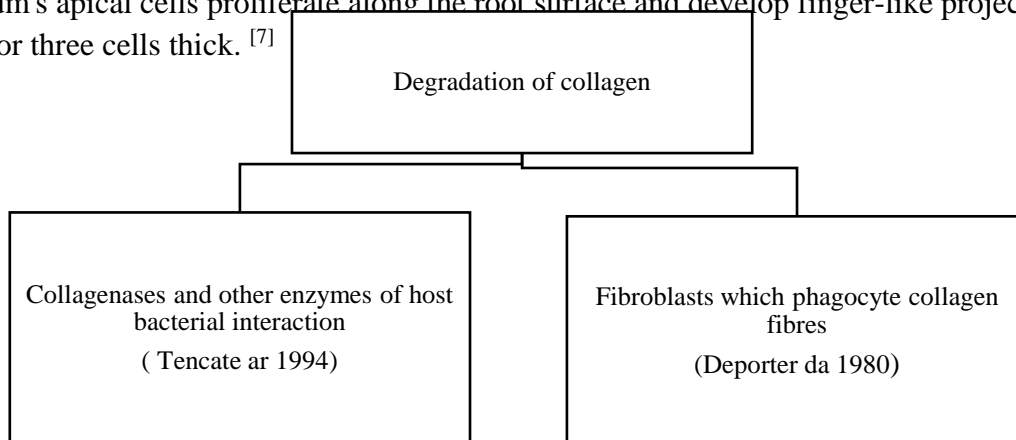


Figure3: Degradation of collagen

As the apical component of Junctional Epithelium migrates, the coronal portion of the epithelium separates from the root surface. PMNs invade the coronal end of Junctional Epithelium as a result of inflammation, and when the relative volume of the Junctional Epithelium reaches 60% or more, the tissue loses its cohesiveness and detaches from the tooth surface. The breach of the epithelial barrier allows communication between the pocket and the underlying tissue. [8] The second most critical event in the pocket formation is ulceration. The antigen-presenting cells activate T cells, which activate the B cell response, as the length of the lesion increases. [9]

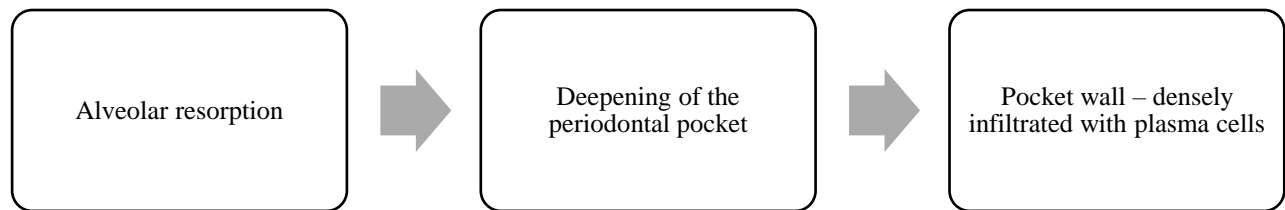


Figure4: Advanced Lesion

## VI. Microtopography of the gingival soft tissue pocket wall [10]

Areas of relative quiescence - A relatively flat surface with tiny depressions and mounds, as well as intermittent cell shedding. Areas of bacterial accumulation - depressions on the epithelium surface with a lot of debris and bacterial clumps entering the expanded intercellular gaps. Cocci, rods, filaments, and a few spirochetes are among the organisms found. Areas of leukocyte-bacteria interaction - A large number of leukocytes are present, and they are covered in bacteria in what appears to be a phagocytosis process. Areas of intense epithelial desquamation - Semi-attached and folded epithelial squames, which are occasionally partially covered with microorganisms. Areas of emergence of leukocytes - Leukocytes emerge from the pocket wall through perforations in the intercellular gaps. Areas of ulceration with connective tissue visible. Areas of hemorrhage with a large number of erythrocytes.

## VII. Histopathological features of the periodontal pocket

### Changes in soft tissue wall[11]

Soft tissue components	Pathological changes
Connective Tissue	Exudative Changes - Edematous with extensive infiltration of plasma cells, lymphocytes, and neutrophils.  Proliferative Changes - Blood vessels become dilated, engorged, and increase in

	<p>number. In the subepithelial connective tissue, these alterations are more pronounced.</p> <p>Endothelial cell proliferation is established, along with newly formed capillaries, fibroblasts, and collagen fibres.</p>
Junctional Epithelium	<p>Degenerative changes - The cells of the junctional epithelium can show signs of degeneration ranging from mild to severe.</p> <p>In the coronal direction, the thickness of the JE at the pocket's base is reduced to only 50 to 100 m.</p>
Lateral wall	<p>Exudative changes - Edema from inflammatory connective tissue, as well as a high infiltration of leukocytes.</p> <p>Proliferative changes - Epithelial buds or interlacing cords of epithelial cells protrude from the lateral wall into inflammatory connective tissue next to the junctional epithelium, extending further apically into the junctional epithelium.</p> <p>Degenerative changes - Cell vacuoles degenerate and break, forming vesicles.</p> <p>Ulceration of the lateral wall occurs as the epithelium degenerates and necrotizes, revealing the underlying inflammatory connective tissue and suppuration.</p>

Table 1: Soft tissue wall changes

**Condition of the soft-tissue wall of the periodontal pocket<sup>[12]</sup>**

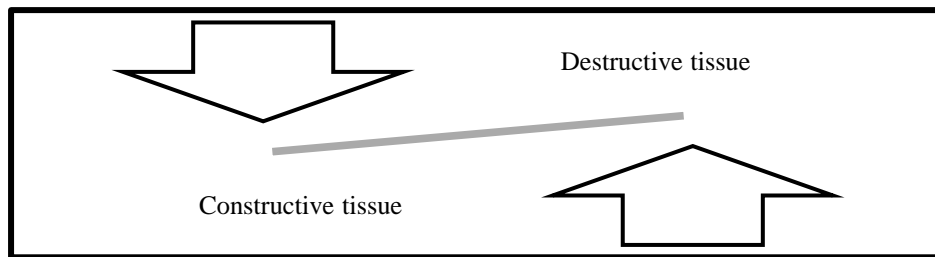


Figure 5: Soft tissue wall of periodontal pocket

Destructive tissue	Constructive tissue
Edematous pocket wall	Fibrotic pocket wall
Predominance and inflammatory fluid and cellular exudate	Newly formed connective tissue cells and fibers are predominantly seen

The pocket wall is smooth, shiny spongy and friable with bluish red hue	The pocket wall is firmer and pinker in colour
---	--

Table 2: Destructive and constructive changes

Edematous and fibrotic pockets are not considered two distinct diseases. They are the diametric opposites of the same pathologic process, and they are constantly subjected to diverse modifications based on the relative preponderance of destructive and constructive alterations.

**Changes in root surface wall <sup>[13]</sup>**

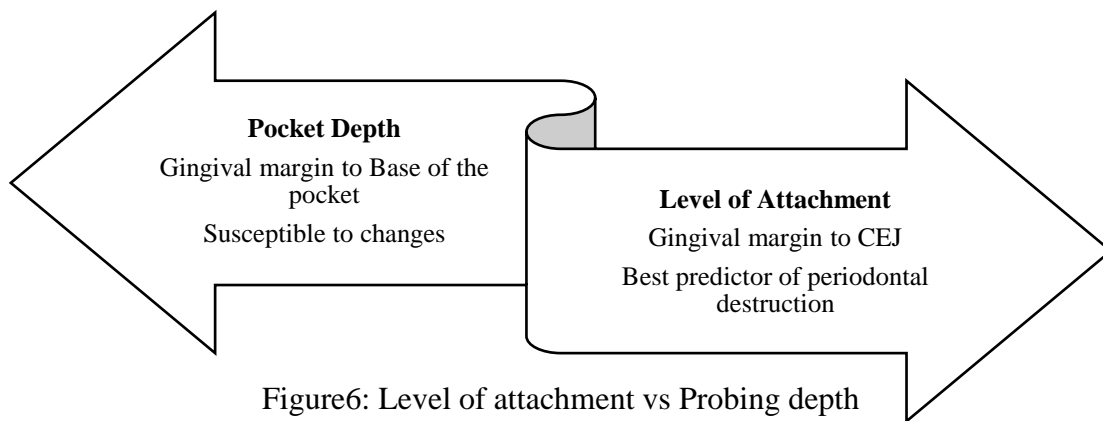
Structural changes	<p>Pyogenic granuloma - Collagen degeneration or places where collagen fibrils are not fully mineralized initially.</p> <p>Areas of increased mineralization - Mineral content of exposed cementum increases in areas of higher mineralization (calcium, magnesium, phosphorus and fluoride)</p> <p>Areas of demineralization - The development of root caries is caused by the proteolysis of remanent sharpy's fibres by bacterial plaque components, which causes cavitation and the progression of caries surrounding the tooth.</p>
Chemical changes	The mineral concentration of exposed cementum increases, rendering the area more resistant to degradation.
Cytotoxic changes	The presence of endotoxin in the diseased cementum inhibits fibroblast proliferation and adhesion to the diseased root surfaces.

Table3: Root surface changes

### VIII. Detection of pocket<sup>[14]</sup>

Careful probing of the gingival border along each tooth surface is the only consistent means of locating and determining the extent of the periodontal pocket. Marquis color-coded probe, UNC-15 probe, Michigan ‘O’ probes, Plastic probes, World Health Organization (WHO) probes, and Williams probe are some of the probes used to locate the periodontal pocket. Pockets are normally not seen on radiographs; however, they can be spotted using gutta percha points or calibrated silver points in conjunction with radiography.

### IX. Level of attachment vs probing depth<sup>[15]</sup>



### X. Clinical and Histological probing depth<sup>[16]</sup>

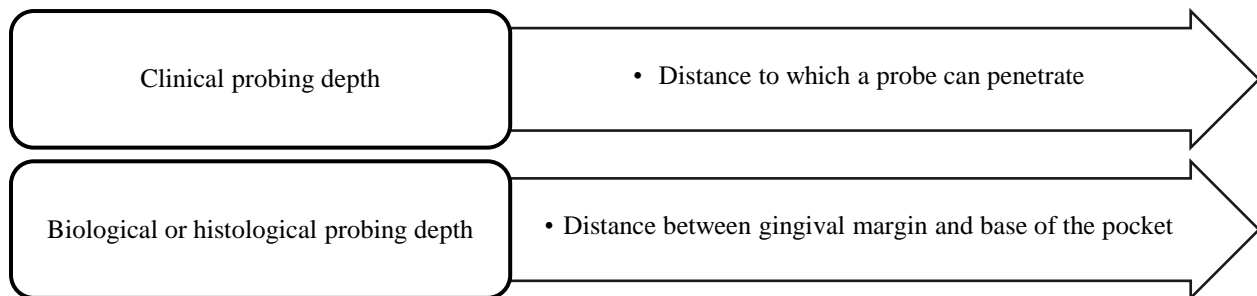
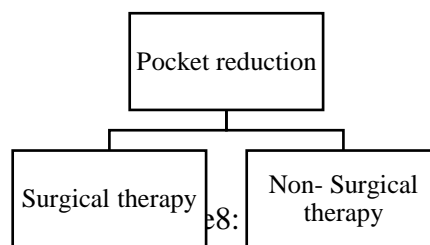


Figure 7: Clinical and histological probing depth

### XI. Treatment of periodontal pocket



### Aim of the periodontal pocket therapy<sup>[17]</sup>

To eliminate pocket lining, pocket wall, and pocket reduction by tissue shrinkage, to achieve a stable and maintainable state, and to stimulate periodontal regeneration.

### Non-surgical therapy<sup>[18]</sup>

Scaling and root planing, types of curettes: universal and area specific curettes.

### Surgical therapy<sup>[19]</sup>

Accessibility for proper SRP, plaque control, pocket reduction and new attachment.

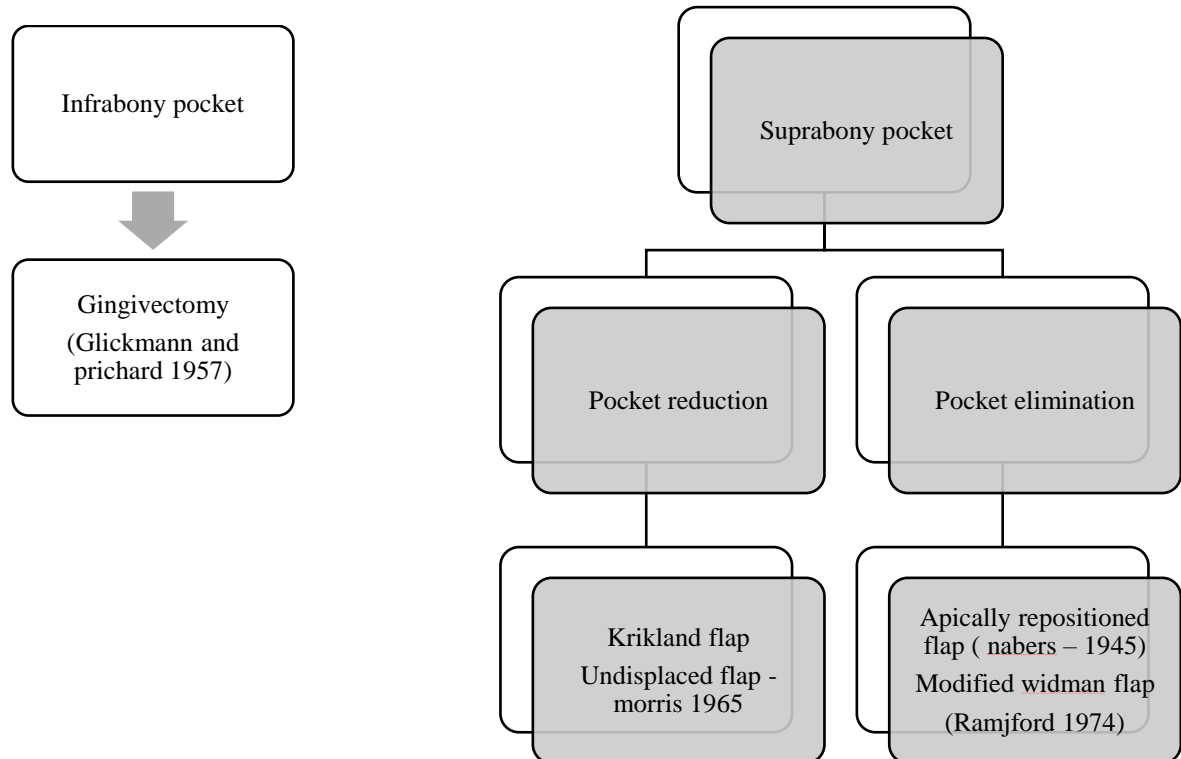


Figure9: Surgical periodontal therapy

### References

1. Newman MG, Takei H, Klokkevold PR, Carranza FA. Newman and Carranza's Clinical Periodontology E-Book. Elsevier Health Sciences; 2018 May 29.
2. Trackman PC, Kantarci A. Molecular and clinical aspects of drug-induced gingival overgrowth. Journal of dental research. 2015 Apr;94(4):540-6.
3. Bosshardt DD. The periodontal pocket: pathogenesis, histopathology and consequences. Periodontology 2000. 2018 Feb;76(1):43-50.
4. Krayer JW, Rees TD. Histologic Observations on the Topography of a Human Periodontal Pocket Viewed in Transverse Step-Serial Sections. Journal of periodontology. 1993 Jul;64(7):585-8.
5. Arweiler NB, Ausschil TM, Sculean A. Patient self-care of periodontal pocket infections. Periodontology 2000. 2018 Feb;76(1):164-79.



6. Graham JW. The toxicity of sterile filtrate from parodontal pocket. 1937: 1165-1172.
7. Deporter DA, Brown DY. Fine structural observations on the mechanism of loss of attachment during experimental periodontal disease in the rat. *Journal of periodontal research*. 1980 Jun;15(3):304-13.
8. Schroeder HE. Quantitative parameters of early human gingival inflammation. *Archives of oral biology*. 1970 May 1;15(5):383-IN4.
9. Donos N. The periodontal pocket. *Periodontology 2000*. 2018 Feb;76(1):7-15.
10. Saglie R, Carranza Jr FA, Newman MG, Pattison GA. Scanning electron microscopy of the gingival wall of deep periodontal pockets in humans. *Journal of periodontal research*. 1982 Jun;17(3):284-93.
11. Schroeder HE. The periodontium. *Handbook of microscopic anatomy, Bd V/5*. Springer Verlag, Berlin. 1986;4(6):9.
12. Hillmann G, Dogan S, Geurtsen W. Histopathological investigation of gingival tissue from patients with rapidly progressive periodontitis. *Journal of periodontology*. 1998 Feb;69(2):195-208.
13. Adriaens PA, De Boever JA, Loesche WJ. Bacterial invasion in root cementum and radicular dentin of periodontally diseased teeth in humans: a reservoir of periodontopathic bacteria. *Journal of periodontology*. 1988 Apr;59(4):222-30.
14. Hunter F. Periodontal probes and probing. *International dental journal*. 1994 Oct 1;44(5 Suppl 1):577-83.
15. Listgarten MA. Periodontal probing: what does it mean?. *Journal of clinical periodontology*. 1980 Jun;7(3):165-76.
16. Caton J, Greenstein G, Polson AM. Depth of periodontal probe penetration related to clinical and histologic signs of gingival inflammation. *Journal of Periodontology*. 1981 Oct;52(10):626-9.
17. Radvar M, MacFarlane TW, MacKenzie D, Whitters CJ, Payne AP, Kinane DF. An evaluation of the Nd: YAG laser in periodontal pocket therapy. *British dental journal*. 1996 Jan;180(2):57-62.
18. Heitz-Mayfield LJ, Lang NP. Surgical and nonsurgical periodontal therapy. Learned and unlearned concepts. *Periodontology 2000*. 2013 Jun;62(1):218-31.
19. Graziani F, Karapetsa D, Mardas N, Leow N, Donos N. Surgical treatment of the residual periodontal pocket. *Periodontology 2000*. 2018 Feb;76(1):150-63.