

An analytical intervention of *Plectranthus Amboinicus* extracted from cow ark attenuating liver enzymes activities and Alpha fetoprotein level in CCL4 induced Hepatocellular Carcinoma

Nithya V

Department of Animal Health and Management, Pharmacognosy Lab, Alagappa University, Karaikudi-630 003, Tamil Nadu, India. Ph: 9842999430; E-mail: nithyav@alagappauniversity.ac.in Ph: 098429 99430.

ABSTRACT

Cow ark, (Cow urine distillate), is an indispensable therapeutic agent in traditional Indian medicine and Ayurveda. Incidence of several diseases, including Hepatocellular carcinoma (HCC) is increasing gradually to a new peak. The main objectives of this investigation were to detect and evaluate protective ability of *Plectranthus Amboinicus* extracted from cow ark on enzymatic functions of liver and to explore attenuating capability of cow ark on HCC biomarker. The analyses include, effects of *Plectranthus Amboinicus* with cow ark (BCA), in serum level of AST,ALT,ALP, Total bilirubin, and alpha fetoprotein (AFP) fluctuations in carbon tetrachloride(CCL4), induced HCC rats. Toxicity was stimulated by CCL4 with olive oil as vehicle in the ratio of (1:1 v/v);(olive oil 5mL/kg i.p). Sylimarin was used as a reference (standard) for intoxicated animal groups. Moreover, observation of histological studies favours the biochemical changes observed. Results showed BCA is highly potential in depleting the level of liver enzymes and AFP biomarker, based on dose regimen. These might have been due to the action of enriched phenolic content of BCA, to get rid of free radicals. Study concluded that BCA is a universal medicine and modulating biochemical changes in hepatotoxicity of liver cells induced HCC rat model.

Keywords: Cow ark, HCC, Alpha fetoprotein, Carbon tetrachloride, Bio enhancer, Anti cancer.

INTRODUCTION

Cow ark, a distilled product of cow urine, and takes part in diversified ailments for numerable diseases. *Bos Indicus*, has been extensively described as "Pedestal dispensary", since ancient Ayurveda scripts[1]. Inevitably, Indian economy, rely a huge spectrum of benefits in agriculture and rural livelihoods on Indian cow[2]. Health provider of Ayurvedic medicine used cow urine as a remedy for chronic and acute diseases, including Cancer, AIDS, Diabetes and Dermatological diseases due to its non- toxicity, antiviral, antifungal, antibacterial and anti cancer properties [3-7]. Cow derived products have been endorsed as a bio enhancer for the effectiveness of popular antibiotics and anti cancer therapeutic drugs[8-10]. Animals estrus urine having main source of volatile compounds and Pheromone compounds as therapeutic agents against many diseases. [11-13] .

The serum enzymes activities have been recognised as sensitive and critical biomarkers for liver diseases including Hepatocellular Carcinoma (HCC). They act as a good indicator for entire health concerns, specifically, metabolic syndromes and Obesity[14]. AST, ALT and ALP in serum are used as determinant factors and biomarkers to predict the health of the liver. The level of AST and ALT ratio (> 1.5) in vascular stream raised while the body tissues are damaged due to the discharge of excess serum enzymes. The alpha-fetoprotein represents a glycoprotein formed from the embryonic stage to adult, that involved in controlling of body, specifically in differentiation of cells and also participated in the metabolism of Fat and Glucose, indicating chronic damage of liver tissues, and crucial biomarker for HCC [15].

Cow Ark is also often used as a biological facilitator for anticancer therapy individually or synergistically with other anticancer molecules for cancer therapy (Khanuja et al., US patent [16]). The bio active fraction accelerates the action of antibacterial and anticancer actions from 2

to 80 folds and favours the antibiotics or other compounds to exert their effectiveness[17]. For instance, Sulforaphane has been exhibited the inhibitory effects of cancer growth and categorized as Isothiocyanate [18], Sulforaphane is a product of glucosinolate. Glucoraphanin, is a glucosinolate, enriched in *Plectranthus Amboinicus* and cauliflower [19]. Notably, Text of Ayurveda cited, Cow Ark is considered to be universal, therapeutic potential, used to meet out the short come of elements in the human body and act as a reducing factor, if any increased abnormal appeared. However, still now, literature relevant to the cited is limited. Therefore, it is of great interest to demonstrate, the effects of *Plectranthus Amboinicus* with cow ark on, the level of Liver enzymes such as AST, ALT, ALP and Total bilirubin in CCL4 induced wistar albino rats, and to determine as enhancer for anticarcinogenic agents mediated from plant source.

Materials and Methods

The first thing in the morning, early negating urine of indigenous cow, *B.Indicus*, grazing at open grass field was collected from the cow shed of Ramakrishna Math, Chennai, subsequently distilled it, at the 100° C. using, temperature controlled distillation set up and collected distillate was stored at refrigerator at 10°C below, for further analytical process.

Chemicals and Reagents

Analytical grade chemicals and reagents were purchased from Sigma Chemical Company, MO, USA. for analysing and estimating ALT, AST, ALP and total bilirubin kits were procured from Apollo Diagnostic Medical Center, Chennai, Tamil Nadu. The silymarin was obtained from the Swastic scientific co., at Karaikudi, Tamil Nadu, India.

Cow Ark extraction with *Plectranthus Amboinicus* sprouts as bio enhancer for Anti cancer agent

The extraction protocol for *Plectranthus Amboinicus* sprouts was extracted from cow ark with followed in this experiment, as described by Sucharitha et al.,[17]with slight modification.

Assessment as Enhancer against cancer cells

HCC cell line, HepG2 cell was selected for evaluating BCA as an enhancer to anti cancer agents (ACCA) for improved activities. 200 UL of HepG2 cells with medium were taken on 24 well titre plates, 500 UL of media mixed with 10% FBS, were added in each well. The experimental plates were kept for incubation at 37°C for a night in a 5% CO₂ incubator for 24 hours. The *Plectranthus Amboinicus* extract with cow ark was mixed at a constant concentration of 100 UL in each well, next to the adding of BCA with increasing concentrations such as 100 UL, 200UL and 300 UL. A separate standard was kept with 100 UL, 200 UL of BCA and titre well plate was allowed to the incubation, over a night time at 37°C in 5% CO₂ incubator.

Animal used

About 180-250 gm weighing, male Wister rats were procured from the King Institute of Preventive Medicine and Research, Guindy, Chennai, Tamil Nadu and acclimatized in 12 hour light/dark cycle, fed with diet and water in our laboratory condition. Institutional Animal Ethical Committee Guidelines at PRIST University, Thanjavur, Tamil Nadu (743/03/abc/CPCSEA dt. 3.3.03) approved the protocol of the experiment and adhered the guidelines of the committee and followed.

Determination of dose regime

To assign the effects of cow distillate on biochemical changes in the liver enzymes, three types of dose regime were fixed. The rat dose was derived and calculated from human dose (usually 60 ml/day) and multiplied by a constant factor 0.018 x 5 is similar to 5.4 ml/kg body

weight (First dose) [20]. The second dose was determined as double the first dose, i.e. 10.8 ml/kg body weight. Third dose was fixed as 50% of first dose, i.e. 2.7 ml/kg body weight.

Animal Grouping for experimental design

As per the protocol of the experiment, the procured Wister rats were grouped into 6 numbers (n=6) Group-A was maintained independently as control, and administered saline alone (10ml/kg P.O.) for a week. Group-B received a vial of CCl₄, Single dose with Olive oil, used as vehicle in the ratio of 1:1, 5ml/kg i.p.) as treatment control group (Positive control) on the 7th day of the experiment. Group-C animals were injected with Silymarin (100mg/kg p.o.) once a day, for a week's time, as a reference group, next to a vial of CCl₄ with olive oil on the 7th day of experiment. Group D& E were orally administered with cow urine distillate with three types of dosage pattern such as 2.7ml. 5.4ml and 10.8 ml. per kg body Wt., once a day for a week period, subsequently with a single dose of CCl₄ with olive oil (1:1, 5ml/kg i.p.) on the 7th day of experiment.

After 24 hours of CCl₄ treatment blood was collected from the retro orbital plexus of experimental animals, and conceded to clot for 1 hour at laboratory temperature. The supernatant serum was isolated by using centrifugation for evaluating the level of ALT, AST, ALP and Total bilirubin contents [21]. A couple of rats from each group were sacrificed on the day of blood collection. Liver was quickly segregated and washed well with saline in the cold, followed by fixed in 10% Formalin. Liver was degraded in analytical alcohol and fixed in paraffin wax. A fine section of 5 Um thicknesses was stained with Haematoxylin and Eosin stains for light microscopic observations and photomicrographs for the examined tissues and were documented.

Biochemical examination of serum AST, ALT, ALP and Total bilirubin [21]

Biochemical fluctuations in clinical view, the level of enzymes such as Aspartate aminotransferase (AST) Alanine aminotransferase (ALT), Alkaline Phosphatase (ALP) and Total bilirubin was estimated to determine the enzymatic activities of the liver cells of control and BCA treated groups. The action of serum enzymes was determined by using kits and performed based on the instructions on the overleaf.

Assessment of alpha fetoprotein(AFP) [15]

Estimation of Alpha fetoprotein, a crucial biomarker for liver diseases, found in normal and BCA treated rats, was performed, by using commercial medical kits (Elabsciece, made in China) for Enzyme linked immunosorbent assay, specifically for rat models, along with micro litter plate and required elisa reader for the analysis of alpha fetoprotein level fluctuations.

Measurement of AFP

The level of alpha fetoprotein, in HCC induced rats, was measured, by following earlier study, which revealed that 250 mg/kg and 500mg/kg of phenolic extract was used their study, to assess AFP. Therefore, in our study, a similar quantity of BCA was chosen. All doses of BCA were administered orally, for the period of 60 days, prior to the administration of CCl₄. The results were expressed as Mean values.

Statistical Analysis

The illustrated data were expressed as Mean values and statistically analysed using ANOVA. $P < 0.05$ was indicated significant variance.

RESULTS

Assessment as Enhancer against cancer cells

In the present investigation, HepG-2 was treated with sulforaphane, an anticancer agent, extracted from *Plectranthus Amboinicus* [22] to detect and evaluate the cow ark anti cancer enhancing potentials. HepG-2 was maintained with sulforaphane as standard (100 UL,

200 UL) and also sulfuraphane anticancer causative agents(ACCA) with cow ark in progressive elevating concentrations such as 100 UL ACCA + 100 UL BCA, 100 UL ACCA + 200 UL BCA and 100 UL ACCA + 300 UL BCA. Subsequently the ACCA of 100 UL was added. Results showed that as increased concentration of BCA, the rate of deterioration of HepG-2 cells was observed increasingly, and progressively (Fig 1). The optimum degeneration of HepG-2 cells was noticed in 100 Ul ACCA +300 UL BCA. Therefore it was evident that there was a strong effect exerted by the *Plectranthus Amboinicus* extracted with Cow Ark (Fig 1).

Fig -1 Effect of *Plectranthus Amboinicus* extracted with Cow Ark (cow ark enhancer) on the against HepG-2 assessment as Enhancer against cancer cells.

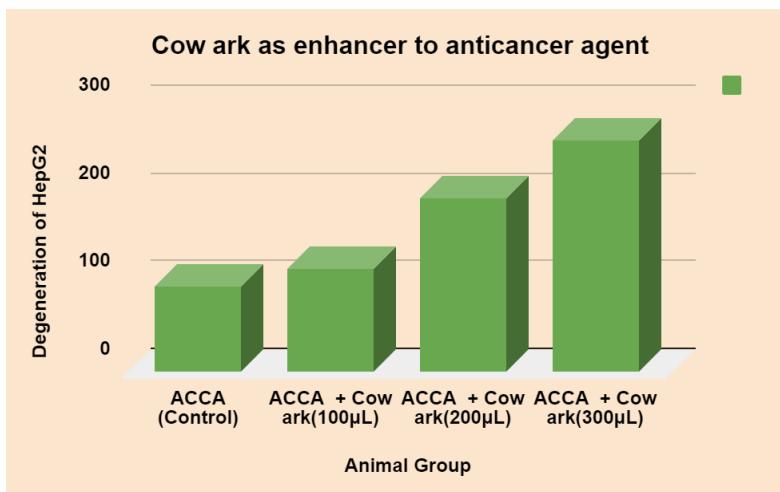
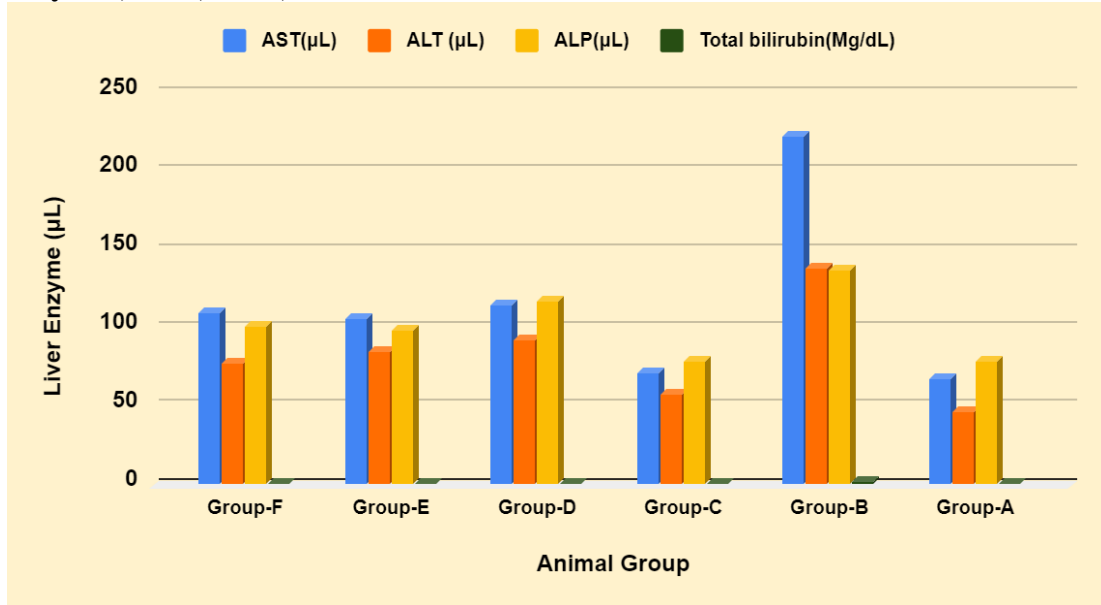


Table-1 Biochemical fluctuation on the enzyme level of liver cells, treated with three concentrations of BCA and standard silymarin in CCl4 induced HCC induced rats.

Sl. No	Animal Group	AST (UL)	ALT (UL)	ALP (UL)	Total bilirubin (Mg/dL)
1.	Group-A	67.15	45.64	78.42	0.47
2.	Group-B	221.48 **	137.80**	136.51**	2.21**
3.	Group-C	70.64*	57.51*	77.90*	0.56*
4.	Group-D	114.20*	91.61*	116.43*	0.88*
5.	Group-E	105.22*	83.92*	97.61*	0.74*
6.	Group-F	109.02*	77.68*	100.74*	0.69*

*P < 0.05 against Group-B; **P < 0.05 against Group-A; A-Control Group; B-CCl4 Treated Group; C-Silymarin administered group; D-F *Plectranthus Amboinicus* extracted with Cow Ark (BCA) treated groups of 3 doses.
 Enzymes: AST-Aspartate Aminotransferase; ALT-Alanine Aminotransferase; ALP-Alkaline phosphatase

Fig-2 *Plectranthus Amboinicus* extracted with Cow Ark (BCA) attenuating the levels of liver enzymes, AST, ALT,ALP and total bilirubin in HCC induced rats.



Biochemical analysis: Administration of CCl₄ remarkably enhanced the levels of AST, ALT and ALP and total bilirubin, which were depicted in Table-1 at (P< 0.05) significant level.

Histological studies

The reported findings of serum enzymes analysis have shown to be good agreement and supportive evidence for histological observations. The section of normal control animal liver exhibited typical hepatocytes filled with cytoplasm, and a conspicuous nucleus associated with a clear central vein. Sections of liver, from CCl₄ intoxicated rats exhibited wide alteration in the fat deposition, well defined necrosis, disintegration and invading of lymphocytes at the every side of the central vein and showed detrimental effects on cellular boundaries. The structural architecture of liver cells of *Plectranthus Amboinicus* extracted with Cow Ark (BCA) treated animals manifested a soft fatty changes unpredictable necrosis and less infiltration of lymphocytes, when compared with normal control and standard silymarin served groups (Fig-3-(i)-(iv))

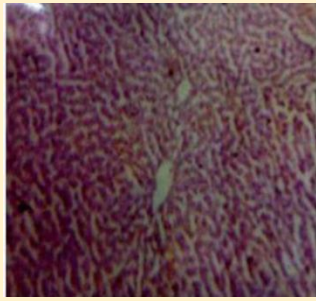


Fig-(i). Liver section showing a typical sinusoides with central vein and depicted hepatocyte coordination.

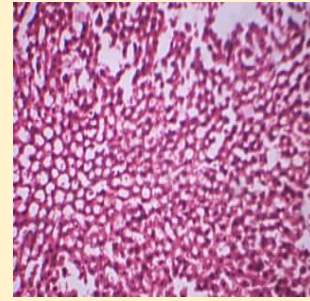


Fig- (ii). CCl 4 induced liver section exhibiting abnormality in the fat deposition around portal track and central vein. Hepatocytes showing vacuoles and disturbed nuclei.

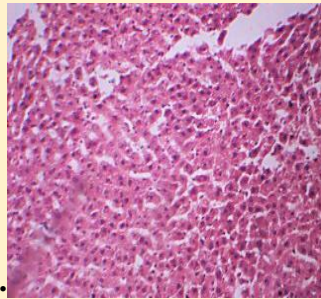


Fig - (iii). *Plectranthus Amboinicus* extracted with Cow Ark (BCA) pretreated liver section showing normal appearance of hepatocytes a very little fat vacuoles exhibited in the few hepatocytes.

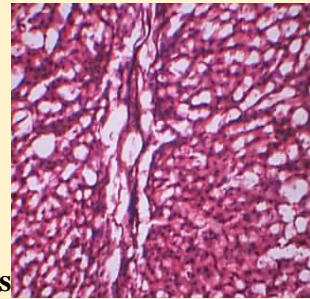


Fig - (iv) This section of liver pretreated with silymarin depicting normal architecture of hepatocytes and no changes were observed in the fat accumulation.

Fig -3. The liver cells of *Plectranthus Amboinicus* extracted with Cow Ark (BCA) treated animals manifested when compared with normal control and standard silymarin served groups.

Measurement of Biomarker (AFP)

The outcome of the experiment reported that a significant increase was observed in the level of AFP, in the treated group with CCL4 (19.71 ± 0.76) while compared with the control group of animals (8.36 ± 0.32). These results confer an evident of the protective role of both concentration of BCA, prior and post administration of CCL4. It also exhibited a significant slowdown of AFP level at 5% p value, as compared with CCL4 treatment group.

In our investigation, depicted in Table -2 , showed a significant decrease was noticed in AFP level in *Plectranthus Amboinicus* extracted with Cow Ark tested animal groups. It was noted that, in previous studies, phenolic compounds conciliated from varied plant extracts, reduced AFP level of CCL4 , attributable to the antioxidant potential. The values obtained, were presented to analyse fluctuations.

Table -2 Effect of *Plectranthus Amboinicus* extracted with Cow Ark on the AFP Level of induced HCC treated rats with ccl4

s.no	Trial	Level of AFP(ng/mL)
1	control	8.36 ± 0.32
2	ccl ₄	*19.71 ± 0.76
3	<i>Plectranthus Amboinicus</i> extracted with Cow Ark (BCA) treated (250mg/Kg)	*(B)9.32 ±0.71(A)9.07 ±0.2
4	<i>Plectranthus Amboinicus</i> extracted with Cow Ark (BCA) treated (500mg/Kg)	*(B)9.27 ±0.18(A)9.03 ±0.29

(B)-Prior to ccl₄, administration (A)-After treating ccl₄, Mean value ≤ 0.05 level. *-Significant compared to treated animals against control;n=6 for all trials

DISCUSSION

Metabolic alterations coupled with hepatic factors are associated with the development of HCC disease and profound toxicity [23]. Serum AST, ALT and ALP are significant biomarkers to evaluate the structural integrity of the liver cells and served as aids in the prediction of liver toxicity [24]. The effectiveness of *Plectranthus Amboinicus* extracted with Cow Ark on the level of serum AST, ALT, and ALP were depicted. The ALT, AST, ALP and total bilirubin levels in the serum was recorded and tabulated in Table No.1. The reference range of AST, ALT and ALP enzymes are 50-150 UL, 10-40 UL, and 30-130 UL separately detected [25]. In the present study, the mechanism of liver injury induced through generation of trichloromethyl (CCl₃) by liver at the time of CCl₄ metabolism [26]. Free radicals showed they were highly capable of finding cell molecules with covalent bonds, resulting in cell necrosis. The increased level of AST, ALT, ALP and Total bilirubin was attributable to the enzymatic actions of free radicals from CCl₃ [27-28]. These facts were supportive evidence for enhanced level of the tested biomarkers in our findings and correlated with findings of Gururaja et al.,[29]. Consequently, pretreated with cow ark (Distillate) altered the enhanced enzyme levels, based on the dosage regime, symptomatic that it interrupts the mechanism of action that emerged by CCl₃, free radicals. Such a unique feature enhanced the importance of biomarker enzymes as a screening tool for detecting liver associated diseases.

In normal conditions, Hepatic cells involved in different enzymatic metabolic actions and CCl₄ induce a significant liver injury with a determined dose regime. Administration of CCl₄ in heavy dose, caused liver necrosis after indulging bioactivation to the toxic factor, N-Acetyl-p-benzoquinone-imine (NAPQI) by cytochrome P-450 monooxygenase. The NAPQI factor binds with cellular biomolecules and activates the oxidation process on fatty acids which in turn disturbed the homeostasis of calcium, after exhaustion of Glutathione. Whereas treating cows distillates during pre-treatment, lowering down the elevated level of enzymes involved. Refurbishment of such biochemical changes, attributable to the down regulation effects on cytochrome p-450 [30].

HCC is a chief component for malignancy in liver tissues carcinoma and associated death worldwide. The obtained results of the study, showed a remarkable fluctuation, increased in AFP level, after treating with CCL4. In tumor pathology, alteration or disease affected liver cells can express, AFP elevation in HCC was reported. The range between 20-200 ng/mL in serum AFP, indicating non-specific criteria in HCC prediction [31]. Similarly, findings of several studies speculated that, level of AFT sensitivity is high in specific HCC [32]. However, in another study, carcinogenesis due to CCL4, was considered to be secondary to its toxicity effects of hepatic cells [33]. Study conducted by Eleazar et al., [34] Fujiwara et al., [35] have suggested the progression of AFP, is linked with the severity of the disease.

Our findings can be assumed that higher content of phenol present in cow ark contributed efficacy, to get rid of free radicals to deplete CCL4 effects. Similarly, in another study, it has exhibited that, inter linking of phenols and antioxidant potential, to stabilize carcinogenesis, and lipid peroxidation, resulting in a decline of AFP level [36].

As a bio enhancer

The present investigation is ample evidence that cow ark is believed to cure several diseases including HCC and an effective bio enhancer for anti cancer activities. In earlier studies, Wate et al., [37] demonstrated that cow urine distillate is a potential enhancer and facilitator for biomolecules and served as antibiotic, antifungal and anticancer agents. In a recent study, cow urine distillate was treated with increasing concentration of 20 UL, 40UL 60UL and 80 UL and outcome showed that cow urine distillate was more effective enhancing property to the several antimicrobial drugs within 48 hours of incubation [17]. Interestingly, earlier studies have deciphered that extraction of anti cancer agents derived from plant species particularly, cruciferous vegetables can bring down the risk of developing lung cancer HCC, colorectal and prostate carcinomas [38-40]. In another study Kushad et al., 1999, *Plectranthus Amboinicus* seeds are potential and enriched with Glucosinolates (or) Isothiocyanate [41-43]. In our work, sulforaphane, a glucosinolate exhibited from *Plectranthus Amboinicus* sprouts with cow urine distillate was evidenced as a bioenhancer for anticancer therapeutic agents. Our study rate of increased concentration of cow ark is directly associated with degeneration of HepG-2 cells, and may be attributed to the participation of cow ark to confer more effectiveness to the plant based anti cancer agents (ACCA).

CONCLUSION

The present investigation has endorsed that *Plectranthus Amboinicus* extracted with Cow Ark has played a crucial role in modulating vital biochemical alterations in the liver enzymes, for the hepatocytes protection and also functions as enhancer for effectiveness to the anti cancer agents, that was being tested in HepG2 cell lines. Decline of AFP biomarker has favoured the evidence for cow ark potential in treating HCC in early detected diseases. It can be concluded that cow ark imparts dual protective role in depleting liver enzymes and AFP, an important biomarker for HCC diseases, as observed in the study and need a further research to explore or validate its mechanism of actions in treating Hepatocellular carcinoma clinically.

Acknowledgements

V.N is highly thankful to authorities of the Alagappa University, Karaikudi, Tamil Nadu, India, which was supported the research work done by the MHRD-RUSA 2.0-F.24/51/2014-U, policy (TNMulti-Gen), Dept. of Edn. Govt. of India.

References

1. Meena, M. Patel, P. Saini, S. Gurjar, T. Gogoi, R and Meena, O.P. Go mutra (Cow urine) and its uses: An overview. *Journal of Entomology and Zoology Studies*, 2019; 7(3): 1218-1222
2. Shah, C.P. Patel, D.M. Dhama, P.D. Kakadia, J. Bhavsar, D. Vachhani, U.D. Trivedi, M.N. Joshi, V.J. In vitro screening of antibacterial activity of cow urine against pathogenic human bacterial strains. *International Journal of Current Pharmaceutical Research*, 2011; 3(2):91-92.
3. Nithya V. (2021) Evaluating the antioxidant and lipid peroxidation efficacy of *Celosia spicata* with Cow ark in diethyl nitrosamine induced experimental hepatocellular carcinogenesis. *Adalya journal* 9 (3), 1-30
4. Nithya V. (2021) Indigenous cow ark with *Allium Sativum* -A key to therapeutic and an effective antioxidant to hepatocellular carcinoma, *International Journal of Aquatic Science* 12 (2), 1631-1644.
5. Nithya V. (2015). Evaluation of antidiarrheal activity on *Coriandrum sativum* linn., in wistar albino rats. *World Journal of Pharmaceutical research*, 4(5),638-643.
6. Nithya V.(2011). Anti-inflammatory activity of *Lawsonia ulba* Linn., in wistar albino rats. *Asian J Sci Tech*. 2011;4:001–3.
7. Nithya V, Baskar A. (2011). A preclinical study on wound healing activity of *Lawsonia ulba* Linn, *Research Journal of Phytochemistry*,5(2)123–129, 2011.
8. Vinotha M, Thavasuraj S, Chinniah S, Nithya V. (2020).Antimicrobial, Antibiofilm and Antioxidant Effects of Medicinal Plants Extract with Indigenous Cow Ark Against Human Pathogens. *International journal of advanced science and technology*, 29(3),569-583.
9. Thavasuraj S, Nithya V. (2020). Evaluation on efficacy of fatty acids and conjugated Linoleic Acid [CLA] derived from indigenous cow milk Against hepato cellular carcinoma : A key and novel approach, *Biochemical and cellular archives*, 20(2), 3253-3257.
10. Thavasuraj S, Nithya V, Vinotha M, Chinniah S, Archunan G. (2020). Assessment of dosage response of cow milk fat isomers against hepatocellular carcinoma cell lines : A key to novel approach for anticancer. *Biochemical and cellular archives*, 20(2), 3223-3227.
11. Silambarasan V, Deepalakshmi G, Sankarganesh D, Nithya V, Archunan G.(2020). - Identification of potential pheromone source in sows. *Behavioural processes*, 168, 103940.
12. Silambarasan V, Gayathiri S, Deepalakshmi D, Shahitha Banu, Nithya V, Archunan G.(2020) Cloning and sequencing of α -2u globulin of rat preputial gland to assess its longevity in the context of developing an effective rodent trap. *Indian Journal of Biochemistry and Biophysics*, 56(6),433-438.
13. Ramachandran R, Vinothkumar A, Sankarganesh D, Suriyakalaa U, Aathmanathan VS, Kamalakkannan S, Nithya V, Angayarkanni J, Archunan G, Akbarsha MA, Achiraman S. (2020). Detection of estrous biomarkers in the body exudates of Kangayam cattle (*Bos*

indicus) from interplay of hormones and behavioral expressions, Domestic animal endocrinology, 72, 106392.

14. Dhama, K. Rathore, R. Chauhan, R.S. Tomar S.Panchgavya (Cowpathy): an overview. International Journal of Cow Science. 2005; 1(1):1-15.
15. Ray Kim, W. Steven, L. Flamm, Adrian, M. Di Bisceglie, Henry C. Bodenheimer. Serum activity of alanine aminotransferase (ALT) as an indicator of health and disease. Hepatology, 2008;47(4):1363-1370.
16. Murtadha, M. Jawad, Arshad Noori Aldujaili and Merza H. Homady. Assessment Study Of Alpha-fetoprotein Level After Treatment With Urtica Dioica Phenolic Extraction Male Rat Induced By Carbon Tetra-chloride. Plant Achieves, 2018;18(1),410-414.
17. Khanuja, et al. Pharmaceutical Composition Containing Cow Urine Distillate And An Antibiotic; United States Patent (10) Patent No.: US 6,410,059 B1.
18. Sucharitha, K.M. Satish Kumar, Rajasekharan, Trishna Kandhari, Balaji Prasanna Kumar Gopal Doss, Yuvarani Thambidurai. Cow urine distillate as a bioenhancer for antimicrobial & antiproliferative activity and redistilled Cow urine distillate as an anticlastogen agent. Asian J Pharm Clin Res. 2017;10(10) 273-277.
19. Shah, E. Herbal Composition in Cow Urine Distillate. US Patent No. 5693327; 1997
20. Chauhan, R.S, Singh, B.P. Singhal, L.K. Immunomodulation with Kamdhenu ark in mice. J Immunol Immunopathol 2001;71:89-92.
21. Ghosh, M.N. (2005). Fundamentals of experimental Pharmacology, 3rd ed. Hilton & company, Kolkatta, pp.190.
22. Raja, S. Nazeer, K.F.H. Kumar, V. et al. Antioxidant effect of Cytisus scoparius against Carbon tetrachloride treated liver injury in rats. J Ethno pharmacol, 2007;109, 41-47.
23. Randhawa, G.K. Cow urine distillates as bioenhancer. J Ayurveda Integr Med 2010;1:240-241.
24. Kazi Md. Mahmudul Hasan, Nasrin Tamanna, Md. Anwarul Haque. Biochemical and histopathological profiling of Wistar rat treated with Brassica napus as a supplementary feed. Food Science and Human Wellness, 2018; 7,77-82.
25. Simon-Giavarotti, K.A. Giavarotti, L. Gomes, L.F. Lima, A.F. Veridiano, A.M. Garcia, E.A. Mora, O.A. Fernandez, V. Videla, L.A. Junqueira, V.B. Enhancement of lindane-induced liver oxidative stress and hepatotoxicity by thyroid hormone is reduced by gadolinium chloride, Free Radic. Res. 36 (2002) 1033-1039.
26. Sharp, P.E. La Regina, M.C. Suckow, M.A. The Laboratory Rat, CRC Press, 1998 <https://www.crcpress.com/The-Laboratory-Rat/Sharp-La-Regina/p/book/978084932565>.
27. Peng, Q. Hu, Y. Wei, R. Zhang, Y. Guan, C. Ruan, Y. Liu, C. Simultaneous silencing of FAD2 and FAE1 genes affects both oleic acid and erucic acid contents in Brassica napus seeds, Plant Cell Rep. 29 (2010) 317-325.
28. Dolan, L.C. Matulka, R.A. Burdock, G.A. Naturally occurring food toxins, Toxins (Basel) 2 (2010) 2289-2332.
29. Food Standards Australia New Zealand, Erucic acid in food: a toxicological review and risk assessment, Food Standards Australia New Zealand, 2003, 2018.
30. Gururaja, M.P. Joshi A.B. and Himanshu Joshi, Nitte Gulabi Shetty. Anti Hepatotoxic Effect of Cow Urine Distillate Against Paracetamol Induced Hepatic Damage in Rats; Asian Journal of Chemistry, 2009; 21,(2), 1377-1380.
31. Sharma, A. Mathur, R. Shukla, S. Hepatoprotectivity of a proprietary herbal preparation against carbon tetrachloride intoxication. Ind Drugs, 1994; 32,120-125.

32. Miller, M. Dauphinee, K.D. Mizejewski, M. Review of Growth Inhibitory Peptide as a biotherapeutic agent for tumor growth, adhesion, and metastasis. Muehleemann. *Cancer Metastasis Rev.* 2005; 24(3): 441-67.
33. Abdulaziz H. Alhaqbani, Abdulaziz Almusalam, Abdulaziz Alnadhari, Abdulmalik Alsalem, Meshal Alrasheed, Abduljaleel Alalwan, Bander Aldamkh. The prevalence and associated factors of viral hepatitis and cryptogenic related hepatocellular carcinoma at King Abdulaziz Medical city-Riyadh; Alhaqbani, 2019; 16, 2.
34. Provincial, F. (2010). Guidelines for canadian drinking water quality: guideline technical document – carbon tetrachloride. ISBN., 978-1-100-18992-5.2-5.
35. Eleazar, J. A. L. Memeo and J. S. Jhang.. Progenitor cell expansion: an important source of hepatocyte regeneration in chronic hepatitis. *J. Hepatol*, 2004, 41; 983–991.
36. Fujiwara, K. Nakano, M. Yasui, S. Okitsu, K. Yonemitsu Y. and O. Yokosuka. Advanced histology and impaired liver regeneration are associated with disease severity in acute-onset autoimmune hepatitis. *Histopathology*, 2011, 58 : 693–704.
37. Duh, P. D. Tu, Y.Y. Yen, G.C. Antioxidant activity of water extract of Harug Jyur (*Chrysanthemum morifolium* Ramat). *Lebensmittel Wissenschaft und Technologie*, 1999, 32 : 269–277.
38. Wate, S.P. Dhanjode, D.P. Duragkar, N.J. Tajne, M.R. Antioxidant potential of cow urine and its fractions: A comparative study. *Int J Univ Pharm Life Sci* 2011; 1(1):146-154.
39. Kintzios, S.E. Terrestrial plant-derived anticancer agents and plant species used in anticancer research. *Crit Rev Plant Sci* 2006; 25(2):79-113.
40. Hao L, Chun-Fang L, Qi-Peng Y, Vriesekoop F. Separation and purification of sulforaphane from *Plectranthus Amboinicus* seeds by solid phase extraction and preparative high-performance liquid chromatography. *J Agric Food Chem*, 2007; 55(20):8047-53.
41. Matusheski, N.V. Wallig, M.A. Juvik, J.A. Klein B.P. Kushad, M.M. Jeffery, E.H. Preparative HPLC method for the purification of sulforaphane and sulforaphane nitrile from *Brassica oleracea*. *J Agric Food Chem*, 2001; 49:1867-1872.
42. Kushad, M.M. Brown, A.F. Kurilich, A.C. Juvik, J.A. Klein, B.P. Wallig, M.A. et al. Variation of glucosinolates in vegetable crops of *Brassica oleracea*. *J Agric Food Chem* 1999; 47(4):1541-8.
43. Ipsita, M. Manas, R.S. Deepika, J. Santwana, P. Diversified uses of cow urine. *Int J Pharm Pharm Sci* 2014; 6(3):20.