Annals of R.S.C.B., ISSN: 1583-6258, Vol.25, Issue 4, 2021, Pages. 19123-19127
Received 05 March 2021; Accepted 01 April 2021

# Giant cell fibroma: Report of two cases with histochemical nature of collagen fibers

**Usha Hegde[1], Sreeshyla HS*[1], Priyanka Nitin[1], Premalatatha BR[1], Shirona AP[1]**

[1]Department of Oral Pathology & Microbiology, JSS Dental College & Hospital, JSS AHER, Mysuru, India

*sreeshylahs@gmail.com

**ABSTRACT**

Giant cell fibroma (GCF) is a benign, localized, fibrous mucosal mass of 1-2cm. It is a unique entity among the fibrotic soft tissue lesions. It is an uncommon lesion occurring on gingiva of the mandible, tongue and palate. It commonly occurs in young people with slight female predilection. Histologically the lesion contains giant cells in a matrix of dense collagen fibers. In contrast to the other fibrous lesions, the giant fibroblast is the prime feature of the lesion. They can be stellate shape, have dendritic processess or may be multinucleated. The etiopathogenesis and nature of the giant cells in this lesion is still provocative. The collagen component in any lesion has a pivot role in the prognosis of the lesion. As Giant Cell Fibroma is rich in collagen fibers, it is highly essential to understand the nature of these fibers to correlate with the nature of the lesion. Histochemical stains such as Van Gieson and Picrosirius red aids us in understanding the nature of these collagen fibers and gives an insight into the maturity of these fibers. However, at present the literature in this regard is sparse. This article attempts to elicit the nature of collagen fibers in two rare cases of Giant cell Fibroma along with their detailed case presentation.

**Keywords**

Collagen fibers; Fibrotic lesion; Giant cell fibroma; Histochemical stain; Palate, Picrosirius red

## Introduction

Weathers and Callihan in 1974 first described Giant cell fibroma (GCF) as a separate entity in reactive fibrous lesions (Weathers and Campbell, 1974; Datar et al., 2014). It is a non-neoplastic lesion that mimics other fibroepithelial lesions clinically, but identified as an entity based on the histopathological findings. GCF commonly occurs in 2nd-3rd decade of life, on mandibular gingiva and has a slight female predilection (Kuo et al., 2009). It presents as a slow growing, sessile or pedunculated, painless fibrous mucosal mass with papillary surface, of not more than 1cm in size (Kuo et al., 2009; Razi et al., 2020).

Etiology for GCF is not known, but the possible role of trauma or recurrent chronic irritation and the role of virus have been suggested (Reddy et al., 2015; Sonalika et al., 2014). The diagnosis of GCF is established based on the microscopic findings of an uncapsulated, non-inflammatory stroma with both spindle shaped and stellate shaped fibroblasts. These cells are mononucleated or multinucleated with vesicular nucleus having prominent nucleoli and well demarcated cytoplasm. Few cells also show dendritic processes. The deeper stroma consists of loosely arranged fibrous and vascular connective tissue with numerous spindle shaped fibroblasts along with blood vessels and few inflammatory cells, predominantly lymphocytes (Reddy et al., 2015; Kulkarni et al., 2017).

## Case Report

### Case 1

A 25year female patient visited the hospital with chief complaint of swelling in the upper left back tooth region since 2-3 months. The swelling was small initially and grew slowly to attain the present size. On intraoral examination a diffuse irregular swelling measuring about 5x4cm in size, distal to 28 extending into hard palate was noted. A smooth surfaced sessile, pale pink firm swelling that was well demarcated from the surrounding tissue was seen. A provisional clinical diagnosis of fibroma was given. (Figure 1a)

The distal extension of the large lesion was surgically removed and sent for histopathological examination. The gross specimen was single bit of soft tissue measuring about 2.0x1.5x0.4cm, creamish white in colour and firm in consistency. (Figure 1b)

60-year-old female patient complained of swelling in the right side of the hard palate since 6 months. On intraoral examination, a pedunculated pale pink firm swelling, measuring about 1cm in size, roughly oval in shape with irregular borders was noted. A provisional clinical diagnosis of fibroma was given. The lesion was excised and sent for histopathological examination. The grossed soft tissue specimen measured about

Annals of R.S.C.B., ISSN: 1583-6258, Vol.25, Issue 4, 2021, Pages. 19123-19127
Received 05 March 2021; Accepted 01 April 2021

1.0x0.8x0.6cm, was creamish white in colour and firm in consistency. The specimen was taken for processing. (Figure 2a)

## Case 2

Histopathological examination of Hematoxylin and Eosin (H & E) stained sections of the tissue from case 1 revealed epithelium and connective tissue. The epithelium is stratified squamous keratinized with reticular rete ridges. Juxtaepithelially the connective tissue was hyalinised showing moderate amount of spindle shaped fibroblasts. Few fibroblasts are stellate shaped exhibiting dendritic processes with one or two or multiple vesicular nuclei. Deeper connective tissue shows dense collagen bundles and focal inflammatory cells around the blood vessels. (Figure 1c & Figure 1d) Similar findings were seen in case 2. (Figure 2b & Figure 2c) Based on the above features a final diagnosis of giant cell fibroma was made in both the cases. In case 1 a complete excision was performed and follow up has been uneventful in both cases.

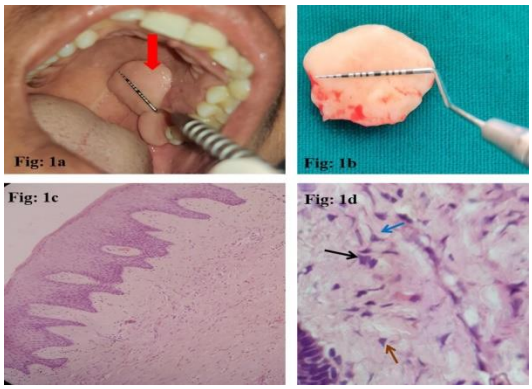


**Figure 1**: **1a** - Intra-oral photograph. **1b** - Gross specimen **1c** – Microscopic features (10X). **1d** - Multinucleated fibroblast (black arrow), fibroblast with dendritic process (blue arrow), stellate shaped fibroblast (brown arrow) (40X)

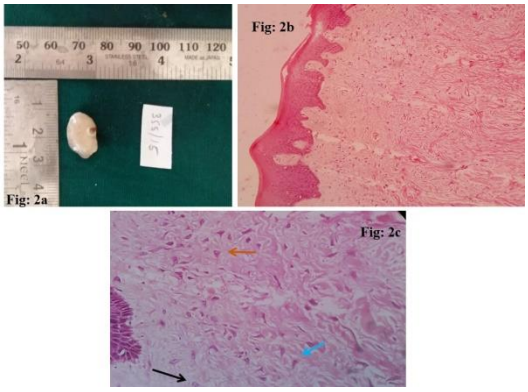


**Figure 2: 2a** - Gross specimen **2b** – Microscopic features (10X). **2c** - Multinucleated fibroblast (black arrow), fibroblast with dendritic process (blue arrow), stellate shaped fibroblast (brown arrow) (40X)

Both the cases were stained with Van Gieson to study the collagen fiber alignment and density. Van Gieson stained the collagen fibers red to orange and nucleus black to dark brown. In case 1, the fibers were tightly packed and arranged perpendicular to surface of the epithelium subepithelially and parallely arranged in the deeper connective tissue. (Fig. 3a) In case 2, the fibers were more tightly packed than in case 1 and arranged haphazardly both subepithelially and in deeper connective tissue. (Fig. 3b)

Annals of R.S.C.B., ISSN: 1583-6258, Vol.25, Issue 4, 2021, Pages. 19123-19127
Received 05 March 2021; Accepted 01 April 2021

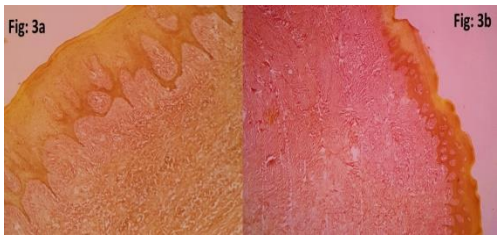


**Figure 3**: Van Gieson stain in case 1 (**3a)** case 2 (**3b)**

Picrosirius red staining was done in both the cases and observed under polarised microscope. Picrosirius stained sections of both case 1 and 2 revealed intermediate mixed fibers having all the birefringent colours. The intensity of green was more when compared to other colours in case 1 (Fig. 4a) and intensity of orange yellow was more in case 2. (Fig. 4b)




**Figure 4**: Picrosirius red stain in case 1(**4a)** case 2(**4b)**

## Discussion

A slow growing fibrous mass in the oral cavity mimics a number of non-neoplastic and neoplastic benign lesions. The demographic details will help us in narrowing the clinical diagnosis to a certain extent. But only a thorough histopathological examination will aid in the conclusive diagnosis of such lesions. GCF is one such lesion to be considered in the clinical diagnosis of sessile or pedunculated fibrous masses with papillary surfaces of not greater than 1 cm in size (Datar et al., 2014; Razi et al., 2020; Kulkarni et al., 2017).

Incidence of GCF is 2nd-3rd decade of life with a slight female predilection (Datar et al., 2014; Razi et al., 2020). A rare congenital case has been reported (Datar et al., 2014). Approximately 93%–97% of the reported cases are in Caucasians and rare in other races (Reddy et al., 2015). In the present reported cases, both occurred in females and case 1 in 2nd decade of life. But the age of occurrence in the 2nd case was unusual and occurred in 6th decade of life. Common sites of occurrence of GCF are mandibular gingiva, maxillary gingiva followed by tongue, buccal mucosa and palate ( Reddy et al., 2015; Sonalika et al., 2014). Both our cases occurred on the hard palate.

GCF presents as sessile or pedunculated pale pink growths with a papillary surface, not exceeding 1cm in size (Razi et al., 2020; Reddy et al., 2015). Both the cases reported here were sessile and pale pink. However, both of them had a smooth surface and case 1 presented as a large growth of 5x4cms.

Histologically, GCF presents an overlying stratified squamous keratinized epithelium with reticular rete ridges. The stroma shows unencapsulated mass of dense fibrous connective tissue with spindle shaped and large stellate, plump fibroblasts. Few stellate fibroblasts show dendritic cytoplasmic extensions with basophilic cytoplasm and large vesicular nuclei and prominent nucleoli. The fibroblasts can be uni, bi or multinucleated and are seen in the stroma just beneath the epithelium (Reddy et al., 2015; Sonalika et al., 2014). Similar histopathological findings were seen in both our cases that helped us in arriving at the final diagnosis of GCF. Rare case of GCF with melanin deposits has been reported (Kulkarni et al., 2017).

GCF contains collagen and lacks elastic fibers. These collagen fibers are observed to be more mature and dense (Datar et al., 2014). The distribution of type I and type III collagen fibers is found to be similar to that of normal

mucosa, indicating a normal collagen maturation process of type III to I. Greater amount of type I collagen has been identified in giant cell fibroma in individuals of less than 41.5 years, which reinforces the neoplastic nature of lesion (Schmidt et al., 2016). Van Gieson and Picrosirius red stains aid in studying the nature of collagen fibers and our both cases were studied with these histochemical stains.

Van Gieson stain is used to evaluate the density, arrangement and alignment of collagen fibers in relation to the epithelium. A study has reported tightly packed collagen fibers that were perpendicular to the surface of the epithelium in a case of GCF studied after Van Gieson staining (Datar et al., 2014). Case 1 showed similar findings, whereas case 2 showed haphazardly arranged tightly packed collagen fibers. (Fig. 3a & Fig. 3b)

Picrosirius red stained sections under polarised microscopy is used to evaluate the nature of the collagen fibers and thus to assess the course and prognosis of the lesions. Collagen molecules are rich in basic amino acids and hence normally react with acidic dyes. Picrosirius polarizing red special stain is one such acidic dye used to study the different collagen molecules. By staining with Picrosirius red, procollagen, intermediate and pathological collagen fibers, which are not tightly packed, can be differentiated (Zhang et al., 2011). The collagen fibers in GCF has been reported to show yellow, yellow-orange and green birefringence with the intensity of yellow and orange being more. This is suggestive of an intermediate, mixed type of collagen fibers in GCF, as thin immature fibers appear green-yellow to green in colour and thick mature collagen red-orange to red (Datar et al., 2014; Schmidt et al., 2016). In the current cases, similar intermediate mixed fibers were reported in case 2. Case 1 showed more of immature green birefringence. (Fig. 4a & 4b)

Presence of giant cell fibroblast clearly distinguishes the giant cell fibroma from other lesions. Two widely proposed theories put forth to explain the giant fibroblast formation in GCF are cell to cell fusion and mitosis without cytokinesis, with the former theory being widely accepted (Sonalika et al., 2014). It may also be similar to the process of wound healing, where the role of fibroblasts and its influence on extracellular matrix protein synthesis is well established. These cells appear spindle due to the cytoplasmic membrane laminae and have closed or open nucleus depending on its activity. During active synthesis phase the fibroblasts have tendency to fuse with one another (Sonalika et al., 2014).

The origin of the multinucleated and stellate cells in giant cell fibroma is still unknown. It is thought to arise from the melanocytes, langerhans cells, macrophage-monocyte lineage, myofibroblasts or fibroblasts (Weathers and Campbell, 1974; Kuo et al., 2009; Kulkarni et al., 2017; Campos and Gomez, 1999; Odell et al., 1994). Histochemical studies have ruled out the possibility of melanocytes, langerhans cells, macrophage-monocyte lineage and myofibroblasts (Weathers and Campbell, 1974; Kuo et al., 2009; Kulkarni et al., 2017; Campos and Gomez, 1999; Odell et al., 1994; Jimson and Jimson, 2013). However, minor subset of stellate giant cells are found to be monocyte macrophage lineage and they show close proximity to HLA-DR (Okamura et al, 2009). PCNA positivity and a negative Ki-67 immunoreactivity indicated the possibility of fusion of mononuclear fibroblasts (Kuo et al., 2009; Okamura et al., 2009; Mighell et al., 1996).

Positive staining with vimentin and prolyl 4-hydroxylase suggests a fibroblastic origin of these cells (Kuo et al., 2009; Campos and Gomez, 1999; Odell et al., 1994; Jimson and Jimson, 2013). These fibroblasts are also described to be mesenchymal cells which possessed the properties of both macrophage and fibroblast. However, it is difficult to determine whether these cells undergo functional or degenerative changes (Kuo et al., 2009; Kulkarni et al., 2017). Ultrastuctural studies have shown multinucleated giant cells and stellate cells to be unusual fibroblasts (Weathers and Campbell, 1974; Kuo et al., 2009).

## Conclusion

GCF is an uncommonly encountered oral mucosal mass. Its unique histopathological findings distinguish it as an entity. Yet there seems to be a lacuna in understanding its pathogenesis and behaviour. Though various histochemical and molecular studies have led to certain understanding of the lesion, clear cut conclusions are yet to be researched.

## Acknowledgment

Nil

## References

[1] Weathers, D. R., & Campbell, W. G. (1974). Ultrastructure of the giant cell fibroma of the oral mucosa. *Oral Surg Oral Med Oral Pathol*, 38, 550–61.

[2] Datar, U. V., Bhavan, C. M., Hallikerimath, S., Angadi, P., Kale, A., & Mane, D. (2014). Clinicopathological study of a series of giant cell fibroma using picrosirius red polarising micorsopy technique. *Arch Iran Med*, 17(11), 746-749.

[3] Kuo, R. C., Wang, Y. P., Chen, H. M., Sun, A., Liu, B, Y., & Kuo, Y. S. (2009). Clinicopathologial study of oral giant cell fibromas. *J Formos Med Assoc*, 108(9), 725–729.

[4] Razi, M. R. M., Harith, N. S., Tahir, N. F. M., & Selvaraj, N. (2020). Congenital giant cell fibroma – A case report. *MJPCH*, 26(1).

[5] Reddy, V. K. K., Kumar, N., Battepati, P., Samyuktha, L., & Nanga, S. P. (2015). Giant cell fibroma in a paediatric patient: A rare case report. *Case reports in dentistry*, Article ID 240374, 1-3.

[6] Sonalika, W. J., Sahu, A., Deogade, S. C., Gupta, P., Naitam, D., & Chansoria, H., et al,. (2014). Giant cell fibroma of tongue: understanding the nature of an unsual histopathological entity. *Case Reports in Dentistry*, Article ID 864512, 1-4.

[7] Kulkarni, S., Chandrashekar, C., Kudva, R., & Radhakrishnan, R. (2017). Giant-cell fibroma: Understanding the nature of the melanin-laden cells. *J Oral Maxillofac Pathol*, 21, 429-33.

[8] Schmidt, M. J., Tschoekea, A., Noronhaa, L., de Moraes, R. S., Mesquita, R. A., & Grégio, A. M. T., et al,. (2016). Histochemical analysis of collagen fibers in giant cell fibroma and inflammatory fibrous hyperplasia. *Acta Histochemica*, 118, 451–455.

[9] Zhang, J-Y., Dong, Q., & Li, T-J. (2011). Differences in collagen fibers in the capsule walls of parakeratinized and orthokeratinized odontogenic cysts. *International journal of oral and maxillofacial surgery*, 40(11), 1296-1300.

[10] Campos, E., & Gomez, R. S. (1999). Immunocytochemical study of giant cell fibroma. *Braz Dent J*, 10, 89-92.

[11] Odell, E. W., Lock, C., & Lombardi, T. L. (1994). Phenotypic characterisation of stellate and giant cells in giant cell fibroma by immunocytochemistry. *Journal of Oral Pathol Med*, 23, 284-87.

[12] Jimson, S., & Jimson, S. (2013). Giant Cell Fibroma: A Case Report with Immunohistochemical Markers. *JCDR*, 7(12), 3079-3080.

[13] Okamura, K., Ohno, J., Iwahashi, T., Enoki, N., Taniguchi, K., & Yamazaki, J. (2009). Giant cell fibroma of tongue: report of a case showing unique S-100 and HLA-DR immunolocalization with literature review. *Oral Med Pathol*, 13, 75-79.

[14] Mighell, A. J., Robinson, P.A., & Hume, W. J. (1996). PCNA and Ki-67 immunoreactivity in multinucleated cells of giant cell fibroma and peripheral giant cell granuloma. *J Oral Pathol Med*, 25, 193-99.

**Acknowledgements- Nil**

**Source of funding – Nil**

**Conflict of interest - Nil**