

Supraclavicular Block: A Review and Current Picture

Soumya Samal¹, Nupur Moda¹, Sushree Das¹, Swayamprabha Sahoo², Jatindra Nath Mohanty^{2*}

¹Department of Anaesthesiology, IMS and Sum Hospital, SOA deemed to be university
Bhubaneswar, India

²Medical Research laboratory, IMS and Sum Hospital, SOA deemed to be university
Bhubaneswar, India

Corresponding Author

Jatindra Nath Mohanty, Assistant Professor, Medical Research Laboratory, IMS and Sum
hospital, SOA deemed to be University, Bhubaneswar, Odisha, India

Mail ID- jatindranathmohanty@soa.ac.in

Abstract

The supraclavicular block is a territorial anesthesia procedure utilized as another option or aide to general anesthesia or utilized for postoperative agony control for furthest point medical procedures. Fringe nerve blocks have gotten significant in clinical practice in light of their part in postoperative relief from discomfort, shortening of patient recuperation time and evading chances and antagonistic impacts of general sedation. Thus, fringe nerve bar is currently an all around acknowledged idea for far reaching sedative consideration. Supraclavicular and infraclavicular blocks displayed positive qualities contrasted with the axillaries square. Supraclavicular brachial plexus block with the multi-injection intracluster procedure displayed essentially diminished absolute sedation related time and higher achievement rate with no early unfavorable occasions.

1. Introduction

Fringe nerve blocks have gotten significant in clinical practice on account of their job in postoperative relief from discomfort, shortening of patient recuperation time and dodging chances and unfavorable impacts of general sedation. Henceforth, fringe nerve bar is presently an all around acknowledged idea for extensive sedative consideration. Provincial nerve blocks depend on the idea that torment is passed on by nerve filaments, which can be intruded on anyplace along their pathway. For upper appendage medical procedures, brachial plexus block is the favored territorial sedation method [1]. Brachial plexus block [2] at the supraclavicular level gives sedation to the upper appendage medical procedures by hindering the center and lower plexus[3]. Neighborhood sedatives regulated as local nerve blocks give post-employable help with discomfort by hindering sign transmission to dorsal horn [4]. Bupivacaine is a long acting neighborhood anaesthetic[5]. Because of its long length of activity and joined with its top notch tangible barricade contrasted with engine bar it has been the most normally utilized neighborhood sedative for fringe nerve blocks. Ropivacaine is a fresher, long acting nearby sedative whose neuronal impeding potential utilized in fringe nerve bar is by all accounts

equivalent or better than bupivacaine.[6]Studies shows that it has altogether more noteworthy security edge over bupivacaine in light of lower CNS and Cardiac toxicity[7] and thus can be utilized in higher focuses. One of the disadvantages of ropivacaine referenced is its less extreme engine bar contrasted with bupivacaine.[8] Hence here is an endeavor through the investigation to contrast bupivacaine and ropivacaine in supraclavicular brachial plexus block[9]. This survey predominantly itemized on the supraclavicular block with all procedures and the board in various ways.

Strategies

The supraclavicular block is one of a few strategies used to anesthetize the brachial plexus. The square is performed at the level of the brachial plexus trunks where practically the whole tangible, engine, and thoughtful innervation of the furthest point is conveyed in only three nerve structures restricted to an exceptionally little surface region. Thus, this method normally gives an anticipated, thick square with fast beginning. In 1911, Georg Hirschel depicted a careful way to deal with the brachial plexus in the axilla. A couple of months after the fact, DiedrichKulenkampff, in Germany, played out the main percutaneous supraclavicular approach, purportedly on himself. The strategy was distributed in 1928 by Kulenkampff and Persky. As they portrayed it, the method was performed with the patient in the sitting position ("a standard seat will get the job done") or in the recumbent situation with a cushion between the shoulders. The administrator sat on a stool along the edge of the patient. The needle was embedded over the midpoint of the clavicle where the beat of the subclavian conduit could be felt and was coordinated medially toward the spinous cycle of T2 or T3. Kulenkampff 's knowledge of brachial plexus life structures permitted him to perceive that "the most ideal approach to arrive at the trunks was in the neighborhood of the subclavian corridor over the principal rib." His strategy was likewise straightforward: "all the parts of the plexus could be anesthetized through one infusion." These two attestations are as yet legitimate today. Lamentably,his recommendation on needle bearing conveyed a naturally high danger of pneumothorax. The notoriety of the supraclavicular block stayed unparalleled during the whole first 50% of the twentieth century until well after World War II. During this time the procedure went through a few adjustments, the greater part of them proposed to decrease the danger of pneumothorax. The presentation of axillary strategies by Accardo and Adriani in 1949 and by Burnham10 in 1958 denoted the start of the decrease in eagerness for the supraclavicular block [11].

The axillary square was especially advocated after a distribution in the diary Anesthesiology by Rudolph De Jong in 1961. The paper depended on body analyzations and incorporated the currently notable estimation of 42 mL as the volume expected to fill a chamber 6 cm long (axillary sheath); as per De Jong, this portion "ought to be adequate to totally wash all parts of the brachial plexus." The article was likewise disparaging of the supraclavicular approach. Circumstantially, a similar diary distributed a paper by Brand and Papper, who thought about axillary and supraclavicular strategies and cautioned of the 6.1% pace of pneumothorax often cited for supraclavicular block. More present day alterations of supraclavicular block incorporate

Alon Winnie and Vincent Collins' subclavian perivascular method and the "plumb-weave" procedure of Brown and colleagues. The previous is more an idea than a fundamentally extraordinary strategy, expressing that plexus sedation is performed around a primary vessel (perivascular) and inside the bounds of a sheath. Something else, their strategy is like Murphey's, who in 1944, depicted a solitary infusion procedure performed only parallel to the foremost scalene muscle coordinating the needle caudad[12].

The plumb-weave method, distributed in 1993, depends on corpse analyzations and attractive reverberation imaging performed on volunteers. In this strategy, the needle is presented over the clavicle, only horizontal to the sternocleidomastoid (SCM) muscle and progressed oppositely to the plexus in an anteroposterior heading. On the off chance that the needle misses the plexus, the pleural arch could be penetrated[13,14]. Numerous examiners seem to see the supraclavicular block as being intricate and related with a huge danger of pneumothorax. In any case, its fast beginning, thick and unsurprising sedation, and high achievement rate make it an extremely helpful methodology, which, as per Brown and colleagues, is "unmatched" by different strategies. To be sure, in our training, the supraclavicular approach is the foundation of distal furthest point local sedation, and we use it widely with an extremely low pace of difficulties.

Anatomy

- The anterior rami of C5 to T1 form the brachial plexus, which exits the cervical spine to form the superior, middle, and inferior trunks that travel between the anterior and middle scalene muscles.
- Each trunk divides into an anterior and posterior branch, which subsequently rejoins to form the lateral, posterior, and medial cords as it travels distally to the clavicle.
- The supraclavicular approach blocks the brachial plexus from the distal trunks to the proximal cords but often is targeted at the divisions level.

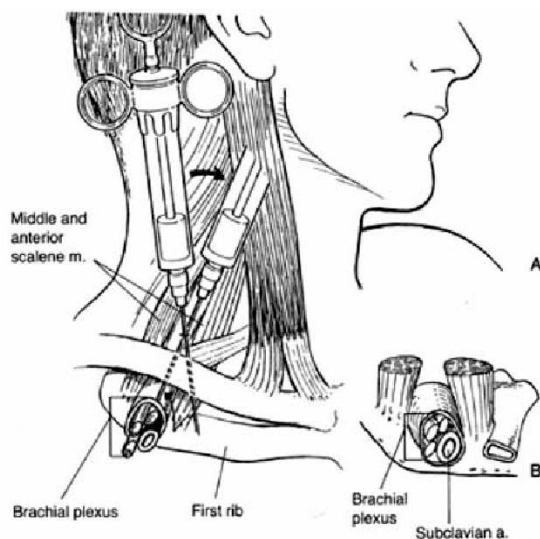


Fig 1: Anatomy

Contradiction

- Patient refusal
- Allergy to local anaesthetics
- Infection at injection site
- Malignancy at the needle entry site,
- Coagulopathy.
- Severe pulmonary disease
- Preexisting neural deficits

Equipments

The necessary equipment includes the following:

- Chlorhexidinegluconate or povidone iodine
- High-frequency ultrasound probe with sterile probe cover and gel
- Nerve stimulator (optional)
- Local anaesthetic, typically 1% lidocaine, for superficial layer local anaesthesia
- Regional block local anesthetic solution (0.5% bupivacaine or 0.5% ropivacaine for postoperative analgesia, and 2% lidocaine or 1.5% mepivacaine when shorter onset times are a necessity)
- 10 to 20 mL syringe with extension tubing
- Short bevel block needle (10 cm, 18 gauge for a continuous catheter or 22 gauge for single-injection)

Preparation

- The provider must perform an informed consent process.
- A pre-procedure pause is done, and the patient is placed in the supine position with arms by the sides.
- The head is turned towards the contralateral side of the block.
- Consider elevating the head of the bed about 30 degrees.
- A towel roll may be needed under the ipsilateral shoulder to improve access to supraclavicular space.
- Mild sedation may be provided (typically 1 to 2 mg of midazolam and 50 to 100 mcg of fentanyl are provided through an IV), though some patients may not require sedation.
- Aseptic technique is employed. Chlorhexidinegluconate 2% or povidone-iodine solution is applied to the skin.
- Sterile conduction gel is applied to the ultrasound probe, and the use of a sterile probe cover is recommended.

Procedures

- The ultrasound probe is placed in the supraclavicular fossa in the transverse orientation parallel to the clavicle and aimed inferior toward the ipsilateral thorax.
- The brachial plexus and the subclavian artery are visualized.

- The first rib appears as a hyperechoic line with the lung pleura deeper to this bony border.
- Utilizing the in-plane approach, the needle is advanced from lateral to medial, aimed for near the main neural cluster of the brachial plexus.
- After negative aspiration, local anaesthetic (about 10 mL) is injected.
- Subsequently, smaller aliquots of local anaesthetic are deposited near the surrounding satellite neural clusters. Injection should be stopped if the patient experiences paresthesia or pain.
- Another approach is "the corner pocket technique," first described by Soares and colleagues in 2007. This involves a needle trajectory aimed towards the deeper portion of the brachial plexus with the goal of local anaesthetic solution raising the brachial plexus off of the first rib. Then, the needle is retracted and advanced at a shallower angle, aiming toward the superficial brachial plexus. After negative aspiration, a local anaesthetic is injected (about 10 mL). This technique may have higher potential for pleural puncture[15].
- Nerve stimulation may be utilized as an adjunct to ultrasound. If this approach is utilized, the nerve stimulator must be connected before local anaesthetic injection. With contraction of the arm, forearm, or wrist occurs below 0.4 mA, intraneural needle position may be likely, and the needle should be withdrawn and redirected. Neural pressure monitoring during proximal brachial plexus blocks has also been recommended as a high opening injection pressure (greater than or equal to 15 psi) is associated with more needle-to-nerve contacts and intraneural injection.

Choice of Anaesthesia

The majority of furthest point medical procedures performed under territorial sedation last 1–3 hours. Therefore, we most ordinarily utilize 30 mL of 1.5% mepivacaine with 1:200,000 epinephrine, which gives around 3–4 hours of sedation. A similar sedative arrangement without epinephrine gives around 2–3 hours of sedation. To speed block beginning, 2 mL of 8.4% sodium bicarbonate might be added to each 20 mL of mepivacaine arrangement. Arrangements of levobupivacaine, ropivacaine, or bupivacaine give longer acting sedation (5–7 hours) when required. Ongoing examinations have recommended that the utilization of ultrasound direction may diminish the volume required for a fruitful square. For ceaseless methods, a bolus portion of around 10–15 mL of nearby sedative arrangement can be given, trailed by a mixture pace of 8–10 mL/h. An answer of 0.2% ropivacaine can be utilized for this reason. A patient-controlled bolus of 3–5 mL each 30–an hour can be added, with the basal implantation diminished to around 5 mL/h. Advancement torment should be treated with a bolus of neighborhood sedative in light of the fact that just expanding the pace of implantation could require a few hours to have an effect[16,17].

The patient that gets single-shot squares can go through a medical procedure under intravenous sedation titrated to the patient's solace. The sedation prerequisites shift from patient to patient

and reach from little irregular boluses of midazolam or fentanyl, to a propofol mixture at 25–50 mcg/kg/min, to light broad anesthesia[18].

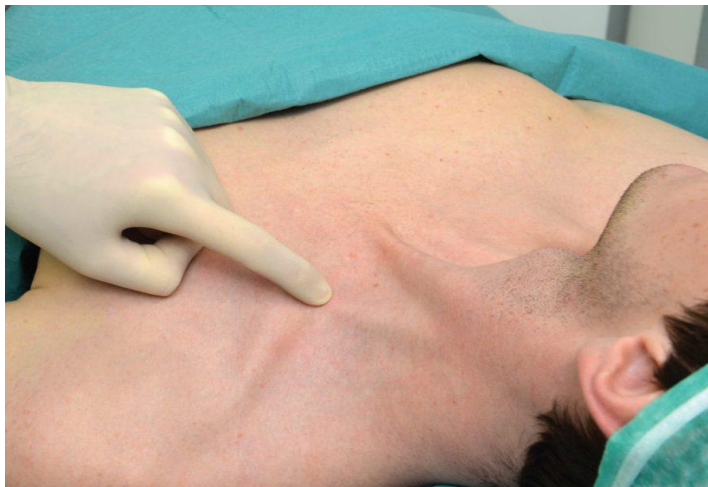

Fig 2: Area of anesthesia in a patient with proper position

Complication

Basic results related with this method incorporate phrenic nerve block with diaphragmatic loss of motion and thoughtful nerve block with improvement of Horner disorder. These are regularly self-restricting and don't need intercession. Phrenic nerve block purportedly happens about half of the time, albeit this might be decreased by the utilization of ultrasound direction. Intravascular infusion with foundational neighborhood sedative harmfulness and hematoma development can likewise happen. To lessen the danger, significant degree of carefulness is required because of the rich vascularity of the supraclavicular locale. On account of the supraclavicular block, this can be because of cut of the subclavian, cross over cervical or dorsal scapular conduits, which are all situated close to the plexus at this level[19-23]. Pneumothorax happens as regularly as 6.1%, which was an occurrence announced in 1961 that contrasted 230 continuous supraclavicular blocks and 246 successive axillary squares. Nonetheless, the correlation was neither blinded nor randomized, and the investigation utilized a few unique procedures. Conversely, this inconvenience is uncommon in the cutting edge writing. It is oftentimes referenced that the pneumothorax confounding a supraclavicular block has a deferred beginning. Albeit such cases have been distributed in the writing, the greater part of the pneumothoraces announced have been analyzed inside a couple of hours of the strategy and before the patient's release. In view of the accessible writing, the pneumothorax related with supraclavicular block is exceptional, regularly little, and it presents inside a couple of hours following the technique. In certain occasions its introduction can be deferred as long as 12 hours [23-26].

Conclusion

Supraclavicular block is a solid, fast beginning way to deal with brachial plexus anesthesia. The life systems of the brachial plexus, with its three trunks kept to a much-diminished surface territory, manages the cost of a high achievement rate for accomplishing sedation in the furthest

point beneath the shoulder. A mix of good anatomic information, straightforward tourist spots, and fastidious method are central for reliable achievement rate and restricting its potential for difficulties.

Reference

1. Hirschel G (1911-07-18). "Die anästhesierung des plexus brachialis fuer die operation en an der oberenextremitat" [Anesthesia of the brachial plexus for operations on the upper extremity]. 58: 1555–6.
2. Kulenkampff, D (1911). "Zuranästhesierung des plexus brachialis" [On anesthesia of brachial plexus]. 38: 1337–40.
3. Partridge BL, Katj J, Benirschke K. Functional Anatomy of the brachial plexus sheath: Implications for Anaesthesia. *Anaesthesiology* 1987; 66: 743.
4. Charles BB, Gary RS. Local anaesthetics. Miller's Anaesthesia 5th edition. New York; Churchill livingstone. 2000; 491-517
5. Singelyn F J. clinical application of Bupivacaine for upper extremity. *Current topics in medicinal chemistry*, 2001; volume 1 number 3: 219-225.
6. Lew D, Jerry D, V loka et al. Ropivacaine for peripheral nerve blocks: Are there advantages. *Techniques of Regional Anaesthesia and pain management* 2001; Volume 5 issue 2: 56-59.
7. Singelyn F J, clinical application of Ropivacaine for upper extremity. *Current topics in medicinal chemistry*, 2001; volume 1 number 3: 219-225.
8. Feldman HS, Arthur GR, Covino BG. Comparitive systemic toxicity of convulsant and supraconvulsant doses of intravenous ropivacaine, Bupivacaine and Lidocaine in the conscious dog. *Anaesthesia Analgesia* 1989; 69:794-801
9. Tripathi D, Shah K, Shah C, S Shah, E Das. Supraclavicular Brachial Plexus Block for Upper Limb Orthopedic Surgery: A Randomized, Double Blinded Comparison Between Ropivacaine and Bupivacaine. *The Internet Journal of Anesthesiology*. 2012 Volume 30 Number 4.
10. Moore D: Supraclavicular approach for block of the brachial plexus. In Moore D (ed): *Regional Block. A Handbook for Use in the Clinical Practice of Medicine and Surgery*, 4th ed. Thomas, Springfield, IL: 1981, pp 221–242.
11. Lanz E, Theiss D, Jankovic D: The extent of blockade following various techniques of brachial plexus block. *AnesthAnalg* 1983;62:55–58.
12. Urmey W: Upper extremity blocks. In Brown D (ed): *Regional Anesthesia and Analgesia*. Philadelphia, PA: Saunders, 1996; pp 254–278.
13. Kulenkampff D, Persky M: Brachial plexus anesthesia. Its indications, technique and dangers. *Ann Surg* 1928;87:883–891.
14. Labat G: *Regional Anesthesia. Its Technic and Clinical Application*. Philadelphia, PA: Saunders, 1922.
15. Patrick J: The technique of brachial plexus block anesthesia. *Br J Surg* 1940;27:734–739.

16. Murphey D: Brachial plexus block anesthesia: an improved technic. *Ann Surg* 1944;119:935–943.
17. Winnie A: *Plexus Anesthesia. Perivascular Techniques of Brachial Plexus Block.* Philadelphia, PA: Saunders, 1993.
18. Accardo N, Adriani J: Brachial plexus block: a simplified technic using the axillary route. *South Med J* 1949;42:920.
19. Burnham P: Regional anesthesia of the great nerves of the upper arm. *Anesthesiology* 1958;19:281–284.
20. De Jong R: Axillary block of the brachial plexus. *Anesthesiology* 1961;22:215–225.
21. Brand L, Papper E: A comparison of supraclavicular and axillary techniques for brachial plexus blocks. *Anesthesiology* 1961;22:226–229.
22. Winnie A, Collins V: The subclavian perivascular technique of brachial plexus anesthesia. *Anesthesiology* 1964;25:353–363.
23. Brown DL, Cahill D, Bridenbaugh D: Supraclavicular nerve block: anatomic analysis of a method to prevent pneumothorax. *AnesthAnalg* 1993;76:530–534.
24. Franco C, Vieira Z: 1,001 subclavian perivascular brachial plexus blocks: success with a nerve stimulator. *RegAnesth Pain Med* 2000;25:41–46.
25. Franco CD: The subclavian perivascular block. *Tech RegAnesth Pain Manage* 1999;3:212–216.
26. Haleem, Shahla; Siddiqui, Ahsan K.; Mowafi, Hany A. Nerve Stimulator Evoked Motor Response Predicting a Successful Supraclavicular Brachial Plexus Block; *More Anesthesia & Analgesia*. 110(6):1745-1746, June 2010.