

Comparison Analysis between of Software Imagej and Adaptive Region Growing Approach Android-Based in Determining the Width of Periapical Abscess Lesions

NurFadhilah Arifin¹, Masriadi¹, Mohammad Dharma Utama², Sarafin Aslan¹, Mila Febriany¹, Harun Achmad², Sitti Fadhillah Oemar Mattalitti¹, Amanah Pratiwi⁷, Karnila¹

¹Faculty of Dentistry, Moslem University of Indonesia, Makassar

²Faculty of Dentistry, Hasanuddin University, Makassar

*Corresponding author: email: lla.6191@gmail.com

Objective: To determine the possibility of existing difference of software ImageJ and Adaptive Region Growing Approach based on Android in determining the width of periapical abscess lesions.

Material & Methods: This Study was an observational analysis. This research was conducted in November until December 2019 at RSIGM UMI. The samples collected were 10 cases of radiography of periapical abscess. Digitalizing radiograph used software ImageJ and adaptive region growing approach android-based to examine a width number of lesions and then analyzed by Independent T-test. **Results:** the research found a difference broad measures of periapical abscess lesions with an average number of lesions on the software ImageJ of 3.87 mm² and Android applications 21.51 mm² (P-Value: 0.039) or (P < 0.05). **Conclusion:** it indicated significant differences between the measures of the full amount of periapical abscess lesions using software ImageJ and Android-based applications combined with software ImageJ.

Keywords: *Periapical Abscess, Method of Adaptive Region Growing Approach Android -based, Software ImageJ*

INTRODUCTION

Radiographic examination is one of the main diagnostic tools used in dentistry to determine the state of disease and formulate appropriate treatment. Dental radiography is a valuable diagnostic tool when image quality is adequate for proper interpretation. In many procedures, radiographic diagnostics are very important to determine a good treatment and treatment plan. Image quality will greatly affect the diagnosis. ^{[1][2]}

Periapical radiography provides important information about the teeth and surrounding bone. There are three types of intraoral projections: (1) periapical, (2) bitewing, and (3) occlusal. Intraoral periapical radiography is useful in most dental procedures. The main indications for this technique include detection of dental caries, periapical pathology, assessment of periodontal status, assessment of root morphology before extraction and during endodontic procedures, trauma to teeth and related structures, and assessment for implant surgery. ^{[3][4]}

Periapical lesions are lesions involving the apical area of teeth which are an advanced process of caries and pulp disease, which can also be caused by mechanical, thermal and chemical irritants. Classification of periapical lesions are apical periodontitis, acute alveolar abscess or acute periapical abscess, granuloma, and radicular cyst or periapical cyst. Pathogenesis of acute alveolar abscesses or acute periapical abscesses occurs when antibodies and bacteria reach a balance characterized by the formation of sinus tracts by the lymphatic system. On roentgenographic examination, radiolucent features appear clearly demarcated around apical teeth of varying sizes. Sometimes in some cases, radiolucency has very clear borders marked by radiopaque lines or sclerotic bone areas around the

lesion. This clear boundary is what distinguishes the radiographic picture between granulomas and abscesses, where in radiographic images of abscesses, radiolucency has no clear boundaries. ^{[5] [6]}

ImageJ software is not to be used as a substitute for Adobe Photoshop, GIMP, or other graphic editing programs. This is less centered on layers, transparency, filtering, measuring, and mathematical processing. This does not mean that images cannot be modified using ImageJ, the type of modification intended by ImageJ is of a different nature from the program mentioned earlier. ^[6]

Image processing technology can enter various fields such as medicine, industry, agriculture, geology, marine and so on. The presence of image processing technology provides extraordinary progress in these fields. In the future the application of digital image processing technology will continue to expand and this is a challenge for researchers and researchers in this field. The Adaptive Region Growing Approach method for contrast enhancement is proposed for periapical radiograph images. ^[7]

Based on the results of the 2017 Rikko study, the implementation of periapical radiographs using the Adaptive Region Growing Approach method and euclidean algorithm is able to detect pulpitis. Accuracy results are better for images that use segmentation with an accuracy difference of 10%, which means segmentation has the best effect on image detection and accuracy in detecting the system using a threshold value of 0.3 and a pixel size of 256 x 256 that is 70%. ^[8]

Research on the wide radiographic differences in periapical abscess lesions using ImageJ Software and the Android-based Adaptive Region Growing Approach method at UMI RSIGM has never been done before.

Based on preliminary surveys conducted by researchers in the radiology section of UMI Hospital, the average patient who had a periapical abscess had X-rayed periapical for endodontic treatment. Therefore, researchers are interested in conducting research to find out whether there are differences in radiographic features of periapical abscess lesion area using ImageJ Software and Android-based Adaptive Region Growing Approach.

MATERIALS AND METHODS

This research was conducted using an observational analysis study using a cross-sectional study approach using 10 secondary data periapical intraoral radiographs on suspected periapical abscesses in dental and oral hospitals at Muslim University of Indonesia. The study has passed the approval of the Indonesian Muslim University Health Research Ethics Committee with number 210 / A.1 / KEPK-UMI / VIII / 2019.

The collected data is then grouped into two namely imageJ software (National Institute of Mental Health, United States of America) data and adaptive region growing approach android-based (Telkom University, Indonesia) combined with ImageJ software. For the first data cropping and converting it into a threshold data then calculating the total area of the lesion. Calculation of the total area of the lesion is done by analyzing and measuring by entering the number (see figure 1) 3. Furthermore, for the second data processing images using the android application which is then performed (Insert) on the image, then (Cropping) and (Process). (see figure 2) Furthermore, the calculation of the total area of the lesion is done by inserting images that have been processed on Android to ImageJ software.

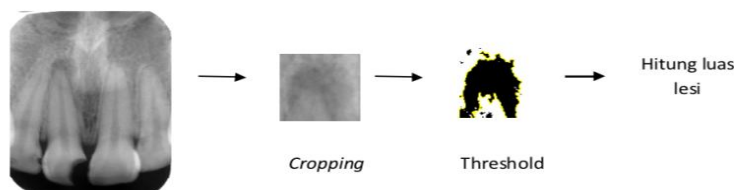


Figure 1. How to measure using ImageJ

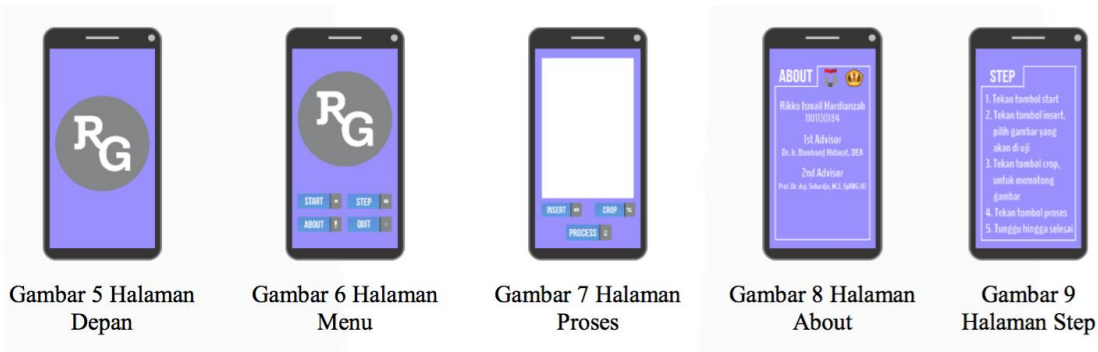


Figure 2. Improving image quality using Android

Research analysis was conducted to see the number of lesions in periapical abscess using ImageJ Software and Android-based Adaptive Region Growing Approach. The results are described in a table and then performed a statistical test using the Independent T test.

RESULT

This observational analysis research aims to determine whether there are differences in the ImageJ Software and Android-based Adaptive Region Growing Approach method in seeing the area of periapical abscess lesions. After a study of x-rays of patients at RISGM UMI obtained the number of lesions in periapical abscesses using ImageJ Software.

Table 1. Descriptive Statistics of the Amount of Lesion in Periapical Abscess using imageJ software

Sample	Software ImageJ	Mean± SD	Maximum	Minimum
Subject 1	2.80			
Subject 2	4.95			
Subject 3	3.43			
Subject 4	1.37			
Subject 5	5.22	3.87 ±2.13	8.23	1.37
Subject 6	2.29			
Subject 7	1.37			
Subject 8	8.23			
Subject 9	5.47			
Subject 10	3.62			

Based on table 1 and graphs obtained descriptive statistics on the number of lesions in periapical abscesses with ImageJ software. The results showed that the subject with the largest lesion area (maximum) ie in subject 8 was 8,23 mm². While subject 4 was the subject that had the smallest average number of lesions area among 10 other subjects which was 1,37 mm². The minimum value of the number of lesions in periapical abscesses using ImageJ software in the study subjects was 1,37 mm², while the maximum value of the number of lesions in periapical abscesses used ImageJ software in the study subjects was 8,23 mm². Based on table 1, it is also found that the mean (mean) number of trabecular particles in 10 study subjects is 3.88 mm² with a standard deviation or standard deviation from the average value of 2.13 mm².

Table 2. Descriptive Statistics of the Amount of Lesion in Periapical Abscess Using an Android Application Combined with ImageJ Software

Sample	Android application	Mean±SD	Maximum	Minimum
Subject 1	23.57			
Subject 2	23.63			
Subject 3	23.94			
Subject 4	71.67			
Subject 5	24.08	21.51±20.92	71.67	0.00
Subject 6	24.25			
Subject 7	23.99			
Subject 8	0.00			
Subject 9	0.00			
Subject 10	000			

Based on table 2 and graph 2 we get descriptive statistics on the number of lesions in periapical abscesses using the android application combined with ImageJ software. The results showed that subject 4 was the subject who had the largest average number of lesions area at 71.67 mm². While subject 1 is the subject that has the lowest average number of uses of the android application combined with ImageJ software among 10 other subjects that is 23,57 mm². The minimum value of the number of lesions in periapical abscesses using the android application combined with ImageJ software in the study subjects is 0,00 mm². While the maximum value of the total area of lesions in periapical abscesses using the android application combined with ImageJ software on the research subjects is 71,68 mm². Based on table 2, it is also found that the mean number of lesions in 10 study subjects is 21.51 mm² with a standard deviation or standard deviation from the mean value of 20.92 mm².

Table 3. Statistical Tests on the Difference in the amount of Lesions in Periapical Abscesses using ImageJ Software and Android Applications combined with ImageJ Software

Measurement	N	Mean	P-value
Software ImageJ	10	3.88±2.13	0,039
Android Application	10	21.51±20.92	

Based on table 3, the difference in the number of lesions in periapical abscess using ImageJsoftware and android application is combined with ImageJ software. From the results of research using the Independent T Test, there are 10 radiographic images of periapical abscesses. The average number using ImageJ software is 3.88 mm² and using the android application combined with ImageJ software is 21.51 mm². The standard deviation using ImageJ software is 2.13 mm² and using an android application combined with ImageJ software is 20.92 mm². The results of the Independent T Test also show the significance of the difference between using ImageJ software and the android application combined with ImageJ software, there is a significance value (P-Value) of 0.04. The P-Value value indicates less than 0.05 which means that there is a very significant difference between using ImageJ software and android applications that are integrated with ImageJ software. The results of research on the number of lesions using an android application combined with ImageJ software have increased compared to using ImageJ software. Thus the null hypothesis (H0) is rejected and the alternative hypothesis (Ha) is accepted

DISCUSSION

Based on table 4, there is a significant difference between the measurement of periapical abscess lesion area using ImageJ Software and Measurement using an Android-based application combined with ImageJ Software. The results of the study using the Independent T Test that there are differences in the accuracy of the measurement results of periapical abscess lesion area with ImageJ software and Android applications. Thus the null hypothesis (H₀) is rejected and the alternative hypothesis (H_a) is accepted.

Researchers argue that in making Android-based applications there are still deficiencies in the preprocessing part of filtering and binary to calculate the area of the lesion so that it gets very significant results in reading radiolucent and radioopaque images that affect the measurement results of periapical abscess lesion using ImageJ software and Android Application. It can be said that the results of the research still need to be developed in the future so that there are no more shortcomings, especially in the Android-based measurement system so that it will produce better results.

This is in line with research conducted by Rikko et al (2017), showing that based on the results of radiographic imaging studies using the Android-based Adaptive Region Growing Approach method is able to detect pulpitis with an accuracy rate of 70% on android. In addition, other studies from Auzan et al (2015), showed that the results of the study resulted in an increase in image quality so as to produce periapical radiographic images that have better quality. This shows an increase in image accuracy in this study, especially in the case of periapical abscesses by looking at the results of reading radiographic images on an android-based application to give a clearer difference in radiolucent and radioopaque images.^{[8][9]}

Periapical abscess is a collection of pus locally around the tip of the nonvital tooth root which is the result of pulp death. Periodontal abscesses may be acute or chronic. Description of acute periapical abscess is a collection of pus that is localized around the apex of a nonvital tooth that has a picture of the process of producing acute pus. Chronic periapical abscess is a collection of pus which is localized around the apex of a nonvital tooth that has the characteristics of a long, low level of pus, whether acute or chronic. Periapical abscesses generally originate from pulp tissue necrosis. Infected tissue causes some cells to die and break down, leaving cavities that contain infected tissue and cells.^[10]

Periapical abscess is an extension of pulp infection into periapical tissue, fracture of the tooth with an open pulp, perforation of the apical foramen during root canal treatment which causes the entry of pulp microorganisms into the periapical area. Many of the symptoms that can occur cause pulp necrosis if left untreated and depend on the virulent microorganisms involved and the overall integrity of the patient's defense mechanism. From its origin in the pulp, the inflammatory process extends to the periapical tissue, where it can be present as granulomas or cysts (if chronic) or abscesses (if acute). Acute exacerbations of chronic lesions can also be seen. Necrotic pulp tissue debris, inflammatory cells, and bacteria, especially anaerobes, all function to stimulate and maintain the periapical inflammatory process. Periapical periodontitis can develop into a periapical abscess where a collection of pus forms at the apex of the tooth, with the consequent spread of infection from the dental pulp. The symptoms are pain that can be continuous, throbbing pain.^{[11][12][13]}

Periapical abscess and focal inflammation of the tooth root occurs by penetration of bacteria into the pulp area, mainly of preceding dental caries and plaque formation on the site, which may allow the entry of bacteria into the soft tissues of tooth [1]. Localization of pus in the alveolar region at the root apex of tooth is a clinical definition used to explain dentoalveolar abscess. An abscess at the end of a tooth is called periapical abscess. Profound caries lesions may lead to invasion of microorganisms to the dental pulp. Periapical lesions develop as a sequelae to pulp disease. Periapical lesions can promote the development of dentoalveolar abscess and periapical bone loss. They are generally diagnosed examination or following acute pain in tooth.^{[14][15]}

Acute Apical Abscess is considered one of the most common causes of dental emergency. Tissue damage in this condition depends on the bacterial counts, virulence factors and host response. Acute apical abscesses (AAA) are caused by bacteria that egress the infected root canal and invade the periradicular tissues to establish an extraradicular infection and evoke purulent inflammation. Clinically, the disease is characterized by spontaneous pain, tenderness/pain to percussion and pain on palpation. The presence of soft-tissue swelling indicates diffusion through bone and may result in life-threatening conditions if immediate treatment is not provided. Acute apical abscess is caused by bacteria that leave the infected dental root canal to invade the periodontal tissues. Most species occurring in abscesses are also found in asymptomatic infections; therefore, the possibility exists that not only the presence of certain species but also their specific counts influence the appearance of symptoms.^{[16] [17] [18]}

Abscesses are associated with acute clinical signs and symptoms such as pain, suppurative exudation, and swelling. Histopathologically, periapical acute abscesses are characterized by an intense, localized 1,2 neutrophil and macrophage infiltration, diffused in a necrotic matrix surrounded by a fibrous connective tissue; lymphocytes and mast cells can be observed, but they occur in low numbers. diagnosis and management of necrotic dental pulp cases that are associated with apical pathosis possess difficulties. the role of bacteria and their toxic by-products in pathosis and manage the case properly by providing the appropriate treatment measures.^{[19] [20]}

The development of technology has developed very rapidly. No doubt this has helped a lot in the world of health in solving some of the existing problems. One of the technologies in the world of health that is used to detect internal disease is X-Ray. There is one application of X-Ray that is used by dentists to see all layers of teeth, namely periapical radiographs. However, the output of this tool does not always produce clear data or images. So that this affects the doctor's diagnosis. One way to improve the results of periapical is to use image processing. Through this digital image processing, it can help in answering these dental radiology challenges with more objective diagnosis. With Android-based tools, it is expected that usage will be easier and more efficient. The method used in this thesis is the Adaptive Region Growing Approach. This method is used to provide details of medical images based on the region created in the image.^[8]

Based on the results of the 2017 Rikko study, the implementation of periapical radiographs using the Adaptive Region Growing Approach method and euclidean algorithm is able to detect pulpitis. Accuracy results are better for images that use segmentation with an accuracy difference of 10%, which means segmentation has the best effect on image detection and accuracy in detecting the system by using a threshold value of 0.3 and a pixel size of 256 x 256 which is 70%.^{[8] [21] [22] [23] [24] [25]}

The variable that distinguishes the results of this study with previous research is the difference in the sample and the use of ImageJ Software used. This was done to see if there were differences in the radiographic features of periapical abscess lesions using ImageJ Software and the Android-based Adaptive Region Growing Approach method. Auzan et al in 2015 stated that by using the Android-based Adaptive Region Growing Approach method there was an increase in image quality so as to produce periapical radiographic images that have better quality.

CONCLUSION

The average number of lesions in periapical abscesses using ImageJ Software was 3.88 mm² and the average number of lesions in periapical abscesses using Android-based Adaptive Region Growing Approach and ImageJ Software was 21.51 mm². Based on the Independent T Test, it shows that there is a significance value (P-value) of 0.04. The P-Value shows less than 0.05 (p <0.05) meaning that there is a difference between the measurement of periapical abscess area using ImageJ Software and Measurement after using Android-based Adaptive Region Growing Approach and ImageJ Software.

SUGGESTION

The researcher should then conduct an initial survey on the application or software that will be used in the study and the researcher suggests conducting research on developing an Android-based Adaptive Region Growing Approach method to get better results related to the unit of measurement in the application

REFERENCES

1. Gupta A, Srivastava R, Jyoti B. Intra oral periapical radiography - basics yet intrigue : A review Intra oral periapical radiography - basics yet intrigue : A review. 2014;(August).
2. Yau H. An Adaptive Region Growing Method to Segment Inferior Alveolar Nerve Canal from 3D Medical Images for Dental Implant Surgery An Adaptive Region Growing Method to Segment Inferior Alveolar Nerve Canal from 3D Medical Images for Dental Implant Surgery. 2014;(October).
3. Langland OE, Langlais RP, Preece JW. *Principles of Dental Imaging*. Ed. ke-2. United States of America: Lippincott; 2002 : 202-204
4. Kumar R, Khambete N, Priya E. Extraoral periapical radiography : an alternative approach to intraoral periapical radiography. 2011;161–5.
5. Sabrina D, Pradono AR. Frequency and Distribution of Lesion of Periapical Based on Element Teeth, Location, Abnormal, Gender, and Size
6. Lesi. 2014 Perez JMM, Pascau J. Image Processing with ImageJ. Uk: Packt. 2013.
7. D. Putra, Processing Digital, Yogyakarta: CV. Andi Offset, 2010
8. Rakhma, Tranantika RTEU. Endodontic One Visitin Pada First Right Molar Mandible with Pulp Necrosis with Periapical Abscess dan Fistula. 2011;18 (1):117–21.
9. Hustanto AH, Bambang H, Suhardjo. Increase of Quality Periapical Radiograph with Detection Pulpitis Irreversible using Methods Adaptive Region Growing Approach. Yogyakarta. 2015: 418.
10. Iannucci, J & Howerton, L.J. *Dental Radiography: Principles and Techniques*. 5th edition. St. Louis Missouri. Elsevier/Saunders. 2017.
11. Purkait. S. K. Essentials of Oral Pathology. 3rd Edition. Jaypee brother medical publisher; 2011.
12. Regezi JA, Sciubba JJ, Jordan RCK. Oral pathology clinical pathologic correlations 6th edition. China: Elsevier. 2012; 316.
13. Haug RH. Oral and Maxillofacial Surgery Clinics Of North America. 2016;28(3):278–9.
14. Regmi S, Chaudhary SK, Gurung G, Bhandari S, K Rajeshwor Reddy. Bacteriology of Periapical Abscess and Antibiotic Susceptibility Pattern of the Facultative Anaerobes Isolated at Gandaki Medical College, Pokhara, Nepal. 2019;15(6):443–8.
15. Aeran H, Chandra S, Rautela M. Non-surgical management of a periapical abscess in a adolescent patient : A case report. 2017;3(December):240–3.
16. Quiñones J, Akemi M, Flores J, Rodriguez I, Nakagoshi E, González R. Endodontic management of acute apical abscess : A case report. Int J Appl Dent Sci. 2017;3(4):42–4.
17. Nóbrega LMM, Montagner F, Ribeiro AC, Mayer MAP, Gomes BPF. Molecular identification of cultivable bacteria from infected root canals associated with acute apical abscess. Braz Dent J. 2016;27(3):318–24.
18. Rôças IN, Siqueira JF. Frequency and levels of candidate endodontic pathogens in acute apical abscesses as compared to asymptomatic apical periodontitis. PLoS One. 2018;13(1):1–11.
19. Ferreira LG onçalve. V, Rosin FCP erill., Corrêa L. Analysis of Interleukin 17A in periapical abscess and granuloma lesions. Braz Oral Res. 2016;30(1):1–9.
20. Madarati AA. Preferences of dentists and endodontists, in Saudi Arabia, on management of necrotic pulp with acute apical abscess. BMC Oral Health. 2018;18(1):1–11.

21. Achmad H, Djais AJ, Petrenko EG, Larisa V, Putra AP. 3-d printing as a tool for applying biotechnologies in modern medicine. *International Journal of Pharmaceutical Research*, 2020. 12(4), pp. 3454-3463.
22. Achmad H, Djais AI, Jannah M, Huldani, Putra AP. Antibacterial chitosan of milkfish scales (*Chanoschanos*) on bacteria *porphyromonasgingivalis* and *agregatibacteractinomycetescommitans*. *Systematic Reviewa In Pharmacy*, 2020. 11(6), pp. 836-841.
23. Achmad H, Djais AI, Syahrir S, Fitri A, Ramadhany YF. A literature us regarding the use of herbal medicines in pediatric dentistry. *International Journal of Pharmaceutical Research*. 2020. 12,PP. 881-897.
24. Achmad H, Djais AI, Syahrir S, Fitria A, Ramadhany YF. Impact Covid-19 in pediatric dentistry: A literature review. *International Journal of Pharmaceutical Research*, 2020. 12,p.830-840.
25. Djais AI, Achmad H, Dewiayu D, Sukmana BI, Huldani. Effect of Combination of Demineralization Freeze Dentin Matrix (DFDDM/0 and *Moringaoleifera lam* osteoprotegerin(OPG) and receptor activator of nuclear factor kappa Bligand (RANKL) as a marker of bone remodeling. *Systematic Reviews in Pharmacy*. 2020. 11(6), pp.771-779.