

PREOPERATIVE AND POSTOPERATIVE AUDIOLOGICAL EVALUATION IN MYRINGOPLASTY

P. Fathima¹, S. Rajasekaran², M.K. Rajasekar³

^{1,2,3}Department of Otorhinolaryngology, SreeBalaji Medical College & Hospital, Chromepet, Chennai
*rajasekar.k@bharathuniv.ac.in

ABSTRACT

Chronic suppurative otitis media is characterized by hearing loss and ear discharge. Myringoplasty is one of the various surgical procedures for the management of chronic suppurative otitis media tubotympanic type. Myringoplasty is defined as surgical repair of tympanic perforation without ossicular reconstruction. It is a beneficial procedure done for closure of tympanic membrane and for hearing improvement.

Keywords: Myringoplasty, Tympanic membrane perforations, audiometry, ossicular chain, otitis media

Introduction

Chronic suppurative otitis media is the most common otorhinolaryngology problems and one of the major health problems around the world. Chronic suppurative otitis media is a chronic infection of mucosa lining middle ear cleft. Chronic suppurative otitis media is classified into active and inactive mucosal and squamous type. It is long standing infection of middle ear cleft characterized by ear discharge and its complications is the one of the life threatening conditions in early centuries. With introduction of antibiotics and use of microscopes and endoscopes in the surgical field, there have been revolutionary advances in the control of disease. It is a major cause of deafness in India. Prevalence of Chronic suppurative otitis media in developing countries is around 72 cases per 1,000 inhabitants and in world is over 20 million. In India, prevalence of chronic suppurative otitis media is approximately 2%.¹

Tympanic membrane perforations can lead to recurrent ear infections and hearing loss. In Brazil, studies had shown an association between chronic otitis media and hearing loss in school going children. Hearing loss in inactive mucosal (tubotympanic) disease is usually conductive hearing loss. In adults Chronic suppurative otitis media causes psychosocial challenges and affect the quality of the life.¹

Surgical intervention has become necessity to relieve the patients from their complaints and to reduce social disability among many peoples. Tympanic membrane reconstruction was attempted for many years. Different technique and grafts were used in reconstruction. Using pure tone audiometry hearing loss of patients can differentiated into conductive hearing loss or sensorineural hearing loss or mixed. Conductive hearing loss is reversible.

Myringoplasty is a reconstructive surgical procedure of tympanic membrane perforation in a normally functioning middle ear ossicles and patent Eustachian tube. Reconstruction of tympanic membrane provides a barrier between middle ear mucosa and the external pathogens. The goal of this surgery is to improve hearing by closure of perforation and eradicate middle ear disease. This prospective and observational study focus on to find the outcome of myringoplasty in term the hearing improvement after 3 months and 6months in different sizes of perforation taking into criteria of Air Bone closure and Air conduction threshold.

MATERIALS AND METHODS

A prospective quantitative study was conducted in SreeBalaji Medical College and hospital, chromepet, Chennai, India from November 2014 to September 2016. This study was done to

analyze hearing gain in patients with inactive mucosal (Tubotympanic) type of CSOM after myringoplasty. This study includes 50 patients from urban population of chromepet, Chennai attending outpatient department of ENT.

INCLUSION CRITERIA

Inactive mucosal CSOM (TT) type.

Unilateral chronic suppurative otitis media having conductive hearing loss.

Dry ear for 3months before myringoplasty. Size and location of perforation: small, medium, subtotal perforation. Conductive hearing loss less than 40dB.Middle ear conducting apparatus functioning normally.Normal Eustachian tube function in all patients.Adequate cochlear reserve.

Age between 20yrs to 45yrs,both males and females.

No focal sepsis of infection from nose and throat.

EXCLUSION CRITERIA

Active CSOM mucosal type (wet ear).

Unsafe type CSOM: Perforation in pars flaccid, cholesteatoma.

Marginal and total perforation in CSOM TT.

Patients having mixed or sensorineural hearing loss type.

Patients with vertigo and tinnitus.

Middle ear ossicles discontinuity and fixity.

Poor cochlear reserve.

Tympanosclerotic patch.

History of Revision myringoplasty in our institution and from other institutions.

Age less than 20yrs and more than 45 yrs.

Focal sepsis of infection from nose, mastoid and pharynx.

Immunocompromised disease in patients.

METHODOLOGY

Detailed clinical history and examination was done in all 50 patients who underwent myringoplasty. Pure tone audiometry was performed preoperatively and postoperatively in all patients using elkon audiometer in sound attenuated room. Air conduction and bone conduction threshold values are tested and plotted in a graph by audiologist. Pure tone average calculated to evaluate degree of hearing loss in decibels. All findings are documented as per proforma. Informed and written consent taken from all patients before surgery.

Clinical examination

In our study, detailed history which includes history of ear discharge, hearing loss and any associated symptoms such as vertigo and tinnitus.

Past history and treatment history such as medical and surgical management for the same complaints was taken.

General physical examination including systemic examination was done.

Examination of nose and throat

Clinical examination of nose and throat was done for selected patients.

Indirect laryngoscopy and diagnostic nasal endoscopy was done for all patients.

Examination of ear:

Examination of ear was performed by otoscope.

Examination under microscope (EUM):

Otosopic examination was confirmed by examination under microscope.

Visualization of external auditory canal and tympanic membrane

Perforation was classified into small, medium and subtotal depending upon size of perforation involving the number of quadrants of tympanic membrane.

Confirming inactive stage of CSOM type

Eustachian tube function was determined by Siegel's speculum and valsalva maneuver.

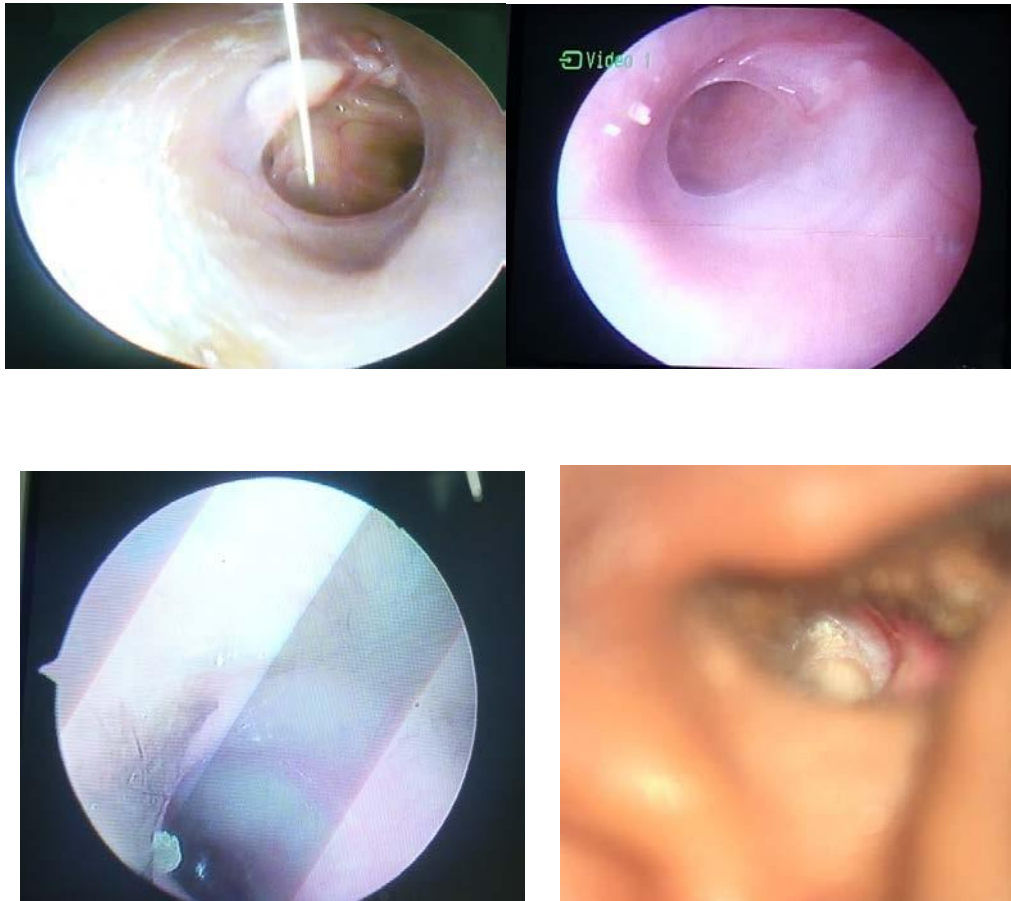


Fig 16: Types of Perforation

Turning fork test:

Turning fork tests include Rinne's, Weber and Absolute bone conduction test was performed using all the 3 frequencies that are 256, 512, 1024 KHz to determine the type and degree of deafness.

Rinne's test:- Air conduction (AC) and bone conduction (BC) compared.

Conductive deafness- $AC < BC$:- Rinne's test-negative

- Sensorineural deafness- $AC > BC$:- Rinne's test- positive
- False Rinne's test:- Severe sensor neural deafness.

Weber's test:- Bone conduction of both ears are compared

- BC lateralized to affected ear-conductive deafness.
- BC lateralized to normal ear-sensorineural deafness.

Absolute bone conduction (ABC) test:- Measures cochlear function.

- BC not reduced:- Conductive deafness
- BC reduced:- Sensorineural deafness

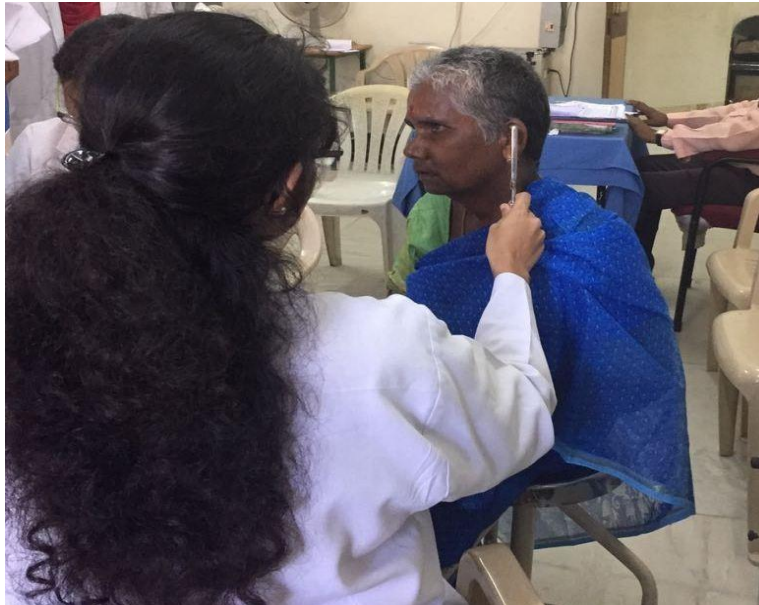

Fig 17: Examiner Performing Turning Fork Test

Pure tone audiometry:

Pure tone audiometry is used to determine hearing threshold sensitivity at discrete frequencies.

Pure tone audiometry performed preoperatively and postoperatively using clinical audiometer calibrated to ISO standard. Audiogram recorded at the frequencies 250Hz, 500Hz, 1000Hz, 2000Hz and 4000Hz Air conduction and bone conduction threshold values was plotted in a graph by a trained audiologist.



Fig 18: Audiologist Performing PTA

Degree of hearing loss in decibels was calculated by pure tone average. The preoperative and postoperative air bone gap was determined at the frequencies 500Hz, 1000Hz and 2000Hz. All the data was documented.

Preoperative investigations

The following investigation was taken for the study group

1. X-ray mastoid (Schullre's view): Type of mastoid pneumatisation.
2. Complete hemogram, fasting and postprandial blood sugar and serum electrolytes.
3. X ray paranasal sinuses: For sinus pathology.
4. X-ray chest PA view.
5. ECG.

Surgical procedure

Anaesthesia:

Endoscopic Myringoplasty was done under General anaesthesia (GA) in all selected patients.

Preparation of the patient:

A 2-3cm area of hair was shaved above and behind auricle.

Patient positioning

The patient's head was placed on doughnut shaped pillow for stability of head and also allows the head to be rotated along axis of neck. The patient was brought close to the edge of bed.

Surgical technique

Underlay technique of Myringoplasty was performed for all patients using a 0 degree Hopkins rigid endoscope.

1. Skin preparation and graft harvesting:

Using post aural incision temporalis fascia graft harvesting was done. Skin was cleaned using betadine solution and dried. Using 2% lignocaine with 1:100000 adrenaline infiltrations were given. Using Mollison's self retaining haemostatic mastoid retractor was inserted to expose areolar tissue and incised along linea temporalis. Areolar tissue was dissected from temporalis fascia using fresh 15" scalpel blade. A large piece of temporalis fascia graft was harvested. Graft was placed on a Teflon block, tease out to a thin uniform layer and was allowed to dry. The external auditory canal was flushed with betadine solution and the debris was removed.

Transcanal exposure:

Using 2% lignocaine with 1:100000 adrenaline solution four quadrants of cartilaginous part of external auditory canal and bony canal were infiltrated using ear speculum.

Freshening of margins of perforation:

Using 00 degree Hopkins's endoscope, the rim of tympanic membrane perforation was excised and the under surface of the remnant tympanic membrane denuded of squamous epithelium.

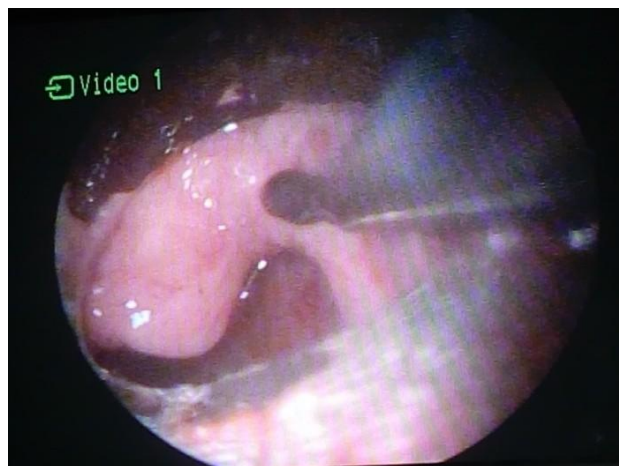


Fig 19: Freshening of Margins of Perforation

Canal incisions and elevation of tympanomeatal flap. Using Beaver knife blade a vascular strip was outlined by making incisions at the tympanosquamous and tympanomastoid suture lines. A small incision was put inferiorly and superiorly based flaps were created by making right angled incisions to the vascular strip incisions. The medial end of the vascular strip was formed by connecting the two primary incisions approximately 2mm lateral to annulus. The skin of the inferior ear canal was elevated down to the fibrous annulus creating a flap. The fibrous annulus was mobilized out of its sulcus and displaced anterior to malleus. The under surface of the tympanic membrane remnant was then denuded using sickle knife and a cupped forceps. The manubrium of the malleus was denuded, preserving the annulus. Haemostasis was achieved prior to graft placement with gel foam.

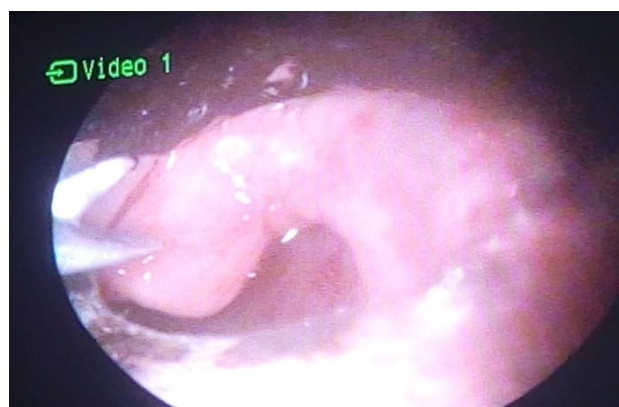

Fig 20: Tympanomeatal Flap

2. Assessment of ossicular chain:

The status of middle ear ossicles was evaluated for continuity and mobility in each patient and was found to be intact in all patients. Ossicular integrity is checked by applying mild pressure at handle of malleus and observing the movement of incudo-stapedial joint. Round window reflex was elicited and was present in all patients.

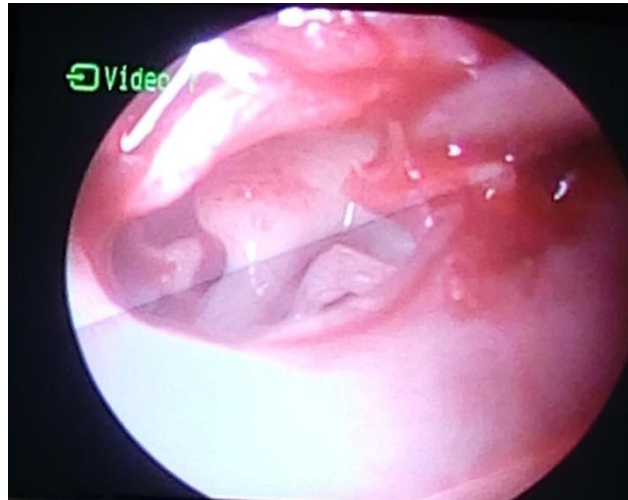

Fig 21: Ossicular Chain

3. Preparation of graft bed and graft placement:

The graft was trimmed to size and a slit was made in the superior aspect of the graft to accommodate medial to the manubrium placement. Gel foam placed at the Eustachian tube region in the middle ear. With the right angle hook the graft was slid medial to the manubrium and onto the lateral attic wall. Using House annulus elevator, graft was tucked under the drum remnant anteriorly and inferior. The remaining graft was draped along posterior canal wall and canal flap was repositioned over the graft. All edges of the annulus were evened and smooth out the graft. Gel foam was placed in external auditory canal.

4. Closure:

Post auricular suture was done with 4-0 ethylone suture material for all cases. Mastoid dressing was done.

Postoperative care:

All patients were kept nil per oral for 5 hours following GA.

- Intravenous broad spectrum antibiotics, ceftriaxone were administered for all patients. Analgesics, antihistaminic and multivitamin were given for about 5 days.
- In all patients mastoid dressing changed after 48hrs.
- All the patients were discharged with mastoid dressing after 5 days.

- All the patients were advised for suture removal on eighth day after surgery.

Postoperative advice

The following advice was given to all patients:

1. Avoidance of the head bath for three weeks
2. Swimming and air travel should be avoided for about at least one month
3. Avoid excess blowing of nose.

Follow up

All the patients were followed regularly for 6 months period in this study group. Follow up done weekly for one month followed by once in 4 every week.

During the follow up period the hearing assessment with tuning fork tests and pure tone audiometry was done after three months and six months in all patients after myringoplasty. The improvement of AB gap was documented during the follow up period. After six month follow up we calculated hearing improvement by reduction of AB gap. We considered the hearing gain in all patients as the success of myringoplasty. The postoperative AB closure less than 10dB was considered successful.

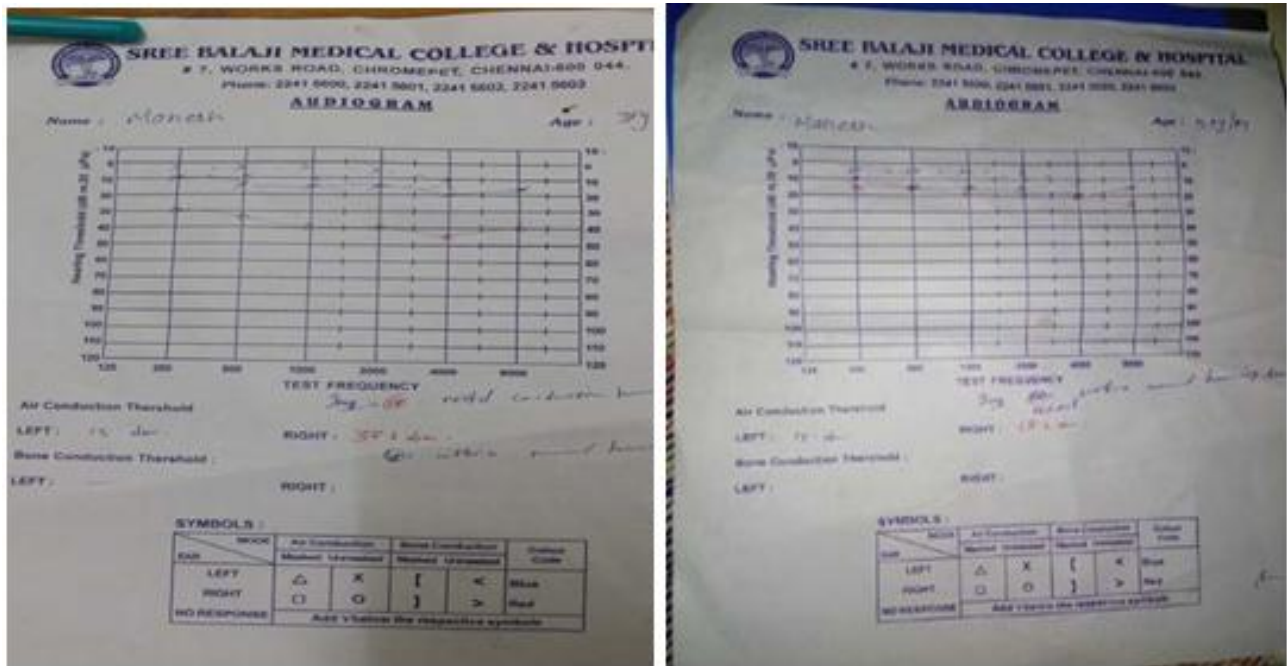

Fig 22: Preoperative PTA Fig 23: Postoperative PTA

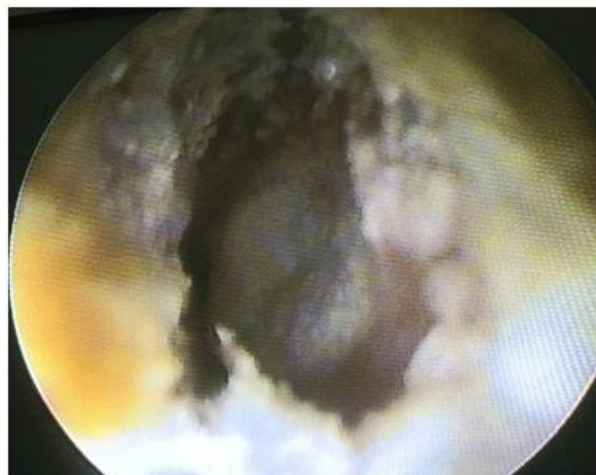

Fig 24: Postoperative Graft Uptake

RESULTS

In our study, 50 patients who underwent myringoplasty were included. We analyzed the age, sex incidence and various other factors influencing the audio logical benefit postoperatively.

Table 1: Age Distribution in our Study Population

AGE (IN YEAR)	NO OF PATIENTS	PERCENTAGE
20-25	6	12%
26-30	15	30%
31-35	10	20%
36-40	11	22%
41-45	8	16%

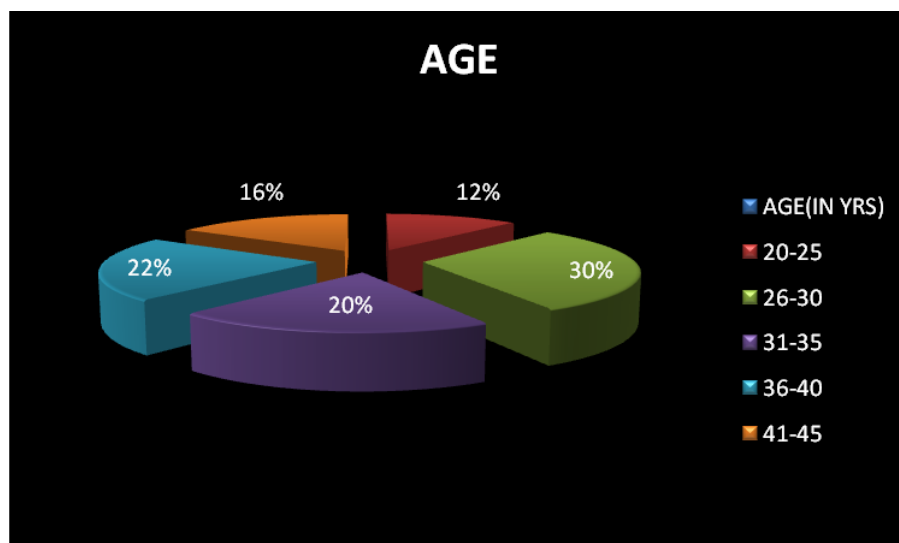


Chart 1: Showing Age Distribution in study population

In our study, 50 myringoplasty were performed between age group 20yrs to 45yrs.

Table1: Illustrates range and frequency of study population in which large number of patients were between the age group 26-30yrs which was 15(30%) followed by 11(22%) patients belonging to 36-40yrs age group.

Table 2: Sex Distribution In Study Population

AGE (IN YEARS)	MALE	FEMALE	TOTAL
20-25	3	3	6
26-30	9	6	15
31-35	3	7	10
36-40	7	4	11
41-45	4	4	8
TOTAL	26	24	50
PERCENTAGE	52%	48%	100%

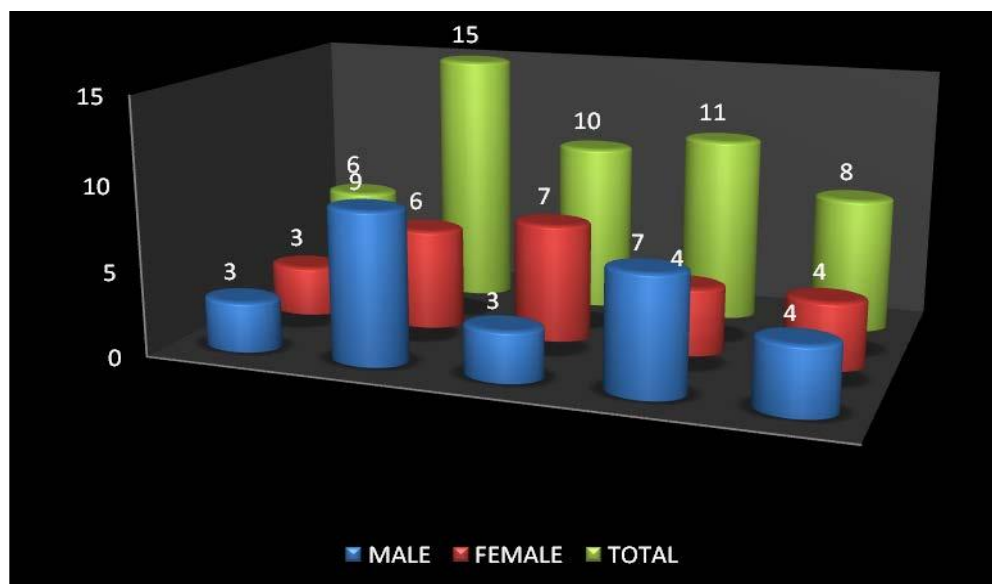


Chart 2: Graphical Representation of Sex Distribution in Study Population

In our study, overall 26(52%) males and 24(48%) females underwent myringoplasty. Age group of 20-45yrs were included. Males were more common than female with sex ratio of Male: Female 1.1:1.

Table 3: Number and Size of Perforation and Audiological Benefit

SIZE	NUMBER OF PATIENTS	MEAN PREOP AC THRESHOLD	MEAN POSTOP AC THRESHOLD	PERCENT	VALID PERCENT	CUMULATIVE PERCENT
Small	4	34.15	23.45	44.0	44.0	44.0
Medium	22	36.99	22.77	8.0	8.0	52.0
Subtotal	26	37.53	23.17	48.0	48.0	100.0

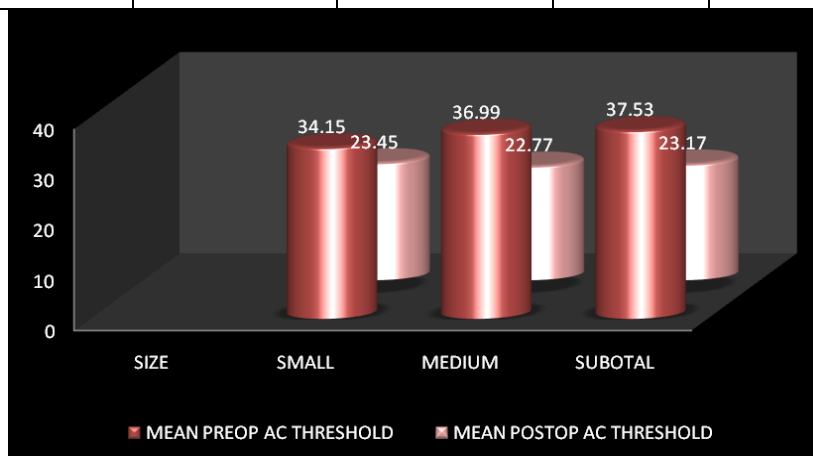


Chart 3: Graphical Representation Showing Incidence of Size of Perforation And Audio logical Benefit

In our study, out of 50 patients who underwent myringoplasty, 4(8%) patients had small perforation and 22(44%) patients had medium and rest 26(52%) patients had subtotal perforation.

DISCUSSION

CSOM is one of the commonest otorhinolaryngology problems in developing countries. It is characterized by chronic inflammation of mucoperiosteal lining of middle ear cleft.³⁹ It is classified into healed CSOM, inactive mucosal CSOM, active mucosal CSOM, inactive squamous CSOM and active squamous CSOM. In Clinical practice the most common is inactive mucosal CSOM (tubotympanic) type and is characterized by perforation in pars tensa of tympanic membrane, ear discharge and hearing loss. Tympanic membrane perforation usually results from middle ear infection, trauma and iatrogenic causes. Different types of perforation include central, marginal and attic. Two types of hearing loss are present such as conductive hearing loss and sensorineural hearing loss. Patients present with complaints of hearing loss and ear discharge which is profuse and mucoid. Spontaneous healing of perforation is uncommon and medical management is ineffective in this regard. This type of disease is treated medically to become inactive dry stage.

Hence surgical intervention is required for closure of perforation and in turn hearing improvement. Myringoplasty is a type of tympanoplasty in which the reconstruction procedure is limited to the repair of tympanic membrane perforation alone. It is a safe and effective procedure to improve the quality of life of patients by avoiding continuous infection and allowing them in contact with water such as swimming. Ideal candidates for myringoplasty should have dry central perforation, normal middle ear mucosa, normal Eustachian tube function, good cochlear reserve

and intact ossicular chain. Several factors influence surgical results such as age, size of perforation, site of perforation, status of contra lateral ear, status of middle ear mucosa and type of graft.^{7,8} Temporalis fascia graft was first used in myringoplasty by Ortergren (1958-1959) because it's easy to harvest and no size limitations.¹³ Pure tone audiometry has become one of the standard methods for quantitative description of degree of loss of hearing and also it provides information regarding the localization of lesion that causes loss of hearing. Quantitative assessment of deafness from air conduction threshold levels.³

0 -25dB:- Normal

26 -40dB:- Mild Deafness

41 -55dB:- Moderate Deafness

56 -70dB:-Severe Deafness

71 -90dB:- Very Severe Deafness

≥91dB:- Profound Deafness prospective study was conducted on a total of 50 cases of myringoplasty and hearing improvement was analyzed. The present study describes various parameters influencing hearing improvement after successful myringoplasty. Preoperative and Postoperative audiological evaluations were done after 3 and 6 months following myringoplasty.

AGE INCIDENCE:

In the present study all fifty patients between age group of 20yrs to 45ys underwent myringoplasty under general anaesthesia. We observed, majority of the cases were within the age group of 26-30yrs which is 15(30%) out of 50 patients followed by 11(22%) patients among 36- 40yrs age group. Rest of the six patients were in age group 20-25 yrs and 11 patients in age group of 36-40yrs.

In earlier studies conducted by many authors such as J Bennett's the average age of patient was 21.5 yrs. In another study by J B Booth the youngest was 8yr and oldest was 67yrs. From these studies it was concluded that hearing improvement was seen at an age group of 10-50ys.^{40,41} Ortergren reported that beyond age of 40yrs hearing results are worse than younger patients. But in our study, if there is good cochlear reserve, hearing improvement is seen in older patients as well.^{13,39} This is in contrast to the study conducted by Ortergren where the maximum patients were in age group more than 40yrs (25%).¹³

In 1985, Vartianen et al conducted study on 404 patients who underwent myringoplasty. He concluded that results in elderly patients were found to be good as in younger patients.²⁰ In another study, Habib Ur Rehman et al had shown graft was taken up successfully in 80% cases. They concluded success rate is affected by various factors especially age, size of perforation, graft used, mastoid cellularity and Eustachian tube function.^{42,43}

In 1994, Alexander Kessler et al conducted a study where he concluded that re-perforation was commonly seen in patients younger than 6 years.²⁹ In 2002, N Gupta and R K Mishap showed that the success rate was higher in 12-15 years age group (90.24%) than in 8-11 yrs age group (81.8%).⁴⁴ In 1984, Warren Y. Adkins & Benjamin White concluded in their study the age of patient to have no affect on success of myringoplasty. Similarly Schukecht and lee (1971), Booth (1974), Sade et al (1981) concluded in their study that age has no role in success of myringoplasty. Also in another study, Fadl found age factor have no influence on success of graft take up.^{41,45-49} In 1995, Quraishi et al concluded that the average age of patients were 33 and 33 yrs in the control and study group.⁵⁰

SEX INCIDENCE

According to the review of literature there is no statistical significant relationship between the sexes with audiological benefit. In our series, we performed Myringoplasty in 26(52%) males and 24(48%) females. Males were more common than females with sex ratio of Male: Female 1.1:1.

The P value of our result was not significant, which was more than 0.001, which showed there was no statistical relationship between the sexes with audiological benefit. Hence gender has no role in the success of myringoplasty.

In 1974, Booth concluded in his study that there was more failures in females compared to men with regard to graft take up.⁴¹ In 1994, Saeed and Ghamadi conducted a study on factors influencing the success of surgery and they had 59% males and 40.95% females. In another study conducted by Ajmal they had 58.4% of males and 41.6 females. Both these studies concluded that males are more common than females.^{21,51} In recent series, conducted in Maharashtra out of 120 patients, 68(56.6%) were males and 52(43.3%) were females. Similar incidence was seen in a study conducted by Dornhoffer where 55% males and 5% females underwent myringoplasty. In another study by Strahan et al 62% were males and 38% were females.⁵²⁻⁵⁴

SIZE OF PERFORATION

The size of the perforation generally will not influence surgical outcome and hearing gain. We have considered small, medium and subtotal perforation depending upon involvement of number of quadrants of pars tensa of tympanic membrane. Among our study group, 4(8%) patients had small perforation and 22(44%) patients had medium and rest 26(52%) patients had subtotal perforation. The maximum number of patients was having subtotal perforation. Subtotal perforation was found in a similar study population by Indorewala.⁴² The present series analysed Preoperative and postoperative air conduction threshold for each size of perforation. In small perforation patients, mean preoperative AC threshold was 34.15dBHL and postoperative AC threshold was 23.45dBHL. In medium perforation, patients mean preoperative AC threshold was 36.99dBHL.

CONCLUSION

In literature, several studies analyzed surgical outcome and hearing gain after the myringoplasty. In developing countries especially India awareness of chronic suppurative otitis media and benefits of myringoplasty in regard to hearing improvement is very less. This hearing impairment affects the quality of the life of the patient. The degree of hearing improvement depends on several factors such as size and site of perforation, ossicular status, surgical techniques, and type of graft and function of eustachian tube.

A prospective analysis was done from the urban population to assess the hearing gain after myringoplasty in our institution. The objective of study is hearing gain after myringoplasty by comparing AB gap closure before and after surgery. The success depends on proper selection, proper workup and well planned surgery. In the present study, mean AB closure was 13.984dB and successful graft taken was 92%. Through our series overall analysis showed age, gender, size of perforation has no influence in hearing outcome and success of surgery.

Funding: No funding sources

Ethical approval: The study was approved by the Institutional Ethics Committee

CONFLICT OF INTEREST

The authors declare no conflict of interest

ACKNOWLEDGMENTS

The encouragement and support from Bharath University, Chennai is gratefully acknowledged. For provided the laboratory facilities to carry out the research work.

REFERENCES

- [1] Gelfand, Stanley A. (2009). *Essentials of Audiology* (3 ed.). New York: Thieme Medical Publishers, Inc. p. ix.
- [2] *Clinical audio-vestibulometry for otologists and neurologists*. Biswas, anirban 3rd edn.
- [3] Banzer M. *Disputatio de Auditione Laesa*. Wittenbergae Johannis Rohrerei; 1651.
- [4] Toynbee J. *On the use of an artificial membrane in cases of deafness dependent upon perforations or destruction of the natural organ*. London: J Churchill & Sons; 1853.
- [5] Berthold E. *Uebermyringoplastik*. *Wier Med Bull* 1878; 1: 627.
- [6] Wullstein H. *Theory and practice of myringoplasty*. *Laryngoscope* 1956; 66: 1076-93.
- [7] Zollner F. *The principles of plastic surgery of the sound-conducting apparatus*. *J Laryngol Otol* 1955; 69: 637-52.
- [8] Shea JJ., Jr *Vein graft closure of eardrum perforations*. *J Laryngol Otol*. 1960;74:358–362.
- [9] Tabb HG. *Closure of perforations of the tympanic membrane by vein grafts: a preliminary report of 20 cases*. *Laryngoscope*. 1960;70:271.
- [10] Storrs LA. *Myringoplasty with the use of fascia grafts*. *Arch Otolaryngol*. 1961;74:65–69.
- [11] Austin DF, Shea JJ., Jr *A new system of tympanoplasty using vein graft*. *Laryngoscope*. 1961;71:596–611.
- [12] Ortegren U. *Myringoplasty, four year experience with temporal fascia grafts*. *Acta Otolaryngol Supple.*, 1964; 193: 1- 43.
- [13] Palva T, Palva A, Karja J. *Myringoplasty*. *Ann Otol Rhinol Laryngol*. 1969;78:1074–1080.
- [14] Glasscock ME. *Tympanic membrane grafting with fascia: overlay vs. under surface technique*. *Laryngoscope*. 1973;83:754–770.
- [15] Packer P. et. al. (1982) *What is best in Myringoplasty, dura or fascia* -*Journal of Laryngology and otology*. 96:25-29.
- [16] Sheehy JL, Anderson RG. *Myringoplasty: a review of 472 cases*. *Ann Otol Rhinol Laryngol*. 1980;89:331–334.
- [17] Alan Gibb and Sing-Kiat Chang: *Myringoplasty (A Review of 365 operations)*; *Journal of Laryngology and Otology* 1982; 96; 915-920.
- [18] Yung MW. *Retraction of the pars tensa—long-term results of surgical treatment*. *Clin Otolaryngol Allied Sci*. 1997;22:323–326.
- [19] *Success and pitfalls in myringoplasty: follow-up study of 404 cases*. Vartiainen E, Nuutinen J. 1993 May; 14(3): 301-5.
- [20] Saeed A and Ghamdi Al. *Tympanoplasty: factors influencing surgical outcome*. *Ann Saudi Med* 1994; 14: 483-485.

- [21] Black JH, Wormald PJ. Myringoplasty- effects on hearing and contributing factors. SAfr Med J. 1995 Jan;85(1):41- 3.
- [22] Kotecha ClinOtolaryngol 1999, 24(2):126-9.
- [23] Mak D, Mackendrick A, Bulsara M, Coates H, Lannigan F, Lehman D, et al. Outcomes of myringoplasty in Australian aboriginal children and factors associated with success: A prospective case series. ClinOtolaryngol Allied Sci 2004;29:606–11.
- [24] Matsuda Y, Kurita T, Ueda Y, Ito S, Nakashima TJ LaryngolOtol Suppl. 2009;(31):81-9.
- [25] Determinants of hearing loss in perforations of the tympanic membrane. Mehta RP1, Rosowski JJ, Voss SE, O'Neil E, Merchant SNOtolNeurotol. 2006 Feb;27(2):136-43.
- [26] Correlating the site of tympanic membrane perforation with Hearing loss. Ibekwe TS1, Nwaorgu OG, Ijaduola TG. BMC Ear Nose Throat Disord. 2009 Jan 4;9:1.
- [27] The morphology of central tympanic membrane perforations. Nepal A1, Bhandary S, Mishra SC, Singh I, Kumar P. Nepal Med Coll J. 2007 Dec;9(4):239-44.
- [28] Alexander Kessler, MD; William P. Potsic, MD; Roger R. Marsh, PhD. "Type 1 Tympanoplasty in Children." Arch Otolaryngol Head Neck Surg. 1994;120(5): 487- 490.
- [29] Textbooks 1. Scott-Brown's Otolaryngology, Seventh Edition, 2008 by Alan G.Kerr.volume 2 anatomy of ear.
- [30] Gulya AJ, Schuknecht HF Anatomy of the temporal bone with surgical implications 2nd edition pearl river (NY).
- [31] Lim DJ Functional morphology of lining membrane of the middle ear and Eustachian tube. An overview Ann OtoRhinoLaryngol 1974;83(sup11)5- 22.
- [32] Wright Anthony. In: Anatomy and ultra structure of the human ear, Scott-Brown's otolaryngology, Basic science. sixth edition. Booth JBand, Kerr AG., editors. London: Butterworth- Heinemann; 1997. pp. 1/1/7–1/1/26.
- [33] Merchant SN, Ravicz ME The American journal of otology Toynbee Memorial Lecture 1997: Middle- earmechanics.
- [34] Kirikae I. The structure and function of the middle ear. Tokyo: the University of Tokyo. Diseases of the Ear; Sixth edition 2006 Edited by Harold Ludman and Tony Wright. Surgery of the Ear – Fifth edition 2001, Edited by Michael
- [35] E. Glasscock III and George E. Shambaugh Jr Paperalla –Otolaryngology Volume II "the ear". Outcome of myringoplasty in dry and wet ear – a comparative study Gautam Dhar 1, Bijan Basak, Ganesh Chandra Gayen, Ritam Ray IOSR Journal of Dental and Medical Sciences (IOSR-JDMS) e-ISSN: 2279-0853, p- ISSN: 2279-0861. Volume 13, Issue 3 Ver. V. (Mar. 2014), PP 01-03.
- [36] R.J. Benett. Observation in ear drum repair in tympanoplasty surgery. The Journal of Laryngology and Otolaryngology, 1971;75:745- 72.
- [37] Booth JB. Myringoplasty - Factors affecting results. Final report. J LaryngolOtol 1973;87:1039-84.

- [38] Outcome of Type 1 tympanoplasty: An experience at Biratnagar eye hospital in Eastern Nepal Sanjeev Kumar Thakur, Sanjay Kumar Singh, Anwar Afaque, Nisha Ghimire 10.3126/ajms.v7i2.13357.
- [39] Factors influencing the success rate of myringoplasty Habib-Ur-Rehman, NiamatUllah, Muhammad Said, Isteraj Khan Shahabi.
- [40] Gupta N and Mishra RK. Tympanoplasty in children. Indian Journal of Otolaryngology and Head and Neck Surgery 2002; 54 (4): 271- 273.
- [41] Warrren YA, White B and Charleston SC. "Type-1- tympanoplasty; influencing factors" Laryngoscope 1984; 94: 916-919.
- [42] Tympanoplasty. SchuknechtHf, Oleksiuk SLaryngoscope. 19 59 Jun;69(6):614- 43.
- [43] Lee P, Kelly G, Mills RP. Myringoplasty : does the size of the perforation matter. Clinical otolaryngology and allied sciences.2002;27: 331- 4.
- [44] Sade J. The atelectatic ear. In: Sade J, editor. Monograms in clinical otolaryngology, secretort otitis media and its sequelae. New York: Churchill- Livingstone; 1979. pp. 64–88.
- [45] Fadl AF. Outcome of type-1 tympanoplasty. Saudi Med J 2003; 24 (1): 58-61.
- [46] Quraishi M.S. et al. Day case myringoplasty using tragal perichondrium. Clinical otolaryngology; 1995; 20;12-14.
- [47] AjmhalHussain, Jrnl of P.G Med Inst Peshawar 2004 vol 18,no-4 Pg 695-698.
- [48] Dornhoffer JL. Hearing results with cartilage tympanoplasty. Laryngoscope 1997;107(8):1094.
- [49] Ronald W Strahan, Paul Ward, Mario Acquirelli and Bruce Jafek: Tympanic membrane grafting. Analysis of material and techniques; Annals of Otology 1971; 80; 854- 8600.
- [50] Pre-Operative and Post - Operative Audiometric Evaluation Inchronic Otitis Media Dr. Girish Thakur, Dr.VinodKandakure, Dr. VaibhavLahane, Dr. Swati Mishra, Dr. ParagNarkhede. IOSR Journal of Dental and Medical Sciences (IOSR-JDMS) e-ISSN: 2279-0853, p-ISSN: 2279- 0861. Volume 14, Issue 9 Ver. V (Sep. 2015), PP 33- 35.