

Anti-inflammatory and Anti-oxidative Effects of Vitamin D Supplementation in Type 2 Diabetic Rats' Model

Mona I. Abdel Ati¹, Heba F. Pasha², Amal M. El-Gayar¹, Mamdouh M. El-Shishtawy^{1*}

¹Department of Biochemistry, Faculty of Pharmacy, Mansoura University, Mansoura, 35516, Egypt.

²Department of Biochemistry, Faculty of Medicine, Zagazig University, Zagazig, 44519, Egypt.

**Corresponding Author:*

Mamdouh M. El-Shishtawy, Ph.D.

Prof. of Biochemistry, Ex-Dean of Faculty of Pharmacy,
Mansoura University, Mansoura, 35516, Egypt
Mobile Phone: +20100-468-7974

mshisht@mans.edu.eg

e-mail addresses:

Mona I. Abdel Ati: monaia_1979@hotmail.com

Heba F. Pasha: Hfpasha@medicine.zu.edu.eg

Amal M. El-Gayar: Elgayaramal@gmail.com

Mamdouh M. El-Shishtawy: mshisht@mans.edu.eg

ABSTRACT

Objectives: The study aimed to assess the anti-inflammatory and anti-oxidative effects of vitamin D supplementation to type 2 diabetic rats.

Subjects and methods: Sixty male Albino Wistar mature rats, weighing 250±10 g were used. *Normal control group:* 10 rats kept on regular diet and received no treatment. *Normal control group+100IU vitamin D:* 5 rats kept on regular diet with 1000IU vitamin D supplementation. Diabetes was induced in the rest of animals (45 rats) by single dose of streptozotocin and fed high fat diet, then divided into 3 equal groups. *Diabetic group:* 15 diabetic rats received no treatment. *Diabetic group+100IU vitamin D:* 15 diabetic rats supplemented with 1000IU vitamin D. *Diabetic group+200IU vitamin D:* 15 diabetic rats supplemented with 2000IU vitamin D.

Results: 1000 and 2000IU vitamin D administration to diabetic rats significantly reduced the inflammatory markers TNF- α and NF κ B to near the normal control values. 1000IU vitamin D supplementation was associated with a significant improvement in oxidant markers in diabetic rats with significant decrease of MDA level (p= 0.009), and non-significant increase of GSH level, but with higher level of SOD (p= 0.028). While 2000IU dose has led to significantly elevated GSH (p= 0.003) and SOD (p= 0.003) and lowered MDA level (p= 0.003). Low and high vitamin D regimen to diabetic rats induce

improvement of the histopathological changes in the architecture of pancreas, liver and skeletal muscles.

Conclusion: Supplementations with 1000 to 2000IU vitamin D to diabetic rats significantly reduced the inflammatory markers to near normal values, improved anti-oxidant markers, and showed protective effects on the pancreas, liver and skeletal muscles.

Keywords: *Vitamin D, Type 2 Diabetes, Anti-inflammatory, Antioxidant.*

INTRODUCTION

Vitamin D, an endogenously synthesized in the body under the influence of ultraviolet light, can affect diverse aspects of human health. However, currently many biosocial factors have led to a pandemic of vitamin D deficiency (1,2). Poor vitamin D status has been associated with many human diseases, including cardiovascular disease (CVD), cancers and diabetes mellitus(3).

Type 2 diabetes mellitus (T2DM) as a multifactorial and heterogeneous metabolic disease may affect nearly every organ system in the body(4). It is reaching epidemic proportions globally as the World Health Organization estimated that T2DM was responsible for 1.6 million deaths worldwide each year, a figure making diabetes one of the world's most common causes of preventable mortality(5).

Systemic inflammation is believed to play a significant role in the pathogenesis of T2DM and the development of insulin resistance as inflammatory cytokines down-regulate insulin signaling cascades in tissues that are sensitive to insulin. This leads to the disruption of insulin sensitivity and the impairment of glucose homeostasis(6).

Vitamin D also has a role in immune regulation, as immune cells express 1-alpha-hydroxylase to regulate their own local concentration of calcitriol. Also, adequate level of serum 25-hydroxy vitamin D have been associated with increased levels of the anti-inflammatory cytokines interleukins (IL) 4 and 10, and to lower levels of the pro-inflammatory cytokines IL-1 and IL-6(7).

Oxidative stress, an imbalance between anti-oxidant defense and pro-oxidants with a shift towards the latter, has been implicated in human diseases, including diabetes and its complications(8).

The results in some experimental studies implied that vitamin D administration in diabetic mice helps to diminish the reactive oxygen species (ROS) formation by the suppression of gene expression of NADPH oxidase(9,10).

In this study we aimed to assess the anti-inflammatory and anti-oxidative effects of vitamin D supplementation in T2DM rat model.

MATERIALS AND METHODS

The current study was conducted in the Biochemistry Department, Faculty of Pharmacy, Mansoura University, Mansoura, in collaboration with the Biochemistry labs, Faculty of Medicine, Zagazig University, Zagazig 44519, Egypt. This study was approved by ethics committee of the Faculty of Pharmacy, Mansura University, Mansura 35516, Egypt, that complies with "Principles of Laboratory Animal Care" (National Institute of Health publication No. 85-23, revised 1985).

Animals:

Sixty male Albino Wistar rats supplied from the Egyptian Organization for Biological products and Vaccines (Cairo, Egypt), were used. Rats were mature, weighing 250 ± 10 g at start of experiment with normal vital signs and base line laboratory tests. Rats were kept at housed in stainless steel cages under conventional housing conditions for 10 days to acclimatize to the new environment before start of the experiments with room temperature around 25°C and light/dark cycle of 12 hours. At this stage rats were fed rodent chow diet (El-Nasr Pharmaceuticals and Chemicals Industry, Egypt) and access to drinking water was free.

Study groups:

Animals were divided into five groups: **Group 1** (Normal control group) included 10 rats that were kept on regular diet and received no treatment. **Group 2** (Normal+1000IU vitamin D group) included 5 rats that were kept on regular diet with 1000IU vitamin D supplementation for 45 days. **Group 3** (Diabetic control group) included 15 rats injected with streptozotocin (STZ) and fed high fat diet which induced diabetes mellitus, and received no treatment for 45 days. **Group 4** (Diabetic+1000IU vitamin D group) and **Group 5** (Diabetic+2000IU vitamin D group), each included 15 rats injected with STZ and fed high fat diet which induced

diabetes mellitus, and supplemented with 1000 and 2000IU vitamin D, respectively, for 45 days.

Induction of diabetes mellitus:

Experimental diabetes was induced by feeding rats with a high-fat diet for 8 weeks(11) followed by single intra-peritoneal injection of 60 mg/kg of STZ, freshly dissolved in cold 0.1 M citrate buffer, pH 4.5 after 15 min of intra-peritoneal injection of nicotinamide (110 mg/kg) prepared in normal saline(12). Control rats received standard diet and were injected with citrate buffer alone.

Administration of vitamin D:

The vitamin D-treated groups received cholecalciferol (Vidrop oral drops, Novartis Co, Switzerland) via gavage in doses of 1000IU or 2000IU for a period of 45 days(13).

Blood and tissue sampling:

Blood samples were collected at the end of the study. Animals were then decapitated and tissue samples from pancreas, liver, and skeletal muscle were collected. Tissue samples were washed in 1% phosphate buffered saline (PBS) and preserved in 10% formaldehyde for histopathological assessment.

Analysis of tissue samples:

The formalin preserved pancreatic, hepatic and skeletal muscle specimens were processed in an automated tissue processor. The processing consisted of an initial 2 step fixation and dehydration. Fixation comprising tissue immersion in 10% buffered formalin for 48 hours, followed by removal of fixative in distilled water for 30 minutes. Dehydration was then carried out by running the tissues through a graded series of alcohol. This was followed by clearing the samples in several changes of xylene. Samples were then impregnated with molten paraffin wax, then embedded and blocked out. Paraffin sections (4–5 um) were stained with hematoxylin and eosin (H&E)(14).

Biochemical analysis:

Serum tumor necrosis factor α (TNF- α) and nuclear factor-kappa-B (NF- κ B) were assessed using enzyme-linked immunosorbent assay (ELISA) kits (Shanghai Crystal

Day Biotech Co. Ltd, Shanghai, China) based on the Biotin double antibody sandwich technology (Catalogue: E0764Ra and E0290Ra, respectively).

Assessment of oxidant stress and antioxidant enzymatic activity in tissue homogenates was done by assessing the activity of superoxide dismutase (SOD), and the contents of glutathione (GSH) and malonaldehyde (MDA). ELISA kits were used (CUSABIO TECHNOLOGY LLC, Houston, USA - Catalogue: CSB-E08555r, CSB-E12144r and Cell Biolabs Inc, California, USA catalogue: STA-031).

Statistical analysis:

The collected data were analyzed by computer using Statistical Package of Social Services version 25 (SPSS Inc., Chicago, IL, USA). Data were represented in tables, Continuous Quantitative parametric variables were expressed as the mean \pm standard deviation. Analysis of variance (ANOVA) test with post hook LSD test was used for comparison between more than 2 independent groups. Pearson's correlation coefficient was used to find correlation between two numeric quantitative variables. The results were considered statistically significant when $p < 0.05$.

RESULTS

A. Histopathology Findings:

Group 1&2: Examined serial sections from pancreatic, liver and muscle tissues of Normal and Normal+1000IU vitamin D groups, showed normal tissue features [Figure 1 (A, B, C) and Figure 2 (A, B, C)], respectively.

Group 3: Serial sections from pancreatic tissue of diabetic control group revealed characteristic changes represented by moderate decrease in densities of the islets' cells, degenerative changes in the β -cells of the islets, mainly cloudy swelling and hydropic degenerations. Necrotic and apoptotic changes in a moderate number of β -cells were characteristic findings with complete or partial loss of their nuclear and/or the cytoplasmic components. Apoptotic cells were small, with shrunken deep eosinophilic cytoplasm and small nuclei. Congestion and thickening of pancreatic blood vessels and cystic dilatation and engorgement of pancreatic ducts were also encountered (Figure 3A).

Liver sections revealed congested hepatic blood vessels and sinusoids, marked cloudy swelling and hydropic degenerations of hepatocytes, beside moderate biliary

proliferation (**Figure 3B**). Skeletal muscle sections showed moderate hyaline degeneration, early necrotic changes with disappearance of the peripherally located nuclei, interstitial edema and focal cartilaginous metaplasia (**Figure 3C**).

Group 4: Examined sections from pancreas of Diabetic+1000IU vitamin D group revealed apparently normal endocrine islets cells with regard to densities, distribution, and size and cell populations. The β - and α -cells were healthy and apparently functioning in most parts of the islets, however, a few β -cells were apoptotic or degenerated. The exocrine pancreas was normal with good histo-morphologic architecture (**Figure 4A**).

Examined sections from liver of Diabetic+1000IU vitamin D group revealed apparently normal hepatic parenchyma and stroma with normal arrangement of hepatic lobules, hepatic cords, central veins, sinusoids and Von-Kupffer cells. Some sections denoted mild degenerative changes in some hepatocytes, mainly cloudy swelling (**Figure 4B**). Sections from skeletal muscles showed apparently normal histo-morphological structures with keeping features of fibers arrangement, striations, peripheral nuclear distribution and sarcolemmal membrane coating, however, some sections showed focal hyaline degeneration and interstitial edema (**Figure 4C**).

Group 5: Serial sections from pancreas of Diabetic+2000IU vitamin D group pointed out apparently normal endocrine islets cells with regard to densities, distribution, size and cell populations. The β - and α -cells were in a good morphologic condition and apparently functioning in most parts of the islets (**Figure 5A**).

Examined serial sections from liver of Diabetic+2000IU vitamin D group showed normal hepatic parenchyma and stroma with regular arrangement of hepatic lobules, hepatic cords, portal blood vessels, central veins, sinusoids and Von-Kupffer cells. Some sections showed mild congestion of portal blood vessels and mild biliary proliferation (**Figure 5B**). Serial sections from muscles of this group denoted normal histomorphological structures with keeping features of fibers arrangement, striations, peripheral nuclear distribution and sarcolemmal membrane coating, however, some sections showed focal hyaline degeneration, interstitial capillary hyperemia and edema (**Figure 5C**).

B. Inflammatory markers:

The inflammatory markers were significantly increased in the diabetic group in comparison with the control group for both TNF- α (Z score = 3.105, P = 0.002) and NF κ B (Z score = -2.847, P = 0.004). Vitamin D 1000IU administration to normal rats resulted in no significant change of TNF- α and NF κ B from control group (Z score = 0.32, P = 0.747 and Z score = -1.289, P = 0.197), respectively, while, Vitamin D administration to diabetic rats significantly reduced the inflammatory markers to near normal values at the dose of 1000IU dose (Z score = 2.959, P= 0.003 and Z score = -3.003, P = 0.003 for TNF- α and NF κ B), respectively, and also for 2000IU dose (Z score = 2.911, P = 0.004 and Z score = -2.932, P = 0.003 for TNF- α and NF κ B), respectively, with no significant difference between the 1000IU and the 2000IU treatment groups (**Table 1**).

C. Oxidative stress markers:

The diabetic group of rats had significantly different levels of oxidative stress markers with lower GSH (Z score = -2.842, p = 0.004) and SOD (Z score = -2.840, p = 0.004), and higher MDA (Z score = -2.838, p = 0.004) in comparison with normal rats. Treatment with 1000IU vitamin D to diabetic rats has led to a significant improvement in oxidant markers in comparison with the diabetic control group with higher levels of SOD (Z score = -2.193, p = 0.028) and lower level of MDA (Z score = -2.611, p = 0.009) but no significant change of GSH level (Z score = -0.736, p = 0.462). Vitamin D 2000IU has led to significantly elevated GSH (Z score = -2.928, p = 0.003) and SOD (Z score = -2.928, p = 0.003) and lowered MDA levels (Z score = -2.928, p = 0.003). Administration of vitamin D 1000IU to normal rats has no significant effect (**Table 2**).

D. Correlation study:

On comparing the effect of vitamin D supplementation and its two dose regimen on both anti-inflammatory and anti-oxidant markers among the studied diabetic rats. It was found that GSH, only diabetic rats received 2000IU vitamin D supplementation had the highest level while those taking 1000IU did not significantly improve GSH level on comparing diabetic with and without 1000IU supplementation. Regarding SOD, its level was significantly higher among rats with vitamin D supplementation at dose 2000IU followed by those received 1000IU then the highest level in diabetic

control rats; hence vitamin D at dose 2000IU is expected to improve outcome in diabetic rats regarding SOD. The same findings were reported with TNF which significantly decreased in rats received 2000IU followed by 1000IU then diabetic control rats. However, diabetic control rats, had significantly higher MDA level, on comparing them with those on vitamin D supplementation. However, dose of supplementation did not show significant difference in MDA level as at dose 1000IU or 2000IU, MDA level decreased to comparable values. Same finding was reported on studying NF κ B as vitamin D supplementation at either dose significantly decreased NF κ B as compared to control diabetic rats (**Table 3**).

There was statistically non-significant correlation between GSH level and extent of degenerative, necrotic or biliary changes among the studied rats. However, GSH level was negatively correlated with extent of cytoplasmic and inflammatory changes among the studied rats ($p < 0.05$). Also, there was statistically non-significant correlation between SOD level and extent of degenerative, inflammatory, cytoplasmic, or biliary changes among the studied rats. However, there was non-significant correlation between MDA level and extent of degenerative, inflammatory, cytoplasmic, capillary or biliary changes among the studied rats. (**Table 4**).

There was statistically significant negative correlation between TNF level and the extent of degenerative, cytoplasmic, capillary and biliary changes among the studied rats. On the other hand, there was non-significant correlation between TNF level and the extent of inflammatory changes. There was statistically non-significant correlation between NF κ B level and the extent of inflammatory, cytoplasmic, necrotic and capillary changes (**Table 4**).

There was statistically significant positive correlation between GSH and SOD and between each of TNF, NF κ B and MDA. On the other hand, there was significant negative correlation between GSH, SOD and each of MDA, TNF and NF κ B, also, there was significant negative correlation between GSH and MDA, TNF and NF κ B (**Table 5**).

DISCUSSION

Vitamin D action is extending to a wide range of skeletal and extra-skeletal functions. In this study, we investigated the anti-inflammatory and anti-oxidative roles

of vitamin D administration to T2DM rat model induced by STZ. We, also, studied the histopathological changes in pancreas, liver, and skeletal muscle tissues.

In this study we showed that vitamin D administration has a favorable effect extended to the histopathological findings with healthier pancreatic and liver tissues in the treated groups. The mechanisms behind these findings are complex and involve anti-inflammatory, anti-oxidant and anti-apoptotic effects.

Induction of T2DM was done using a single dose of STZ with high fat diet. As an alkylating agent, STZ has been extensively used for years in experimental studies for chemotherapeutic induction of diabetes mellitus. STZ can begin an autoimmune process that results in the destruction of the Langerhans islets beta cells and results in the toxicity of beta cells with emergence of clinical diabetes within 2-4 days(15,16). The effect of STZ has been controlled by simultaneous administration of nicotinamide showed that the STZ induced T2DM may be unstable and normal diet may improve the glycemic control. The concomitant use of high fat diet aids in the development of insulin resistance which adds to the pathophysiology of T2DM(17,18).

Vitamin D effects extend beyond physiological regulation of glucose/insulin axis to be cell protective against the damaging effects of STZ as proved by histopathological comparison of sections from pancreas, liver and skeletal muscle from different studied groups. Despite the extensive work covering the protective effects of vitamin D in different disease including breast cancer, nephropathies, neuropathies and atherosclerosis; the data supporting histopathological evidence that indicating protection against STZ is scarce(19–21). **Mostafa *et al.*,(22)**, showed histopathological evidence of protective effects of vitamin D on liver and cardiac muscles of rats with fat-induced metabolic syndrome.

These findings raise concerns about the mechanisms by which vitamin D mediated these effects. These histopathological findings necessitated exploring the anti-inflammatory, anti-oxidant and anti-apoptotic pathways.

Addressing the anti-inflammatory effects of vitamin D, serum levels of TNF- α and NF κ B were assessed in this study. The significant elevated markers in the diabetic group compared to the normal one were successfully reduced to near normal levels after treatment with 1000IU and 2000IU vitamin D with no significant

difference between the 1000IU and 2000IU vitamin D treatment groups. Similar effects were reported for vitamin D in patients with bacterial infections, tumors and multiple sclerosis(23–25). In a study by **Haddad Kashani et al.,(26)**, vitamin D showed similar effects on inflammatory markers of diabetic patients undergoing hemodialysis. **Dadrass et al.,(27)**, investigated the anti-inflammatory effects of vitamin D in diabetic patients with or without resistance training in men with T2DM and vitamin D deficiency. They could provide evidence on the effect of vitamin D treatment alone on IL-6 but not TNF- α .

We have showed that vitamin D has dose dependent effects on anti-oxidants and markers of oxidative stress namely SOD, GSH, and MDA. Similar findings were reported by **Mostafa et al.,(22)**, who addressed the anti-oxidant role of vitamin D in rats with high fat diet induced metabolic syndrome. In that study, vitamin D with or without metformin effectively reduced serum MDA level. In meta-analysis of 33 studies up to December 2017 addressing anti-oxidant effects of vitamin D in diabetic patients, vitamin D significantly lowers serum MDA and increases total GSH level (28).

In the present study there was a significant positive correlation between TNF- α and NF κ B. TNF- α is one of the most potent physiological inducers of the nuclear transcription factor NF κ B(29). Cytokines belonging to the TNF family induce rapid transcription of genes regulating inflammation, cell survival, proliferation and differentiation, primarily through activation of the NF κ B pathway (30).

In the present study, we found a correlation between the oxidative stress markers and the inflammatory markers. This is in accordance with the study of **Castellani et al.,(31)**, who found that increases in oxidative stress can increase the production of inflammatory cytokines and likewise, an increase in inflammatory cytokines can stimulate the production of free radicals. Oxidative stress can increase cytokine production via several different mechanisms. Oxygen derivatives, acting as second messengers, activate the transcription factors NF κ B and activating protein-1 (AP-1) leading to the transcription of genes encoding cytokines, growth factors, and extracellular matrix proteins(32). On the other hand, enhanced macrophage migration in diabetes induces the release of inflammatory and pro-fibrotic cytokines, which further stimulates ROS production(33). Therefore, oxidative stress-induced cytokine

production is likely to further increase oxidative stress levels setting up a vicious cycle.

In our study, there is statistically significant positive correlation between TNF and MDA and a significant negative correlation between GSH and TNF. These results were similar to the results of **Yoshida and Tsunawaki,(34) and Kuhad and Chopra,(35)**, who confirmed the relationship between oxidative stress and TNF- α is complex. TNF- α has been shown to increase ROS and ROS have been shown to increase TNF- α levels.

The relation between NF κ B and the oxidative markers has been proved in our study. Oxidative stress or intracellular redox status is involved in the activation of NF κ B, particularly, H₂O₂ has been found to activate NF κ B and antioxidants have been demonstrated to block NF κ B activation(**36,37**). On the other hand, **Djuric et al.,(38)**, showed that the NF κ B subunits contributed to alleviation of oxidative stress by increased expression of antioxidant enzyme manganese SOD (MnSOD). How the NF κ B system regulates the expression of apparently conflicting genes in health and disease is quite complicated and has not been fully clear yet.

The present study found a relation between the histopathological results and both oxidative and inflammatory markers. **Naik and Dixit,(39)**, found that O₂⁻ generated by mitochondria reacts with MnSOD in the mitochondrial matrix to generate H₂O₂, which can cross the mitochondrial outer membrane to access cytosolic targets. This can lead to multiple functional outcomes such as activation of redox-sensitive transcription factors (such as HIF-1 α and NF κ B). In addition, oxidative stress produced by macrophages can induce cell death through creating an imbalance in antioxidant GSH equilibrium(**40**).

In conclusion supplementations with 1000 to 2000IU vitamin D to diabetic rats significantly reduced the inflammatory markers to near normal values, and led to a significant improvement in anti-oxidant markers especially with 2000IU dose supplementation. Moreover, the study revealed histopathological evidences of protective effects of vitamin D on pancreas, liver, and skeletal muscles of diabetic rats.

Funding: The authors received no funding for this work.

Conflict of interest: The authors declare that there are no conflicts of interest.

REFERENCES

1. **Cashman, K. D. (2019).** Vitamin D deficiency: defining, prevalence, causes, and strategies of addressing. *Calcified tissue international*, 1-16.
2. **Holick, M. F. (2012).** Vitamin D: extraskelatal health. *Rheumatic Disease Clinics*, 38(1), 141-160.
3. **Reid, I. R. (2016).** What diseases are causally linked to vitamin D deficiency? *Archives of Disease in Childhood*, 101(2), 185-189.
4. **DeFronzo, R. A., Ferrannini, E., Groop, L., Henry, R. R., Herman, W. H., Holst, J. J., ... & Simonson, D. C. (2015).** Type 2 diabetes mellitus. *Nature reviews Disease primers*, 1(1), 1-22.
5. **World Health Organization. (2016).** Global report on diabetes.
6. **Rehman, K., & Akash, M. S. H. (2016).** Mechanisms of inflammatory responses and development of insulin resistance: how are they interlinked?. *Journal of biomedical science*, 23(1), 1-18.
7. **Roffe-Vazquez, D. N., Huerta-Delgado, A. S., Castillo, E. C., Villarreal-Calderón, J. R., Gonzalez-Gil, A. M., Enriquez, C., ... & Elizondo-Montemayor, L. (2019).** Correlation of vitamin D with inflammatory cytokines, atherosclerotic parameters, and lifestyle factors in the setting of heart failure: A 12-month follow-up study. *International journal of molecular sciences*, 20(22), 5811.
8. **Giacco, F., & Brownlee, M. (2010).** Oxidative stress and diabetic complications. *Circulation research*, 107(9), 1058-1070.
9. **Kono, K., Fujii, H., Nakai, K., Goto, S., Kitazawa, R., Kitazawa, S., ... & Nishi, S. (2013).** Anti-oxidative effect of vitamin D analog on incipient vascular lesion in non-obese type 2 diabetic rats. *American journal of nephrology*, 37(2), 167-174.
10. **Labudzynskyi, D. O., Zaitseva, O. V., Latyshko, N. V., Gudkova, O. O., & Veliky, M. M. (2015).** Vitamin D₃ contribution to the regulation of oxidative metabolism in the liver of diabetic mice. *The Ukrainian Biochemical Journal*, (87, № 3), 75-90.
11. **Yaw, H. P., Ton, S. H., Amanda, S., Kong, I. G. X. F., Cheng, H. S., Fernando, H. A., ... & Kadir, K. A. (2014).** Irregularities in glucose metabolism induced by stress and high-calorie diet can be attenuated by glycyrrhizic acid. *International journal of physiology, pathophysiology and pharmacology*, 6(4), 172 -184.
12. **Saini, S., & Sharma, S. (2013).** Antidiabetic effect of *Helianthus annuus* L., seeds ethanolic extract in streptozotocinnicotinamide induced type 2 diabetes mellitus. *Int J Pharm Pharm Sci*, 5(2), 382-387.
13. **Ryu, O. H., Lee, S., Yu, J., Choi, M. G., Yoo, H. J., & Mantero, F. (2014).** A prospective randomized controlled trial of the effects of vitamin D supplementation on long-term glycemic control in type 2 diabetes mellitus of Korea. *Endocrine*

Journal, 61(2), 167-176.

14. **Alturkistani, H. A., Tashkandi, F. M., & Mohammedsaleh, Z. M. (2016).** Histological stains: a literature review and case study. *Global journal of health science*, 8(3), 72-79.
15. **Akbarzadeh, A., Norouziyan, D., Mehrabi, M. R., Jamshidi, S. H., Farhangi, A., Verdi, A. A., ... & Rad, B. L. (2007).** Induction of diabetes by streptozotocin in rats. *Indian Journal of Clinical Biochemistry*, 22(2), 60-64.
16. **Gajdosik, A., Gajdosikova, A., Stefek, M., Navarova, J., & Hozova, R. (1999).** Streptozotocin-induced experimental diabetes in male Wistar rats. *General physiology and biophysics*, 18, 54-62.
17. **Guo, X. X., Wang, Y., Wang, K., Ji, B. P., & Zhou, F. (2018).** Stability of a type 2 diabetes rat model induced by high-fat diet feeding with low-dose streptozotocin injection. *Journal of Zhejiang University-Science B*, 19(7), 559-569.
18. **Gheibi, S., Kashfi, K., & Ghasemi, A. (2017).** A practical guide for induction of type-2 diabetes in rat: Incorporating a high-fat diet and streptozotocin. *Biomedicine & Pharmacotherapy*, 95, 605-613.
19. **Fu, W. J., Lei, T., Yin, Z., Pan, J. H., Chai, Y. S., Xu, X. Y., ... & Xu, R. H. (2017).** Anti-atherosclerosis and cardio-protective effects of the Angong Niu Huang Pill on a high fat and vitamin D3 induced rodent model of atherosclerosis. *Journal of ethnopharmacology*, 195, 118-126.
20. **Prabhakar, S. S., Kam, K., Kottapalli, R., & Yego, C. (2016).** RNA Next Gen Sequencing of Kidneys from Diabetic Rats Provides Insights Into Reno-protective Effects Of Vitamin D Receptor Activation. *The FASEB Journal*, 30(1-supplement), 771-773.
21. **Sreelatha, A., Sam, N. V., & Raghavan, R. P. (2018).** Protective Effects of Vitamin D-A Review Article. *Journal of Young Pharmacists*, 10(4), 388-391.
22. **Mostafa, D. K., Nasra, R. A., Zahran, N., & Ghoneim, M. T. (2016).** Pleiotropic protective effects of Vitamin D against high fat diet-induced metabolic syndrome in rats: One for all. *European journal of pharmacology*, 792, 38-47.
23. **Liu, W., Zhang, L., Xu, H. J., Li, Y., Hu, C. M., Yang, J. Y., & Sun, M. Y. (2018).** The anti-inflammatory effects of vitamin D in tumorigenesis. *International journal of molecular sciences*, 19(9), 2736.
24. **Hashemi, R., Hosseini-Asl, S. S., Arefhosseini, S. R., & Morshedi, M. (2020).** The impact of vitamin D3 intake on inflammatory markers in multiple sclerosis patients and their first-degree relatives. *PloS one*, 15(4), e0231145.
25. **Hoe, E., Nathanielsz, J., Toh, Z. Q., Spry, L., Marimla, R., Balloch, A., ... & Licciardi, P. V. (2016).** Anti-inflammatory effects of vitamin D on human immune cells in the context of bacterial infection. *Nutrients*, 8(12), 806.
26. **Haddad Kashani, H., Seyed Hosseini, E., Nikzad, H., Soleimani, A., Soleimani, M., Tamadon, M. R., ... & Asemi, Z. (2018).** The effects of vitamin D supplementation on signaling pathway of inflammation and oxidative stress in diabetic hemodialysis: a randomized, double-blind, placebo-controlled trial. *Frontiers in pharmacology*, 9, 50.
27. **Dadrass, A., Salamat, K. M., Hamidi, K., & Azizbeigi, K. (2019).** Anti-

- inflammatory effects of vitamin D and resistance training in men with type 2 diabetes mellitus and vitamin D deficiency: a randomized, double-blinded, placebo-controlled clinical trial. *Journal of Diabetes & Metabolic Disorders*, 18(2), 323-331.
28. **Mansournia, M. A., Ostadmohammadi, V., Doosti-Irani, A., Ghayour-Mobarhan, M., Ferns, G., Akbari, H., ... & Asemi, Z. (2018).** The effects of vitamin D supplementation on biomarkers of inflammation and oxidative stress in diabetic patients: a systematic review and meta-analysis of randomized controlled trials. *Hormone and Metabolic Research*, 50(06), 429-440.
 29. **Tak, P. P., & Firestein, G. S. (2001).** NF- κ B: a key role in inflammatory diseases. *The Journal of clinical investigation*, 107(1), 7-11.
 30. **Gilmore, T. D., & Wolenski, F. S. (2012).** NF- κ B: where did it come from and why?. *Immunological reviews*, 246(1), 14-35.
 31. **Castellani, P., Balza, E., & Rubartelli, A. (2014).** Inflammation, DAMPs, tumor development, and progression: a vicious circle orchestrated by redox signaling. *Antioxidants & redox signaling*, 20(7), 1086-1097.
 32. **Nath, K. A., Grande, J., Croatt, A., Haugen, J., Kim, Y., & Rosenberg, M. E. (1998).** Redox regulation of renal DNA synthesis, transforming growth factor- β 1 and collagen gene expression. *Kidney international*, 53(2), 367-381.
 33. **DeRubertis, F. R., Craven, P. A., & Melhem, M. F. (2007).** Acceleration of diabetic renal injury in the superoxide dismutase knockout mouse: effects of tempol. *Metabolism*, 56(9), 1256-1264.
 34. **Yoshida, L. S., & Tsunawaki, S. (2008).** Expression of NADPH oxidases and enhanced H₂O₂-generating activity in human coronary artery endothelial cells upon induction with tumor necrosis factor- α . *International immunopharmacology*, 8(10), 1377-1385.
 35. **Kuhad, A., & Chopra, K. (2009).** Attenuation of diabetic nephropathy by tocotrienol: involvement of NF κ B signaling pathway. *Life sciences*, 84(9-10), 296-301.
 36. **Anderson, M. T., Staal, F. J., Gitler, C., & Herzenberg, L. A. (1994).** Separation of oxidant-initiated and redox-regulated steps in the NF-kappa B signal transduction pathway. *Proceedings of the National Academy of Sciences*, 91(24), 11527-11531.
 37. **Flohé, L., Brigelius-Flohé, R., Saliou, C., Traber, M. G., & Packer, L. (1997).** Redox regulation of NF-kappa B activation. *Free Radical Biology and Medicine*, 22(6), 1115-1126.
 38. **Djuric, Z., Kashif, M., Fleming, T., Muhammad, S., Piel, D., von Bauer, R., ... & Nawroth, P. P. (2012).** Targeting activation of specific NF- κ B subunits prevents stress-dependent atherothrombotic gene expression. *Molecular medicine*, 18(10), 1375-1386.
 39. **Naik, E., & Dixit, V. M. (2011).** Mitochondrial reactive oxygen species drive proinflammatory cytokine production. *Journal of Experimental Medicine*, 208(3), 417-420.
 40. **Circu, M. L., & Aw, T. Y. (2010).** Reactive oxygen species, cellular redox systems, and apoptosis. *Free Radical Biology and Medicine*, 48(6), 749-762.

Table 1: Inflammatory markers results in study groups

Marker	Normal control	Normal + 1000IU Vit. D	Diabetic control	Diabetic + 1000IU Vit. D	Diabetic + 2000IU Vit. D
TNF- α (pg/mL)	20.90 \pm 0.108	19.80 \pm 0.243	32.10 \pm 0.140*	26.57 \pm 0.11*†	25.50 \pm 0.2*†
NF κ B (pg/mL)	55.17 \pm 3.90	65.68 \pm 4.77	129.14 \pm 14.30*	58.90 \pm 3.60*†	64.67 \pm 3.20*†

Values are represented as: mean \pm SD.

NF κ B: nuclear factor kappa B; TNF- α : tumor necrosis factor-alpha.

ANOVA test with post hook LSD test

* P < 0.05 compared to the normal control.

† P < 0.05 compared to the diabetic control.

Table 2: Markers of oxidative stress in study groups

Marker	Normal control	Normal + 1000IU Vit. D	Diabetic control	Diabetic + 1000IU Vit. D	Diabetic + 2000IU Vit. D
GSH (ng/mL)	8.46 \pm 0.47	8.86 \pm 0.44	7.18 \pm 0.40*	7.36 \pm 0.36*	8.23 \pm 0.33*†‡
SOD (U/mL)	21.77 \pm 1.62	21 \pm 0.54	17.68 \pm 0.89*	19.76 \pm 1.34*†	20.75 \pm 0.91*†
MDA (nmol/mL)	52.62 \pm 1.55	51.96 \pm 1.06	127.60 \pm 5.02*	87.56 \pm 9.33*†	87.50 \pm 14.53*†

Values are represented as: mean \pm SD.

GSH: glutathione; MDA: malondialdehyde; SOD: superoxide dismutase.

Test: ANOVA test with post hook LSD test

* P < 0.05 compared to the normal control.

‡ P < 0.05 compared to the diabetic + 1000IU vitamin D.

† P < 0.05 compared to the diabetic control.

Table (3) Relation between vitamin D supplementation and both inflammatory and antioxidant markers among the studied diabetic rats:

Groups	Diabetic control	Diabetic + 1000IU Vit. D	Diabetic + 2000IU Vit. D	P
Markers				
GSH (ng/mL)	7.18 \pm 0.367	7.36 \pm 0.338	8.244 \pm 0.322	<0.001**
LSD	P ₁ <0.158	P ₂ <0.001**	P ₃ <0.001**	
SOD (U/mL)	17.68 \pm 0.89	19.76 \pm 1.34	20.75 \pm 0.91	<0.001**
LSD	P ₁ <0.001**	P ₂ <0.001**	P ₃ <0.006*	
MDA (nmol/mL)	127.60 \pm 5.02	87.56 \pm 9.33	87.50 \pm 14.53	<0.001**
LSD	P ₁ <0.001**	P ₂ <0.001**	P ₃ 0.940	
GSH (ng/mL)	32.10 \pm 0.140	26.57 \pm 0.11	25.50 \pm 0.2	<0.001**

LSD	P₁ 0.158	P₂ <0.001**	P₃ <0.001**	
NFκB (pg/mL)	129.14 ± 14.30	58.90 ± 3.60	64.67 ± 3.20	<0.001**
LSD	P₁ <0.001**	P₂ <0.001**	P ₃ 0.711	

Values are represented as: mean ± SD. LSD Fisher least significance test; P₁ the difference between groups I and II; P₂ the difference between groups II and III; P₃ the difference between groups I and III. **P≤0.001 is statistically highly significant; *P<0.05 is statistically significant.

Table (4): Correlation between extent of histopathological examination and anti-inflammatory and antioxidant markers among the studied rats

	Degenerative changes		Cytoplasmic changes		Necrotic changes		Inflammatory changes		Biliary changes		Capillary changes	
	r	p	r	p	r	p	r	p	r	p	r	p
GSH	-0.188	0.15	-0.544	<0.001**	0.178	0.173	-0.443	<0.001**	0.006	0.993	-0.425	0.001**
SOD	0.092	0.484	0.148	0.258	0.266	0.04*	-0.101	0.443	0.109	0.407	-0.082	0.531
MDA	0.004	0.976	0.218	0.094	-0.166	0.204	0.073	0.745	-0.035	0.793	0.04	0.76
TNF	-0.514	<0.001**	-0.173	0.185	-0.477	<0.001**	-0.548	<0.001**	-0.488	<0.001**	-0.602	<0.001**
NFκB	-0.329	0.01*	0.163	0.214	-0.25	0.054	-0.11	0.404	-0.262	0.04*	-0.088	0.504

r Spearman rank correlation coefficient; *p<0.05 is statistically significant; **p<0.001 is statistically highly significant.

Table (5) Correlation between anti-inflammatory and anti-oxidant markers among the studied rats

	GSH		SOD		MDA		TNF		NFκB	
	r	p	r	p	r	p	r	p	r	p
GSH	---		0.663	<0.001**	-0.728	<0.001**	-0.242	0.063	-0.57	<0.001**
SOD	0.663	<0.001**	---		-0.726	<0.001**	-0.302	0.019*	-0.663	<0.001**
MDA	-0.728	<0.001**	-0.762	<0.001**	---		0.548	<0.001**	0.749	<0.001**
TNF	-0.242	0.063	-0.302	0.019*	0.548	<0.001**	---		0.625	<0.001**
NFκB	-0.57	<0.001**	-0.663	<0.001**	0.749	<0.001**	0.625	<0.001**	---	

r Pearson correlation coefficient; **p≤0.001 is statistically highly significant.

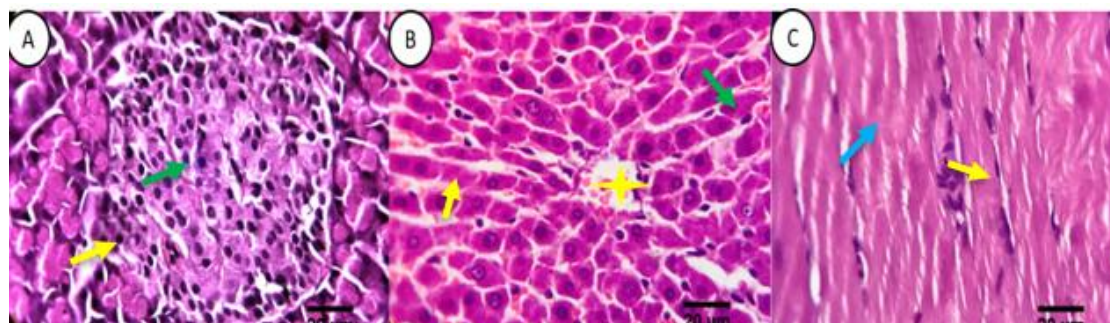


Figure 1. Hematoxylin and eosin-stained sections of Normal control group:

(A) Pancreatic tissue showing apparently normal beta cells (green arrows) and alpha cells (yellow arrows). (B) Liver tissue shows normal arrangement of hepatic lobules, hepatic cords

(yellow arrows), central veins (yellow stars), sinusoids and Von-Kuffer cells (green arrow). (C) Skeletal muscles, showing normal muscle fibers with apparent longitudinal fibers arrangement, striations (blue arrows) and normal peripheral multi-nuclear distribution within a sarcolemmel membrane coating (yellow arrows). Scale bars 20 um.

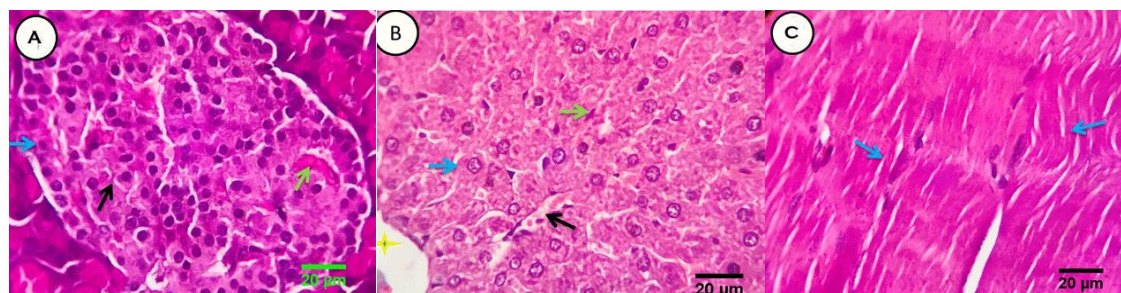


Figure 2. Hematoxylin and eosin-stained sections of Normal+1000IU vitamin D treated group.

(A) Pancreatic tissue showing normal endocrine islets cell populations, the Beta and alpha cells appears healthy and apparently functioning in most parts of the islets (blue and black arrows, respectively). Intervening capillary network is seen among islets cells (green arrow). (B) Liver, showing normal arrangement of hepatic lobules, hepatic cords (blue arrows), central veins (yellow stars), sinusoids (black arrow) and Von-Kupffer cells (green arrow). (C) Skeletal muscles, showing normal muscle fibers with apparent longitudinal and oblique fibers arrangement, striations and normal peripheral multi-nuclear distribution within a sarcolemmel membrane (blue arrows). Scale bars 20 um.

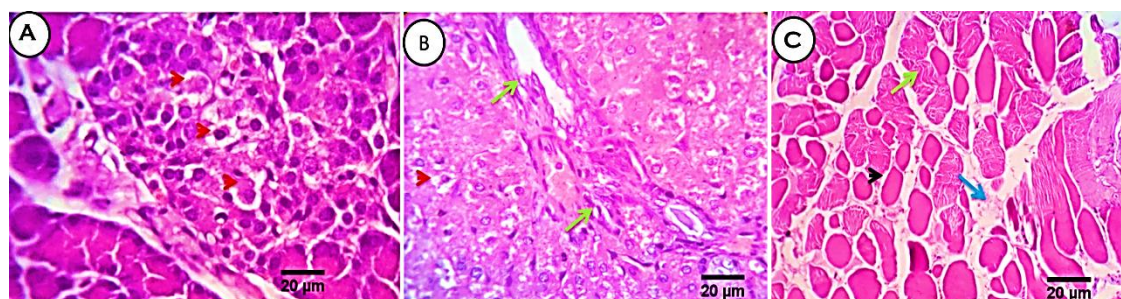


Figure 3: Hematoxylin and eosin-stained sections of diabetic control group.

(A) Pancreatic tissue showing degenerative changes in the β -cells of the islets, mainly cloudy swelling and hydropic degenerations (red arrow heads). (B) Rats' liver tissue showing moderate biliary proliferation (green arrow). (C) Rats' muscle tissue showing normal arrangement of muscle fibers (green arrows), focal hyaline degeneration with early necrotic changes and disappearance of the peripherally located nuclei (black arrow heads), interstitial edema (blue arrow) and focal cartilaginous metaplasia (yellow star). Scale bars 20 um.

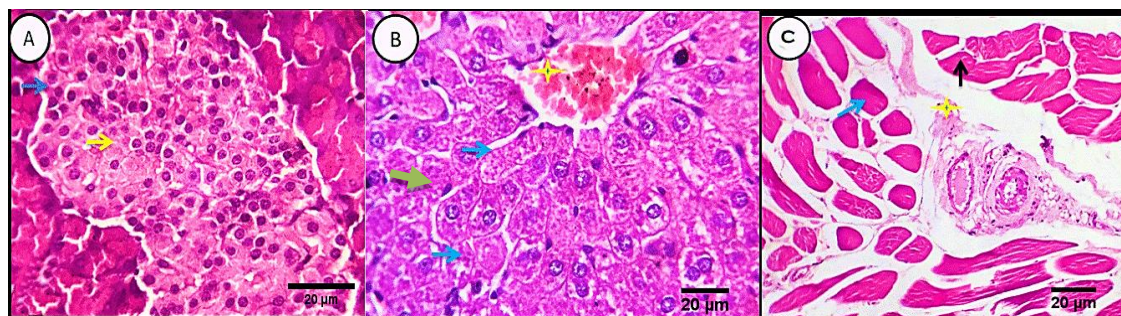


Figure 4: Hematoxylin and eosin stained sections of diabetic+1000IU vitamin D group. (A) Pancreatic tissue showing apparently normal endocrine islets cells with regard to densities, distribution, size and cell populations (yellow stars). The Beta and alpha cells were healthy and apparently functioning in most parts of the islets (yellow and blue arrows, respectively). (B) Liver tissue showing normal arrangement of hepatic lobules, hepatic cords (blue arrow), central veins (yellow stars), sinusoids and Von-Kupffer cells (green arrow). (C) Muscle tissue keeping features of fibers arrangement, striations, peripheral nuclear distribution and sarcolemmal membrane coating (black arrows). Focal hyaline degeneration and interstitial edema are seen (blue arrows and yellow stars, respectively). Scale bars 20 um.

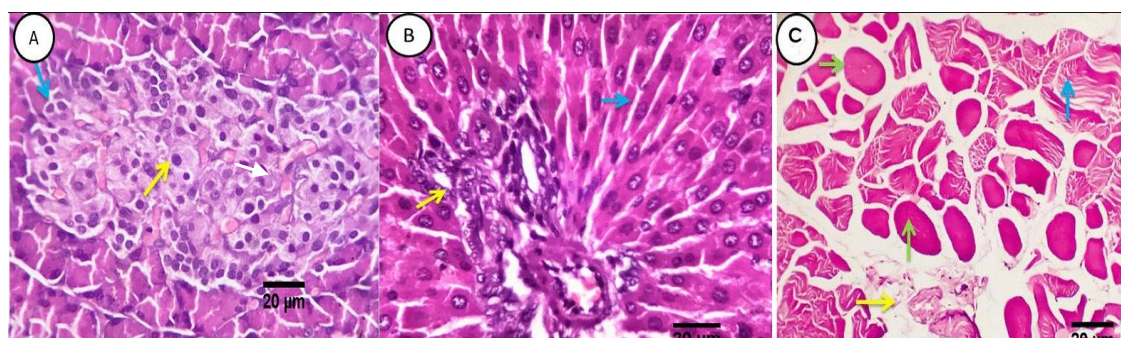


Figure 5: Hematoxylin and eosin stained sections of diabetic+2000IU vitamin D group. (A) Pancreatic tissue showing apparently normal beta and alpha cells (yellow and blue arrows, respectively). Intervening capillary network appears normally distributed among the islet cells (white arrows). (B) Normal hepatic parenchyma and stroma with regular arrangement of hepatic lobules, hepatic cords (blue arrows), central veins, sinusoids and Von-Kupffer cells (black arrow). Mild congestion of portal blood vessels (yellow star) and mild biliary proliferation (yellow arrow). (C) Skeletal muscle showing normal histomorphological structures with keeping features of fibers arrangement, striations, peripheral nuclear distribution and sarcolemmal membrane coating (blue arrow). Focal hyaline degeneration (green arrows), interstitial capillary hyperemia (yellow star) and edema (yellow arrow). Scale bars 20 um.