

New Methods of Correction of Inflammatory Diseases of the Genitalia (Clinical and Experimental Study)

¹Feruza Shopulatovna ORIPOVA, ¹Gulchehra Akmalovna IKHTIYAROVA,

²Kadir SHUKURLAEV, ¹Mukhayo Tukhtasinovna KHAMDAMOVA

¹Bukhara State Medical Institute named after Abu Ali ibn Sino

Department of Obstetrics and Gynecology,

²Tashkent Medical Academy Urgench branch Department of Pathological Physiology

e-mail: oripova.feruza@bk.ru, coll. (94)544-21-12

ABSTRACT

Experimental studies of new vaginal suppositories "Kurkuvir" were conducted in the conditions of experimental vaginitis caused by silver nitric acid. It was found that against the background of experimental pathology, the vaginal suppositories "Kurkuvir" showed anti-inflammatory and reparative effects and had a significant advantage in comparison with the suppositories "Pavisin" and were not inferior in effect, which is confirmed by the indicators of the state of the vaginal mucosa, symptomatic, cytological and ph-metry of the vagina.

Key words: turmeric oil; Pavisin; vaginal suppositories, experimental vaginitis.

INTRODUCTION

Infectious and inflammatory diseases of the female genital organs occupy a special place in the structure of general morbidity, since they can have a direct effect on reproductive function. Nonspecific vulvovaginitis (NV) is one of the most common and recurrent vaginal diseases in women of any age [1, 2, 23]. According to modern data, almost every fifth to sixth patient in gynecological practice suffers from HB. After bacterial vaginosis, vulvovaginal mycosis and trichomoniasis, NV stably ranks 4th in the structure of all infectious and inflammatory diseases of the lower part of the female genital organs [3,13,22]. In recent years, more and more attention has been paid to finding the best ways to solve the problems associated with their treatment. The relevance of this direction is determined by the tendency to generalization and chronicity of inflammatory processes, the development of serious pathophysiological and pathomorphological changes in the affected tissues and organs, the involvement of the immune, nervous, endocrine, reproductive and other body systems in the pathological process [4,14,21]. The local route of drug administration makes it possible to reduce the pharmacological load on the woman's body, its advantages are simplicity and ease of use, the absence of absolute contraindications (except for individual intolerance to the drug components), as well as the possibility of using it in patients with extragenital pathology.

Purpose. Determination of pharmacological (anti-inflammatory and reparative) activity of new vaginal suppositories "Curcuvir" on the model of experimental vaginitis caused by a chemical agent.

MATERIALS AND METHODS

Experimental studies were carried out on female rabbits weighing 2800–3000 g. Care for them (including euthanasia) during the experiment was carried out according to the available documents, which regulate the organization of work with the use of experimental animals. The

principles of the "European Convention for the Protection of Vertebrate Animals used for Experimental and Other Scientific Purposes" (Strasbourg, 1985) [10,11,20], adopted by the I National Congress on Bioethics (Kiev, 2000), which is consistent with the provisions of the European Convention on the Protection of vertebrates used for experimental and other scientific purposes. After completion of the experiment, the rabbits were removed from the experiment in accordance with the ethical principles of animal experiments.

The object of the study were vaginal suppositories "Curcuvir" based on turmeric oil in a copper chelate complex, developed by the staff of the drug technology laboratory "Med Standard LLC" under the guidance of Professor A. N. Yunuskhodzhaev. Suppositories "Pavisin" ("Mu Lin Sen", Kyrgyzstan) were selected as comparison drugs. The pathology was reproduced by introducing a tampon with a 10% solution of silver nitrate into the vagina of an experimental animal and its exposure for 5 min [9,17,18,19]. From the next day after modeling the pathology, treatment was started with the investigated suppositories "Curcuvir", comparison drugs, and placebo once a day. The duration of this model is 7 days. After modulation of the pathology, the animals were divided into 2 groups: 1st main group with nonspecific vaginitis, treated with the drug "Curcuvir" within 7 days; Group 2, compared with HB, treated with the drug "Pavisin" (turmeric oil and borneol) by candlelight a day for 7 days. The duration of this model was 7 days. Doses of the studied suppositories and comparison drugs were administered in terms of the coefficients of species resistance that are commonly used in experimental pharmacology by Yu. R. Rybolovlev [7,14,16].

In order to determine in more detail the severity of the inflammatory process, as well as the therapeutic effect of the reference drug and the test agent, on the 1st and 7th days of the experiment, the following parameters were assessed: pH-metrics of the vagina, semi-quantitative assessment of the area of the lesion of the vaginal mucosa in points, assessment of microbiocinosis using the modern express test Femoflor -16, cytological and morphological data.

The results were statistically processed using the Statistica 6.0 software.

RESULTS AND DISCUSSION.

Since vaginitis in women is always aggravated by a bacterial infection [6,13,15], it is very problematic to study the anti-inflammatory and reparative properties of drugs against the background of this pathology. Therefore, we simulated vaginitis using silver nitrate, which causes vaginal lesions not burdened by infection, in order to study the reparative and anti-inflammatory properties of the studied drugs. [13,14]. On the state of the vaginal mucosa (VTS), a semi-quantitative assessment was made of the sum of the main signs of inflammation in points according to three parameters: edema, hyperemia, hemorrhage. [8,11,12].

The analysis of the study results indicates that a one-time local effect of silver nitrate on the RWS of rabbits leads to the development of vaginitis within 7 days in comparison with intact animals. This is indicated by the indicators on the 7th day of the experiment, which characterize the state of SOS. (table 1).

Table 1. Indicators of the state of IDS in rabbits on the model of "chemical" vaginitis on the 1st day (n = 10)

Inspection in mirrors		
1st day	1-group treated with "Curcuvir" Turmeric oil 50mg, copper chelate 17.5mg, econazole nitrate 0.2ml (antifungal). Excipients: polyethylene glycol 1500, polysorbate 80.	Group 2 treated with "Pavisin" Turmeric oil - 82 mg, borneol - 75 mg. Excipients: ethanol, macrogol 400, macrogol 4000, polyoxyl (40) stearate, laurocapram.
	3-score	3-score

Notes: * - points were assigned depending on the severity of the signs: 0 points - the sign is absent; 1 point - the sign is expressed slightly; 2 points - the sign is expressed moderately; 3 points - the sign is pronounced

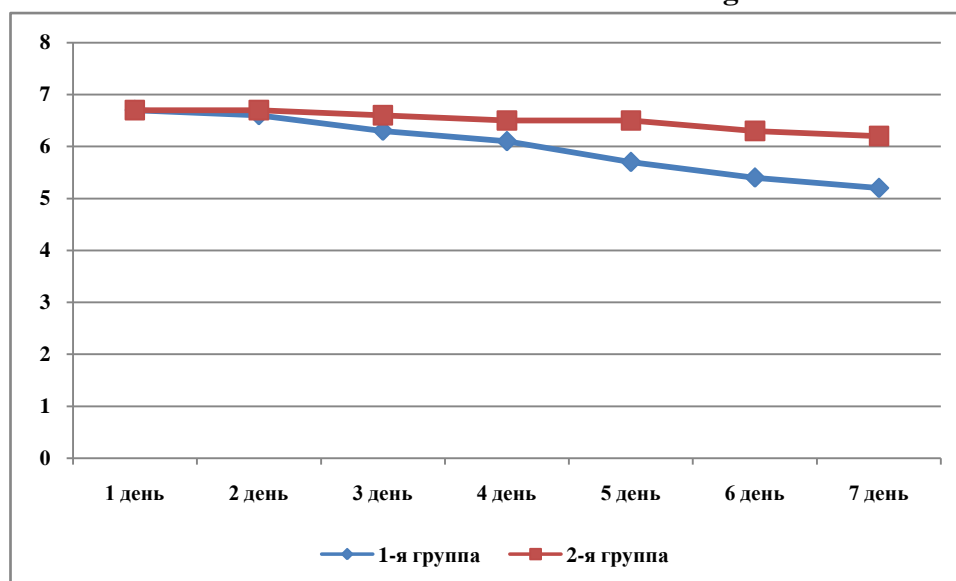
The suppression of the local inflammatory process under the influence of the vaginal suppositories "Curcuvir" and reference drugs is also reflected in a significant decrease in the intensity of edema, hyperemia and the amount of hemorrhage in relation to the control pathology group; Vaginal suppositories "Kurkuvir" reduced this indicator by 2.2 times, and suppositories "Pavisin" - by 2.2 and 1.56 times, respectively.

Table 2. Influence of the studied suppositories on the indicators of the state of SOM in rabbits on the model of "chemical" vaginitis on the 7th day (n = 10)

Inspection in mirrors		
7th day	1-group treated with "Curcuvir" Turmeric oil 50mg, copper chelate 17.5mg, econazole nitrate 0.2ml (antifungal). Excipients: polyethylene glycol 1500, polysorbate 80.	Group 2 treated with "Pavisin" Turmeric oil - 82 mg, borneol - 75 mg. Excipients: ethanol, macrogol 400, macrogol 4000, polyoxyl (40) stearate, laurocapram.
	0-score	2-score

Notes: * -Indicator in female rabbits after treatment with the studied suppositories against the background of "chemical" vaginitis on the 7th day of the model pathology (n = 10); * - the deviation of the indicator is reliable relative to the control pathology, $p \leq 0.05$.

The analysis of the dynamics of changes in the pH of the hut of experimental animals showed that in the 1st group this indicator statistically significantly decreases, making 0.05 ± 0.05 on the 7th day of the experiment. In rabbits of the 2nd, a change in the pH of the humid was revealed; by the end of the experiment, this indicator was 6.12 ± 0.05 and 6.12 ± 0.06 on the 7th day of the experiment.

Fig. 1. Dynamics of changes in the pH of the hut in animals with nonspecific vaginitis in the course of treatment with various drugs.

The analysis of oils from different parts of the lower sex organs showed its high values in all the examined groups on the 1st day of the performance of the model. The treatment of this pathology developed by us by the drug showed a significant decrease in 2.86 times in Vagina, 2.59 times in Cervix and 2.07 times. Pharmacotherapy of experimental HB with thymoquinone also turned out to be effective, as we observed a reasonable decrease in the content of Vtraix at 1.5 and 1.85 in 1.85 The treatment of this pathology by the parasite showed a significant decrease of 2.43 times in Vagina, 2.18 times in Cervix and 2.06 times in Uretra. At the same time, in the 4th unchecked group, we observed an increase in the number of flat epithelium in all parts of the lower genital organs.

Table 3. The content of the flat epithelium in various parts of the genital organs of rabbits with nonspecific vaginitis treated with various drugs

Localization and terms (days)	Experimental groups	
	1-я, n=10	2-я, n=10
Vagina		
1-st day	16,90±0,43 ^{***}	16,50±0,50 ^{***}
7-th day	5,90±0,31 [*]	8,90±0,43 ^{**}
Cervix		
1-st day	15,30±1,04 ^{***}	13,40±1,32 ^{***}
7-th day	5,90±0,31 [*]	8,90±0,43 ^{**}
Uretra		
1-st day	12,2±0,93 ^{***}	12,30±1,16 ^{***}
7-th day	5,90±0,31 [*]	8,90±0,43 ^{**}

Note: * - differences in relation to the given control group are significant (* - $P < 0.05$, ** - $P < 0.01$, *** - $P < 0.001$).

It was also of interest to analyze the content of leukocytes during experimental vaginitis in the course of treatment with various drugs. Conducted studies have shown its high values in all investigated sections of the lower genital tract on the 1st day of experimentation (Table 4.). Pharmacotherapy with a drug developed by us led to a decrease in the high values of leukocytes in the oils taken from Vagina, at 2.4 times over a period of about 7 days. In Cervix, this reduction was 2.31 times, in Uretra - 1.78 times. Pharmacotherapy of experimental HB treatment with Pavisin showed a significant decrease of 2.34 times in Vagina, 2.23 times in Cervix and 1.91 times in Uretra.

Table 4. The content of leukocytes in various parts of the genital organs of rabbits with nonspecific vaginitis, treated with various drugs

Localization and terms (days)	Experimental groups	
	1-я, n=10	2-я, n=10
Vagina		
1-st day	22,3±0,68 ^{***}	21,8±0,57 ^{***}
7-th day	9,30±0,33 ^{**}	12,30±0,37 ^{***}
Cervix		
1-st day	21,50±0,64 ^{***}	19,20±0,51 ^{***}
7-th day	9,30±0,33 ^{**}	12,30±0,37 ^{***}
Uretra		
1-st day	16,60±0,52 ^{***}	16,40±1,17 ^{***}
7-th day	9,30±0,33 ^{**}	12,30±0,37 ^{***}

Note: * - differences in relation to the given control group are significant (** - $P < 0.01$, *** - $P < 0.001$).

It should be noted that treatment of animals against the background of model pathology with suppositories "Kurkuvir" led to suppression of the inflammatory process, as evidenced by a decrease in indicators: significantly, compared with the control pathology group, the ph-metry decreases close to normal, the number of cytological indicators is also affected vaginal mucosa at the level of intact control. The reference drug - suppositories "Pavisin" - similarly influenced the higher indicated indicators, but due to the severity of the therapeutic effect it was somewhat inferior to the suppositories "Kurkuvir".

Thus, vaginal suppositories "Curcuvir" at a dose of 50 mg have anti-inflammatory and reparative effects on OTS in a model of experimental vaginitis caused by a chemical agent, which is confirmed by the indicators of the state of OTS, vaginal ph-metry and cylogical indicators.

CONCLUSION

1. Vaginal suppositories "Curcuvir" under conditions of experimental vaginitis caused by silver nitrate showed anti-inflammatory and reparative effects.
2. In comparison with reference drugs, suppositories "Kurkuvir" had a significant advantage in comparison with suppositories "Pavisin" and were not inferior in effect to it.
3. New vaginal suppositories "Curcuvir" can be recommended for study as a drug for the treatment of HB.

ACKNOWLEDGEMENTS

We are grateful to the staff members of Bukhara State Medical Institute named after Abu Ali ibn Sino and Tashkent Medical Academy Urgench branch for the cooperation and support in our research.

CONFLICT OF INTEREST

The authors declare that they have no competing interests.

FUNDING

No funding sources to declare.

REFERENCES

1. Ikhtiyarova G.A., Oripova F.SH. Reproduktivnaya reabilitatsiya zhenshchin s khronicheskimi vospalitel'nymi zabolovaniyami polovykh organov. // Spets vypusk zhurnala biomeditsiny i praktiki. Tashkent-2020.S-56
2. Ikhtiyarova G.A., Oripova F.SH., Saidov S.A., Mavlonov A.A. Bakterial'nyy vaginit: problemy, perspektivy diagnostiki i lecheniya // Doktor akhborotnomasi. – Samarkand, 2020. - № 1. - S. 131
3. Kira Ye. F., Gaytukiyeva R. A. Biotsenoz i funktsional'naya aktivnost' epiteliya vlagalishcha pri mestnom lechenii aerobnogo vaginita polizhinaksom i terzhinanom // Zhurnal akusherstva i zhenskikh bolezney. — 2019. — T. LIX, vyp. 5. — S. 127–135.
4. Oripova F.SH, Ikhtiyarova G.A. Molekulyarnyye mekhanizmy deystviya antioksidantov na lipidnyy komponent kletok mozga pri eksperimental'noy gipoksii ploda. Infektsiya, immunologiya i farmakologiya. // Nauchno-prakticheskiy zhurnal-2019. № 5 \ S.-280
5. Oripova F.SH., Ikhtiyarova G.A. Morfologicheskaya kartina effektivnosti novykh sredstv lecheniya nespetsificheskogo vaginita. // Tibbiyotda yangi kun, Bukhoro-2020. № 2\1 30\1.– S.215-219.
6. Oripova F.SH., Ikhtiyarova G.A. Saidov S.A. Razrabotka novykh sredstv lecheniye nespetsificheskogo vaginita s uchetom patogeneticheskikh mekhanizma razvitiya. // Tibbiyotda yangi kun, Bukhoro.- 2020. №2.30(2).– S.220-225.
7. Rybolovlev YU. R. Dozirovaniye veshchestv dlya mlekopitayushchikh po konstantam biologicheskoy aktivnosti // Doklady AN SNG. — 2009. — T. 247, № 6. — S. 1513–1516.
8. Sposib modelyuvannya yeksperimental'nogo vaginitu u shchuriv : inform. list / K. O. Stepanova [i dr.]. — K. : Tsentri «Ukrmedpatentinform» MOZ Ukraïni, 2011. — № 44. — S 2-40.
9. Ikhtiyarova G.A. Prenatal Rupture Of Amnion Membranes as a risk of development of obstetrics pathologies / G.A. Ikhtiyarova, I.I. Tosheva, M.J. Aslonova, N.K. Dustova // European Journal of Molecular & Clinical Medicine. - 2020. - ISSN 2515-8260. - Volume 07, Issue 07. - P. 530-535.
10. Ikhtiyarova G.A. Causes of fetal loss syndrome at different gestation times / G.A. Ikhtiyarova, I.I. Tosheva, N.S. Nasrullayeva // Asian Journal of Research. - 2017. - № 3(3). - P. 32-39.
11. Ixtiyarova G.A. Predgravidary preparation of women with a high group of perinatal risks and inflammatory diseases of the genitals / G.A. Ixtiyarova, N.G. Ashurova, I.I. Tosheva // European Journal of Research - Vienna, Austria. - 2017. - №9-10. – P.53-62.
12. Graziottin A. Recurrent cystitis and vaginitis : role of biofilms and persister cells. From pathophysiology to new therapeutic strategies / A. Graziottin, P. P. Zanello, G. D'Errico //

- Minerva Ginecol. — 2017. — Vol. 66 (5). — P. 497–512.
13. Mavlyanova N.N. The State of the Cytokine Status in Pregnant Women with Fetal Growth Retardation/N.N. Mavlyanova, G.A. Ixtiyarova, I.I. Tosheva, M.J. Aslonova, N.S. Narzullaeva//Journal of Medical-Clinical Research&Reviews-2020.-№4(6).-p.18-20
 14. European convention for the protection of vertebrate animals used for experimental and other scientific purpose : Council of Europe 18.03.2017.
 15. Oripova F.Sh., Ikhtiyarova G.A. & Davlatov S.S. (2021). Pathomorphological characteristics of the vaginal mucosa in experimental nonspecific vaginitis and various methods of treatment. International Journal of Pharmaceutical Research, 13(1), 761-765. doi: 10.31838/ijpr/2021.
 16. Qurbonova N.I., Khabibova N.N. & Ikhtiyarova G. A. (2020). Hygienic condition of the oral cavity and the level of hygienic knowledge of silk motor workers. European Journal of Molecular and Clinical Medicine, 7(3), 3027-3033. Retrieved from www.scopus.com
 17. Sarkisova L.V., Yuldasheva R.U., Kurbanova Z.Sh. & Aslonova M.J. (2020). The Role of Indicators of Ferrokinetic and Endogenous Erythropoietin in Anemia of Pregnant Women. American Journal of Medicine and Medical Sciences, 10(4), 262-265
 18. Zavkibekova T.K., Ikhtiyarova G.A., & Aslonova M.J. (2021) Differential markers for the diagnosis of recurrent benign ovarian tumors in women of reproductive and premenopausal age. International Journal of Pharmaceutical Research, 13, 2896-2901
 19. Tosheva I.I. Introduction of childbirth in women with the discharge of amniotic fluid with intrauterine fetal death/I.I. Tosheva, G.A. Ikhtiyarova, M.J. Aslanova//Journal of Problems and solutions of advanced scientific research.-2019.-№1.-p.417-424.
 20. Aslonova M.ZH., Ikhtiyarova G.A., Khafizova D.B., Mirzoyeva M.R. Mikrobiologicheskaya i gormonal'naya kharakteristika formirovaniya nerazvivayushcheysya beremennosti// Fundamental'nyye i prakticheskiye voprosy immunologii i infektologii. Sbornik nauchnykh statey uchastnikov mezhdunarodnoy nauchno-prakticheskoy konferentsii. UFA. - 2018. - S. 9-15.
 21. Nuraliev N.A., Ikhtiyarova G.A. Diagnostis Value Determination of Antibodies to Antigens of Misro – organisms in women with inflammatoru diseases of the relvis organs. \ \ Amerisan journal of medisine and medisal ssienses-2020 № 10 (2) R.124-126.
 22. Oripova F.SH., Ikhtiyarova G.A. Saidov S.A. Metodika vyyavleniya markerov disbioza vlagalishcha i yeye svoeyevremennaya korrektsiya: Metodicheskaya rekomendatsiya. - Tashkent, 2020. - S.25-27.
 23. Oripova F.SH., Ikhtiyarova G.A. Saidov S.A. Metodika vyyavleniya patomorfologicheskikh izmeneniy slizistoy stenki vlagalishcha pri eksperimental'nom nespetsificheskome vaginite i razlichnykh metodikakh lecheniya: Metodicheskaya rekomendatsiya. - Tashkent, 2020.
 24. Tosheva I.I. Iskhody rodov y beremennykh s prezhdevremennym izlitiyem okoloplodnykh vod/I.I. Tosheva, N.G. Ashyrova// Vestnik Dagestanskoy gosydarstvennoy meditsinskoy akademii.-2019.-№ 4(33). - S.34-38.
 25. Tosheva I.I. Rodovozbyzhdeniye pri antenatal'noy gibeli ploda y zhenshchin s izlitiyem okoloplodnykh vod i vnytrytrobnoy infektsiyey / I.I. Tosheva, G.A. Ikhtiyarova, M.M. Rakhmatyllayeva // Nazariy va klinik tibbiyot. – Toshkent, 2019. - №5. – S.78-80.
 26. Ikhtiyarova G. A., Kurbanova Z.Sh., Oripova F.Sh. Reproductive rehabilitation of women with chronic inflammatory diseases of the genitals // Journal of biomedicine and practice special issue-2. - Tashkent, 2020. - Doi Journal 10.26739/2181-9300. P-56
 27. Oripova F.SH., Tosheva I.I. Razvitiye prezhdevremennogo izlitiye okoloplodnykh vod u

zhenshchin s ozhireniyem na fone vaginal'nykh infektsiy // Mezhdunarodnaya Nauchno-Prakticheskaya Konferentsiya «ozhireniye: mul'tidis-tsiplinaryy podkhod k probleme» Baku, Azerbaydzhan, 27-29 noyabrya 2019.

28. Oripova F.SH., Mavlonov A.A. Otsenka effektivnosti novykh metodov lecheniya na modeli travmaticheskogo nespetsificheskogo vaginita (kliniko-eksperimental'noye issledovaniye) // Vestnik Tashkentskoy meditsinskoy akademii. Tashkent, 2020. – S.162.
29. Oripova F.SH., Abdiyeva N.N. Assessment of the rehabilitation of the reproductive system in women with inflammatory diseases of the genitals. // Profilaktik tibbiyotda yuk,ori innovatsion texnologiyalarni k,ullash. Andizhon, 2020. – B. 548.
30. Oripova F.SH., Ikhtiyarova G.A. Saidov S.A. Primeneniye testa «femoflor-16» dlya otsenki sostoyaniya biotsenoza genital'nogo trakta (kliniko-eksperimental'noye issledovaniye) // Sbornik materialov II mezhdunarodnoy konferentsii studentov-medikov i molodykh uchenykh. Bukhara, 2020. – S. 42.