

Evaluation of Abutment Teeth in Fixed Partial Denture- A Retrospective Analysis of the Patient Records

Type of manuscript: Retrospective study

Running title: Evaluation of abutment teeth in FPD.

G.Nithya Karpagam

Saveetha Dental College And Hospitals
Saveetha Institute Of Medical And Technical Sciences
Saveetha University
Chennai, India
Email: 151501035.sdc@saveetha.com

Visalakshi Ramanathan

Senior Lecturer,
Department Of Prosthodontics,
Saveetha Dental College And Hospitals,
Saveetha Institute Of Medical And Technical Sciences
Saveetha University
Chennai, India
Email: visalakshirm.sdc@saveetha.com

Dinesh Prabu

Senior Lecturer,
Department Of Oral And Maxillofacial Surgery
Saveetha Dental college And Hospitals
Saveetha Institute Of Medical And Technical Sciences
Saveetha University
Chennai, India
Email: dineshprabum.sdc@saveetha.com

Corresponding author:

Visalakshi Ramanathan
Senior Lecturer,
Department Of Prosthodontics,
Saveetha Dental College And Hospitals,
Saveetha Institute Of Medical And Technical Sciences
Saveetha University
162,Poonamallee High Road
Chennai, India
Email: visalakshirm.sdc@saveetha.com

ABSTRACT:

The aim of this study is to evaluate the abutment teeth selection in fixed partial denture (FPD) done by undergraduate students. For this, patient records of those who underwent replacement of missing teeth with fixed partial denture were collected. A total of 50 patient radiographs were evaluated. The data on the following parameters: gender and age of the patient, crown root ratio, pocket depth, mobility, axial alignment of the abutment tooth, existing caries and periapical lesion or pulpal involvement and alveolar ridge form were collected. The data was tabulated in excel sheet. After data collection descriptive statistical analysis was done in SPSS software. In the current study the most prevalent gender in the study population to undergo FPD treatment were males (66%) than females (34%). The most prevalent age group opting for FPD treatment was between 41-50 years (52%). 38% of the evaluated FPD abutments had a Crown root ratio of 1:1, 40% of the abutments chosen for FPD construction were detected to have caries. Periapical lesion was present in 13% of the abutment teeth evaluated. Axial alignment of the tooth showed mostly normal alignment representing (65%); pulpal involvement and root canal treatment were done in 17% of the evaluated abutments. The alveolar ridge form of the evaluated patients showed flat ridge (58%). The present study shows appropriate parameters that have to be evaluated by undergraduate students during abutment selection for treatment planning of FPD.

KEYWORDS: Abutment; Crownroot ratio; fixed partial denture; Probing depth

INTRODUCTION:

Fixed prosthodontic treatment deals with the replacement of teeth by artificial substitutes that are not readily removable from the mouth. Its focus is to restore function, esthetics and comfort[(1)]The fixed partial denture (FPD) is one of the most commonly preferred treatment options for a single missing tooth. [(2)] FPDs were considered to be the best treatment choice for replacing a single missing tooth [(3)] Fixed prosthodontics treatment can range from the restoration of a single tooth to rehabilitation [(4)]

Dentofacial problems are known to cause negative effects over the patients satisfaction with their dentition [(5,6)]. Single teeth can be restored to full function, and improvement in cosmetic effect can be achieved. Missing teeth can be replaced with prostheses that will improve patient comfort and masticatory efficiency, maintain the health and integrity of the dental arches [(7)] Conventional crowns and bridgeworks make up a major element of general and prosthodontic dental practice, especially in developing countries [(8)] [(9)] The fixed partial denture is one of the most commonly preferred definitive treatment options for a single missing tooth. For many years, FPDs were considered to be the best treatment choice for replacing a single missing tooth. The primary reasons for suggesting FPDs are its clinical ease and reduced treatment time and costs [(10)] The replacement of missing teeth with fixed partial dentures is largely dependent upon the health and stability of the surrounding periodontal structures [(11)]

Various studies were done in our department on different fields like determination of correlation of width of maxillary anterior teeth [(12)], periodontal health status in groups wearing temporary partial denture [(13)], study on implants [(14,15)], studies on microorganisms [(16,17)], effect of resin bonded luting cement [(18)], cervical incisal marginal discrepancy [(19,20)] The other studies are done on the natural products like aloe vera [(21)] Various studies are also done on awareness

about all ceramic restoration in rural population[(22)],review on retraction cords[(23)].oral hygiene status in pregnant women[(24)]

As abutment selection places an important role in the success of fixed prosthesis, this study invigilates the evaluation of factors influencing abutment selection of FPD constructed in undergraduate wing. Our team has rich experience in research and we have collaborated with numerous authors over various topics in the past decade (25)(26–48). Our team has rich experience in research and we have collaborated with numerous authors over various topics in the past decade (25)(26–48). The aim of this study is to evaluate the abutment teeth selection in fixed partial denture (FPD) done by undergraduate students.

MATERIALS AND METHODS:

Study Setting:

The study was conducted with the approval of the Institutional Ethics Committee [SDC/SIHEC/2020/DIASDATA/0619-0320]. The study consisted of one reviewer, one assessor and one guide.

Study Design:

The study was designed to include patients who underwent fixed prosthodontics. The patients who did not fall under this inclusion criteria were excluded.

Sampling technique:

The study was based on the random sampling method. To minimise the sampling bias, all the cases were reviewed priorly and included.

Data Collection And Tabulation:

Data collection was done using the patient database with the timeframe work of 1st June 2019 to 30th April 2020. About 50 patient radiographs were reviewed and those fitting under the inclusion criteria were included. Cross verification of data was done by a reviewer. The collected data was tabulated based on the following parameters: Gender, Age, Crown root ratio, Presence or absence of caries, Presence or absence of periapical pathology, Axial alignment of the teeth over a scale of parallel/normal, supraerupted, mesially drifted, distally drifted, Probing depth of pockets in abutment teeth in millimetres, Mobility in abutment teeth over a scale of grade 0,1,2,3, Presence or absence of Pulpal involvement in abutment teeth(vital/nonvital), Alveolar ridge form of the edentulous span.

Statistical Analysis:

The variables were coded and the data was imported to SPSS. Using SPSS Version 20.0 categorical variables were expressed in terms of frequency and percentage and bar graphs were plotted. The statistical significance of the associations were tested using the Chi-square test.

RESULTS

A total of 50 Patient records and OPGs were assessed to evaluate the 100 abutments in FPD. In this study it is shown that the most prevalent gender in the study population to undergo FPD treatment were males(66%) than females (34%). The most prevalent age group opting for FPD

treatment was between 41-50 years(52%). 38% of the evaluated FPD abutments had a Crown root ratio of 1:1 ,40% of the abutments chosen for FPD construction were detected to have caries and periapical lesion was present in only 13% of the abutment teeth evaluated. Axial alignment of the tooth showed mostly normal alignment (65%); pulpal involvement and root canal treatment were done in (17%) of the evaluated abutments. The alveolar ridge form of the majority patients in the study represented a flat ridge (58%).

DISCUSSION:

This study has provided information on the parameters of abutment teeth chosen for fixed partial denture. In the study population 66% participants who opted for FPD as a treatment option to replace missing teeth were males and 34% were females.(Figure 1)In the current study, the majority of the patients who underwent fixed partial denture treatment fall into an age group of 41 to 50 years (52%) followed by 30 to 40 years (24%), 51 to 60 years (22%) and 61 to 70 (2%).(Figure 2)

Periodontal tissues play a major role in support and function of abutments. Healthy periodontium is a primary requirement for all prosthetic and restorative therapies as it is considered as a prerequisite for a probable prognosis after restorative therapy[(49)].About 52% of the abutment teeth in this study demonstrated 3mm pocket depth, 6% showed 4mm, 26% depicted 5mm and 16% showed 6mm of pocket depth. (Figure 3)

In the past studies have shown that the indications and contra-indications for extensive tooth-supported fixed prosthodontic treatment in periodontally compromised patients are highly dependent on the mobility of the remaining teeth, affecting patient comfort and chewing ability.[(11)]In the present study, only 4% of the participants represented grade (II) mobility, 14% of the abutment demonstrated grade (I) mobility and mostly about 82% were ideal abutments with no mobility.(Figure 4)

Abutment teeth with healthy periodontium and ideal crown root ratio provide a suitable biomechanical factor in fixed partial denture construction.Thus, it is important to choose a periodontally healthy abutment in rehabilitating compromised dentition[(50)]Crown root ratio is considered a primary variable in the selection of a tooth as an abutment for the various types of prosthetic restorations, such as fixed dental prostheses removable partial dentures or overdentures.In this study about 22% of the abutments represented an ideal crown root ratio of 2:3, 21% depicted a crown root ratio of 1:2, 38% showed 1:1 ratio and 19% showed 2:1.(Figure 5)

Dental caries and periodontal diseases are considered the most common causes of the tooth loss.In this study, dental caries of existing abutments were assessed both clinically and radiographically. It is observed that the majority of the abutments were non carious 60% and 40% showed carious lesions.(Figure 6) The most apparent reason for re-treatment and replacement in restorative failures is recurrent caries under restorations which risks the abutment of periapical pathology and abutment becomes non vital and requires Root canal treatment.In the current study 13% of the evaluated abutments had periapical pathology whereas 87% of the abutment teeth were free from periapical lesion.(Figure 7) Vital teeth are often preferred to non

vital teeth as an abutment.(Figure 8) shows about 83% showed no pulpal involvement and only about 17% showed involvement of pulp and were indicated for root canal treatment[(51)]

Alveolar ridge form also plays an important role in fixed partial denture fabrication. In this study the majority showed flat ridges 58% and 42% showed resorbed ridges. (Figure 9)

Management of drifted abutments involves uprighting the drifted teeth with orthodontic treatment . Our institution is passionate about high quality evidence based research and has excelled in various fields ((43,44,52–60)). Orthodontics is an integral component of multidisciplinary therapy frequently enhancing the aesthetics and function of the final restoration.In this study 65% of the abutment teeth showed normal axial alignment,12% abutments showed supraeruption,14% were mesially drifted and 9% demonstrated a distal drift.(Figure 10)

(Figure 11) shows the association between the gender and carious lesion in the abutment teeth. The P Value <0.05(chi square value) was statistically significant.(0.041) and (Figure 12) shows the association between the age and carious lesion in the abutment teeth.The P Value <0.05(chi square value) was statistically significant.(0.031)As abutment selection plays an important role in the success of fixed prosthesis, this study invigilated the evaluation of factors influencing abutment selection for FPD.

The present study shows appropriate parameters that have to be evaluated during treatment planning for fixed partial denture. Proper abutment selection influences the prognosis of the prosthesis. The prognosis of the prosthesis depends on abutment evaluation and treatment planning.Our institution is passionate about high quality evidence based research and has excelled in various fields ((43,44,52–60). Henceforth academically dental undergraduates need to be trained not only to have an overall picture of abutment evaluation but also a thorough knowledge on the parameters for abutment selection to aid in decision making towards treatment choices and treatment planning for their patients which surely is an eye opener towards understanding and practising the interdisciplinary approach in patient care.

CONCLUSION:

Within the limits of the present study it is concluded that the majority of the participants who opted for FPD as a treatment option were males than females, and most of them fall into the age group of 41-50 years. Majority of the evaluated abutments were non carious, with minimal periapical involvement, Probing depth, pulpal involvement, showed normal alignment of the abutment and depicted a crown root ratio of 1:1 with the majority having flat alveolar ridge form.

ACKNOWLEDGEMENTS:

The authors thank and acknowledge Saveetha dental college for providing access to use the retrospective data from the Prosthodontic department for the study.

AUTHOR CONTRIBUTION:

G. Nithya Karpagam has contributed to study design, data collection,analysis of the data,tabulation of results,manuscript typing .

Dr. Visalakshi Ramanathan has contributed to study design, data collection, analysis of the data, tabulation of results, manuscript typing and formatting and critical reviewing.

Dr. Dinesh Prabu has contributed to formatting and proofreading

CONFLICT OF INTEREST:

This research project is self funded. There is no conflict of interest.

REFERENCES:

1. Sharma R, Tiwari H, Singh D. Assessment of Complications Associated with Fixed Partial Denture-A Clinical Study. Journal of Advanced Medical and Dental Sciences Research [Internet]. 2018;6(1). Available from: <http://jamdsr.com/uploadfiles/32ComplicationsAssociatedwithFPDvol6issue1pp131-134.20190307032200.pdf>
2. Thirunavakarasu R, Ganapathy D. Assessment of clinical skills of students in fixed partial denture. Drug Invention [Internet]. 2019; Available from: <http://search.ebscohost.com/login.aspx?direct=true&profile=ehost&scope=site&authtype=crawler&jrnl=09757619&AN=137153965&h=ZBbJlxX%2F1BDVnfXCxP0tL42DyroYbHJF11qc%2FAdhr14ubrxPHPvt%2BDkaMXm96mLTbiPRgUZ8%2BxrnJh54xVqtFQ%3D%3D&crl=c>
3. Subhashini MHR, Abirami G, Jain AR. Abutment selection in fixed partial denture-A review. Drug Invention Today [Internet]. 2018;10(1). Available from: http://www.academia.edu/download/59480192/wassem_fixed_partial_denture20190601-60928-1c18q50.pdf
4. Sumeet S, Rajesh S, Harvinder S, Sarbjeet S, Nikhil WD. Abutment evaluation--A boon to success of fixed partial denture. J Dent Herald. 2014;1:38–42.
5. Ashok V, Nallaswamy D, Benazir Begum S, Nesappan T. Lip Bumper Prosthesis for an Acromegaly Patient: A Clinical Report. The Journal of the Indian Prosthodontic Society. 2014 Dec;14(Suppl 1):279.
6. Venugopalan S, Ariga P, Aggarwal P, Viswanath A. Case Report: Magnetically retained silicone facial prosthesis. Niger J Clin Pract. 2014 Mar 27;17(2):260–4.
7. Talabani RM. Influence of abutment evaluation on designing of fixed partial denture: A clinical study. Int J Oral Health Med Res. 2016;3:2395–7387.
8. Sailer I, Pjetursson BE, Zwahlen M. A systematic review of the survival and complication rates of all- ceramic and metal–ceramic reconstructions after an observation period of at least 3 years. Part II: fixed Clin Oral Implants Res [Internet]. 2007; Available from: <https://onlinelibrary.wiley.com/doi/abs/10.1111/j.1600-0501.2007.01468.x>
9. Raza M, Fayyaz M, Akram S. COMPLICATIONS AND THEIR SEVERITY IN PATIENTS OF CONVENTIONAL METAL CERAMIC FIXED DENTAL PROSTHESIS: A CLINICAL STUDY. Pakistan Oral & Dental [Internet]. 2015; Available from: <http://search.ebscohost.com/login.aspx?direct=true&profile=ehost&scope=site&authtype=crawler&jrnl=10128700&AN=102677918&h=vz3EeOqJN11Rm7hLcCo3Hk%2FsRIBnzGc97%2FG62nywZEn26Z7Dv21PQ4RSIrlJGB4zqiVmcfvdErrtfx7PAXTGSuQ%3D%3D&crl=c>
10. Tomruk CÖ, Özkurt-Kayahan Z, Şençift K. Patients' knowledge and awareness of dental implants in a Turkish subpopulation [Internet]. Vol. 6, The Journal of Advanced Prosthodontics. 2014. p. 133. Available from: <http://dx.doi.org/10.4047/jap.2014.6.2.133>

11. Al-Sinaidi A, Preethanath RS. The effect of fixed partial dentures on periodontal status of abutment teeth [Internet]. Vol. 5, The Saudi Journal for Dental Research. 2014. p. 104–8. Available from: <http://dx.doi.org/10.1016/j.ksujds.2013.11.001>
12. Jain AR, Nallaswamy D, Ariga P. Determination of Correlation of Width of Maxillary Anterior Teeth with Extraoral Factor (Interpupillary Width) in Indian Population [Internet]. JOURNAL OF CLINICAL AND DIAGNOSTIC RESEARCH. 2019. Available from: <http://dx.doi.org/10.7860/jcdr/2019/41082.12988>
13. Jyothi S, Robin PK, Ganapathy D, Anandiselvaraj. Periodontal Health Status of Three Different Groups Wearing Temporary Partial Denture [Internet]. Vol. 10, Research Journal of Pharmacy and Technology. 2017. p. 4339. Available from: <http://dx.doi.org/10.5958/0974-360x.2017.00795.8>
14. Duraisamy R, Krishnan CS, Ramasubramanian H, Sampathkumar J, Mariappan S, Navarasampatti Sivaprakasam A. Compatibility of Nonoriginal Abutments With Implants: Evaluation of Microgap at the Implant–Abutment Interface, With Original and Nonoriginal Abutments. Implant Dent. 2019 Jun;28(3):289.
15. Kannan A, Others. Effect of Coated Surfaces influencing Screw Loosening in Implants: A Systematic Review and Meta-analysis. WORLD. 2017;8(6):496–502.
16. Selvan SR, Ganapathy D. Efficacy of fifth generation cephalosporins against methicillin-resistant Staphylococcus aureus-A review [Internet]. Vol. 9, Research Journal of Pharmacy and Technology. 2016. p. 1815. Available from: <http://dx.doi.org/10.5958/0974-360x.2016.00369.3>
17. Vijayalakshmi B, Ganapathy D. Medical management of cellulitis. Research Journal of Pharmacy and Technology. 2016;9(11):2067–70.
18. Ganapathy D. Effect of Resin Bonded Luting Agents Influencing Marginal Discrepancy in All Ceramic Complete Veneer Crowns [Internet]. JOURNAL OF CLINICAL AND DIAGNOSTIC RESEARCH. 2016. Available from: <http://dx.doi.org/10.7860/jcdr/2016/21447.9028>
19. Ranganathan H, Ganapathy DM, Jain AR. Cervical and Incisal Marginal Discrepancy in Ceramic Laminate Veneering Materials: A SEM Analysis. Contemp Clin Dent. 2017 Apr;8(2):272–8.
20. Ajay R, Suma K, Ali S, Sivakumar JK, Rakshagan V, Devaki V, et al. Effect of surface modifications on the retention of cement-retained implant crowns under fatigue loads: An In vitro study [Internet]. Vol. 9, Journal of Pharmacy And Bioallied Sciences. 2017. p. 154. Available from: http://dx.doi.org/10.4103/jpbs.jpbs_146_17
21. Subasree S, Murthykumar K, Dhanraj. Effect of Aloe Vera in Oral Health-A Review [Internet]. Vol. 9, Research Journal of Pharmacy and Technology. 2016. p. 609. Available from: <http://dx.doi.org/10.5958/0974-360x.2016.00116.5>
22. Ashok V, Suvitha S. Awareness of all ceramic restoration in rural population. Research Journal of Pharmacy and Technology. 2016;9(10):1691–3.
23. Kannan A, Venugopalan S. A systematic review on the effect of use of impregnated retraction cords on gingiva. Research Journal of Pharmacy and Technology. 2018;11(5):2121–6.
24. Basha FYS, Ganapathy D, Venugopalan S. Oral Hygiene Status among Pregnant Women. Research Journal of Pharmacy and Technology. 2018;11(7):3099–102.
25. Subramanyam D, Gurunathan D, Gaayathri R, Vishnu Priya V. Comparative evaluation of salivary malondialdehyde levels as a marker of lipid peroxidation in early childhood caries. Eur J Dent. 2018 Jan;12(1):67–70.
26. Panchal V, Jeevanandan G, Subramanian E. Comparison of instrumentation time and obturation quality between hand K-file, H-files, and rotary Kedo-S in root canal treatment of primary teeth: A randomized controlled trial. J Indian Soc Pedod Prev Dent. 2019 Jan;37(1):75–9.

27. Rajeshkumar S, Kumar SV, Ramaiah A, Agarwal H, Lakshmi T, Roopan SM. Biosynthesis of zinc oxide nanoparticles using *Mangifera indica* leaves and evaluation of their antioxidant and cytotoxic properties in lung cancer (A549) cells. *Enzyme Microb Technol*. 2018 Oct;117:91–5.
28. Abhinav RP, Selvarasu K, Maheswari GU, Taltia AA. The Patterns and Etiology of Maxillofacial Trauma in South India. *Ann Maxillofac Surg*. 2019 Jan;9(1):114–7.
29. Marimuthu M, Andiappan M, Wahab A, Muthusekhar MR, Balakrishnan A, Shanmugam S. Canonical Wnt pathway gene expression and their clinical correlation in oral squamous cell carcinoma. *Indian J Dent Res*. 2018 May;29(3):291–7.
30. Kavarthapu A, Thamaraiselvan M. Assessing the variation in course and position of inferior alveolar nerve among south Indian population: A cone beam computed tomographic study. *Indian J Dent Res*. 2018 Jul;29(4):405–9.
31. Ramesh A, Vellayappan R, Ravi S, Gurumoorthy K. Esthetic lip repositioning: A cosmetic approach for correction of gummy smile - A case series. *J Indian Soc Periodontol*. 2019 May;23(3):290–4.
32. Sweta VR, Abhinav RP, Ramesh A. Role of virtual reality in pain perception of patients following the administration of local anesthesia. *Ann Maxillofac Surg*. 2019 Jan;9(1):110–3.
33. Felicita AS. Orthodontic extrusion of Ellis Class VIII fracture of maxillary lateral incisor - The sling shot method. *Saudi Dent J*. 2018 Jul;30(3):265–9.
34. Rao TD, Kumar MPS. Analgesic efficacy of paracetamol vs ketorolac after dental extractions. *J Adv Pharm Technol Res*. 2018;11(8):3375.
35. Fluoride, fluoridated toothpaste efficacy and its safety in children - review. *Int J Pharm Res* [Internet]. 2018 Oct 1;10(04). Available from: <http://www.ijpronline.com/ViewArticleDetail.aspx?ID=7041>
36. Ponnulakshmi R, Shyamaladevi B, Vijayalakshmi P, Selvaraj J. In silico and in vivo analysis to identify the antidiabetic activity of beta sitosterol in adipose tissue of high fat diet and sucrose induced type-2 diabetic experimental rats. *Toxicol Mech Methods*. 2019 May;29(4):276–90.
37. Paramasivam A, Vijayashree Priyadharsini J, Raghunandhakumar S. N6-adenosine methylation (m6A): a promising new molecular target in hypertension and cardiovascular diseases. *Hypertens Res*. 2020 Feb;43(2):153–4.
38. Mehta M, Deeksha, Tewari D, Gupta G, Awasthi R, Singh H, et al. Oligonucleotide therapy: An emerging focus area for drug delivery in chronic inflammatory respiratory diseases. *Chem Biol Interact*. 2019 Aug 1;308:206–15.
39. Padavala S, Sukumaran G. Molar Incisor Hypomineralization and Its Prevalence. *Contemp Clin Dent*. 2018 Sep;9(Suppl 2):S246–50.
40. Pandian KS, Krishnan S, Kumar SA. Angular photogrammetric analysis of the soft-tissue facial profile of Indian adults. *Indian J Dent Res*. 2018 Mar;29(2):137–43.
41. Nair M, Jeevanandan G, R V, Emg S. Comparative evaluation of post-operative pain after pulpectomy with k-files, kedo-s files and mtwo files in deciduous molars -a randomized clinical trial. *Braz Dent Sci*. 2018 Oct 24;21(4):411.
42. Ke Y, Al Aboody MS, Alturaiki W, Alsagaby SA, Alfaiz FA, Veeraraghavan VP, et al. Photosynthesized gold nanoparticles from *Catharanthus roseus* induces caspase-mediated apoptosis in cervical cancer cells (HeLa). *Artif Cells Nanomed Biotechnol*. 2019 Dec;47(1):1938–46.
43. Sridharan G, Ramani P, Patankar S, Vijayaraghavan R. Evaluation of salivary metabolomics in oral leukoplakia and oral squamous cell carcinoma. *J Oral Pathol Med*. 2019 Apr;48(4):299–306.
44. Vijayashree Priyadharsini J, Smiline Girija AS, Paramasivam A. In silico analysis of virulence

- genes in an emerging dental pathogen *A. baumannii* and related species. *Arch Oral Biol.* 2018 Oct;94:93–8.
45. Krishnan RP, Ramani P, Sherlin HJ, Sukumaran G, Ramasubramanian A, Jayaraj G, et al. Surgical Specimen Handover from Operation Theater to Laboratory: A Survey. *Ann Maxillofac Surg.* 2018 Jul;8(2):234–8.
 46. Ezhilarasan D. Oxidative stress is bane in chronic liver diseases: Clinical and experimental perspective. *Arab J Gastroenterol.* 2018 Jun;19(2):56–64.
 47. Palati S, Ramani P, Shrelin HJ, Sukumaran G, Ramasubramanian A, Don KR, et al. Knowledge, Attitude and practice survey on the perspective of oral lesions and dental health in geriatric patients residing in old age homes. *Indian J Dent Res.* 2020 Jan;31(1):22–5.
 48. Wu F, Zhu J, Li G, Wang J, Veeraraghavan VP, Krishna Mohan S, et al. Biologically synthesized green gold nanoparticles from induce growth-inhibitory effect on melanoma cells (B16). *Artif Cells Nanomed Biotechnol.* 2019 Dec;47(1):3297–305.
 49. Sirajuddin S, Narasappa KM, Gundapaneni V, Chungkham S, Walikar AS. Iatrogenic Damage to Periodontium by Restorative Treatment Procedures: An Overview [Internet]. Vol. 9, *The Open Dentistry Journal*. 2015. p. 217–22. Available from: <http://dx.doi.org/10.2174/1874210601509010217>
 50. Chitumalla R, Munaga S, Khare A, Agarwal S, Bhoyar A, Parlani S. Stress distribution among periodontally compromised abutments: A comparative study using three-dimensional finite element analysis [Internet]. Vol. 3, *Contemporary Clinical Dentistry*. 2012. p. 452. Available from: <http://dx.doi.org/10.4103/0976-237x.107439>
 51. Aglarci OS, Bilgin MS, Erdem A, Ertas ET. Is it possible to diagnose caries under fixed partial dentures with cone beam computed tomography? *Oral Surg Oral Med Oral Pathol Oral Radiol.* 2015 May;119(5):579–83.
 52. Vijayashree Priyadharsini J. In silico validation of the non-antibiotic drugs acetaminophen and ibuprofen as antibacterial agents against red complex pathogens. *J Periodontol.* 2019 Dec;90(12):1441–8.
 53. Pc J, Marimuthu T, Devadoss P. Prevalence and measurement of anterior loop of the mandibular canal using CBCT: A cross sectional study. *Clin Implant Dent Relat Res* [Internet]. 2018; Available from: <https://europepmc.org/article/med/29624863>
 54. Ramesh A, Varghese S, Jayakumar ND, Malaiappan S. Comparative estimation of sulfiredoxin levels between chronic periodontitis and healthy patients - A case-control study. *J Periodontol.* 2018 Oct;89(10):1241–8.
 55. Ramadurai N, Gurunathan D, Samuel AV, Subramanian E, Rodrigues SJL. Effectiveness of 2% Articaine as an anesthetic agent in children: randomized controlled trial. *Clin Oral Investig.* 2019 Sep;23(9):3543–50.
 56. Ezhilarasan D, Apoorva VS, Ashok Vardhan N. Syzygium cumini extract induced reactive oxygen species-mediated apoptosis in human oral squamous carcinoma cells. *J Oral Pathol Med.* 2019 Feb;48(2):115–21.
 57. Mathew MG, Samuel SR, Soni AJ, Roopa KB. Evaluation of adhesion of *Streptococcus mutans*, plaque accumulation on zirconia and stainless steel crowns, and surrounding gingival inflammation in primary molars: Randomized controlled trial. *Clin Oral Investig.* 2020;1–6.
 58. Samuel SR. Can 5-year-olds sensibly self-report the impact of developmental enamel defects on their quality of life? *Int J Paediatr Dent.* 2021 Mar;31(2):285–6.
 59. R H, Hannah R, Ramani P, Ramanathan A, R JM, Gheena S, et al. CYP2 C9 polymorphism among patients with oral squamous cell carcinoma and its role in altering the metabolism of

- benzo[a]pyrene [Internet]. Vol. 130, Oral Surgery, Oral Medicine, Oral Pathology and Oral Radiology. 2020. p. 306–12. Available from: <http://dx.doi.org/10.1016/j.oooo.2020.06.021>
60. Chandrasekar R, Chandrasekhar S, Sundari KKS, Ravi P. Development and validation of a formula for objective assessment of cervical vertebral bone age. Prog Orthod. 2020 Oct 12;21(1):38.

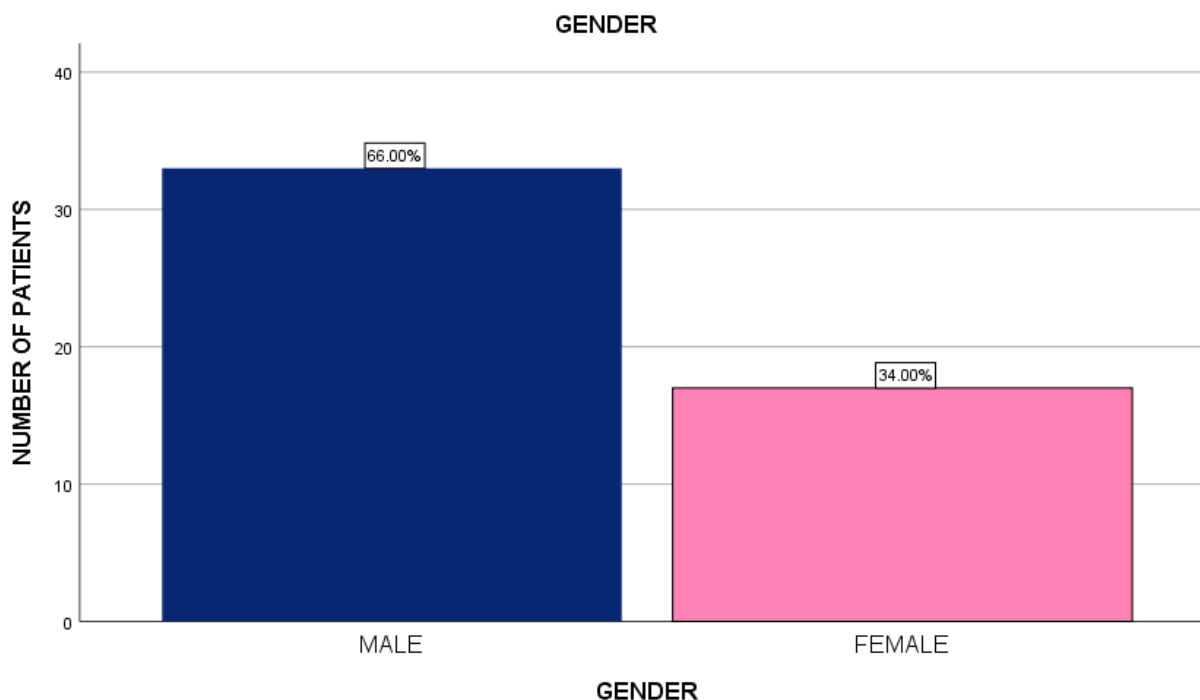


Figure 1: Bar chart showing Gender distribution among the study population. X axis represents Gender of patients undergoing FPD; Y axis represents the number of patients undergoing FPD. Majority of the patients were males - 66%, females - 34%.

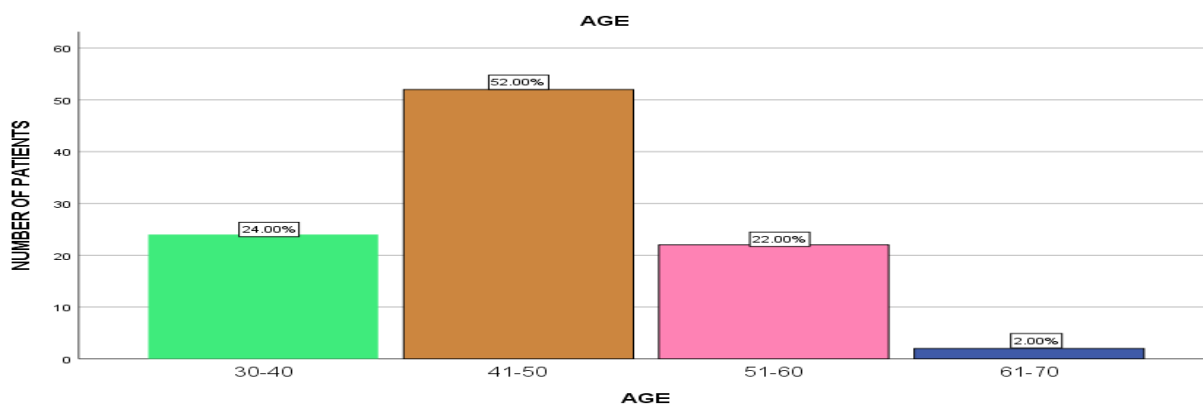


Figure 2: Bar chart representing the age distribution of the study population. X axis represents age of study participants; Y axis represents the number of patients undergoing FPD. The majority of the patients who underwent fixed partial denture treatment fall into the age group of 41-50 years.

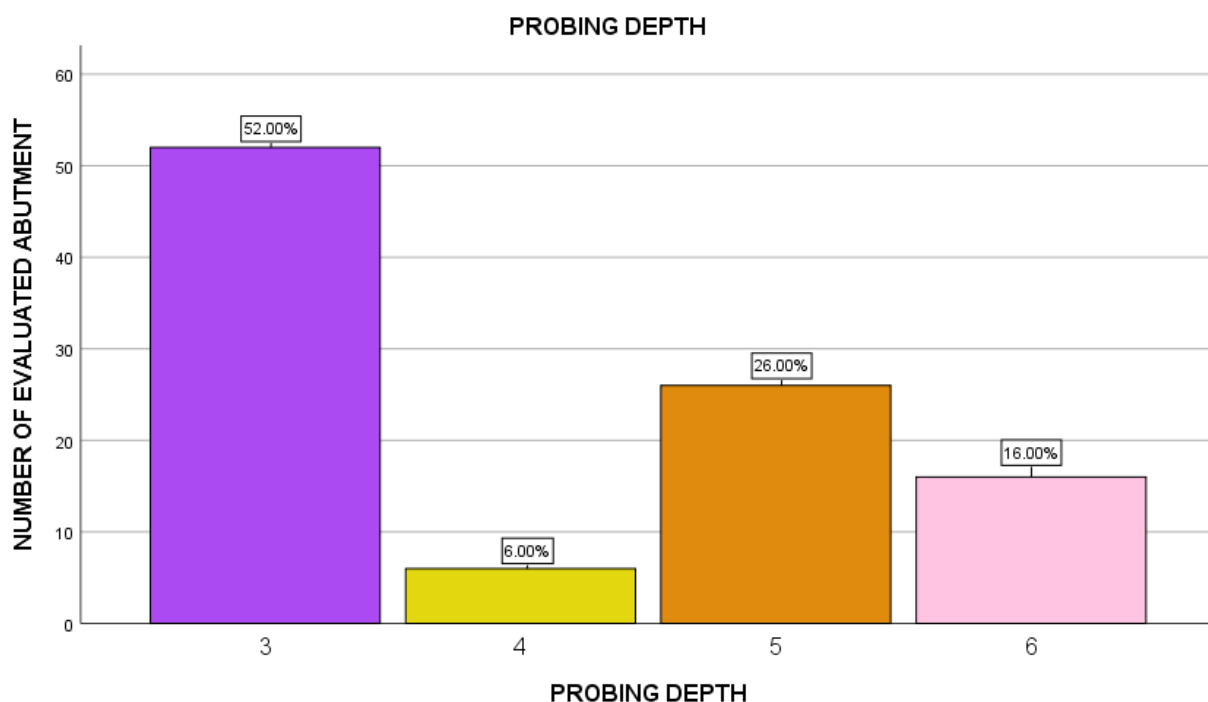


Figure 3: Bar chart showing the distribution of probing depth in FPD abutments. X axis represents the distribution of probing depth in mm; Y axis represents the number of evaluated abutments. Majority of the evaluated abutment showed probing depth of 3mm (52%) with the least at 4mm (6%).

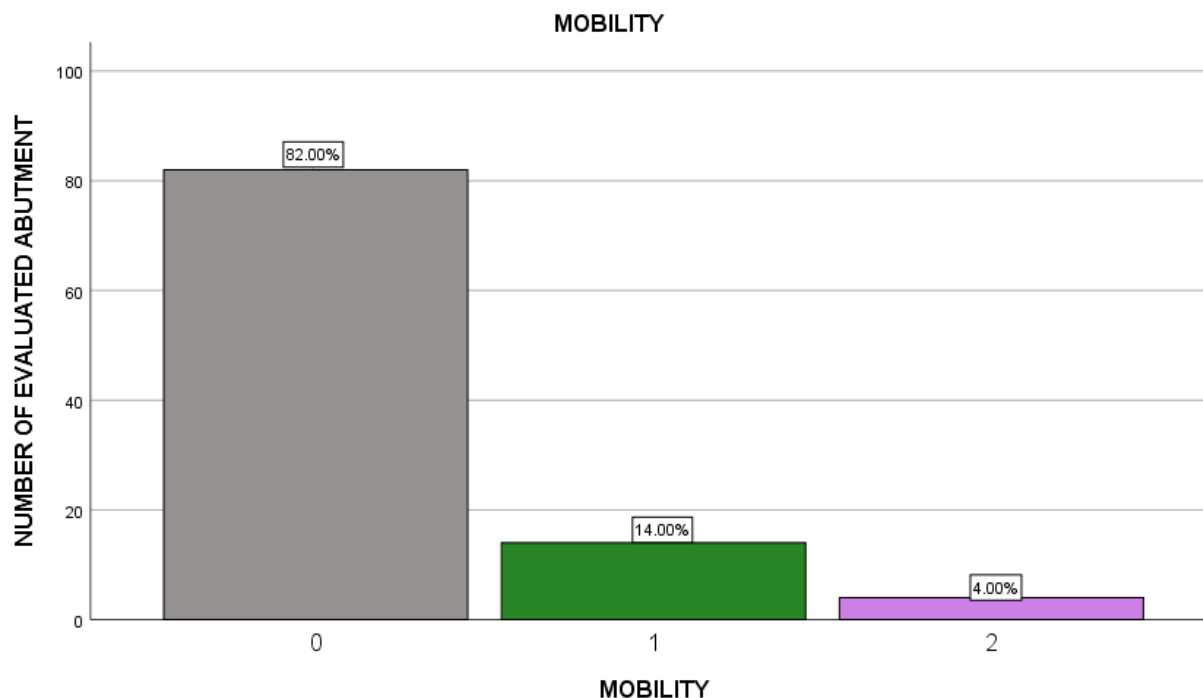


Figure 4: Bar chart showing the distribution of FPD abutments based on their Mobility. X axis represents the distribution of mobility (grade 0,1,2,3); Y axis represents the number of evaluated abutments. Majority of the evaluated abutments were not mobile (82%) whereas only 4% showed grade 2 mobility.

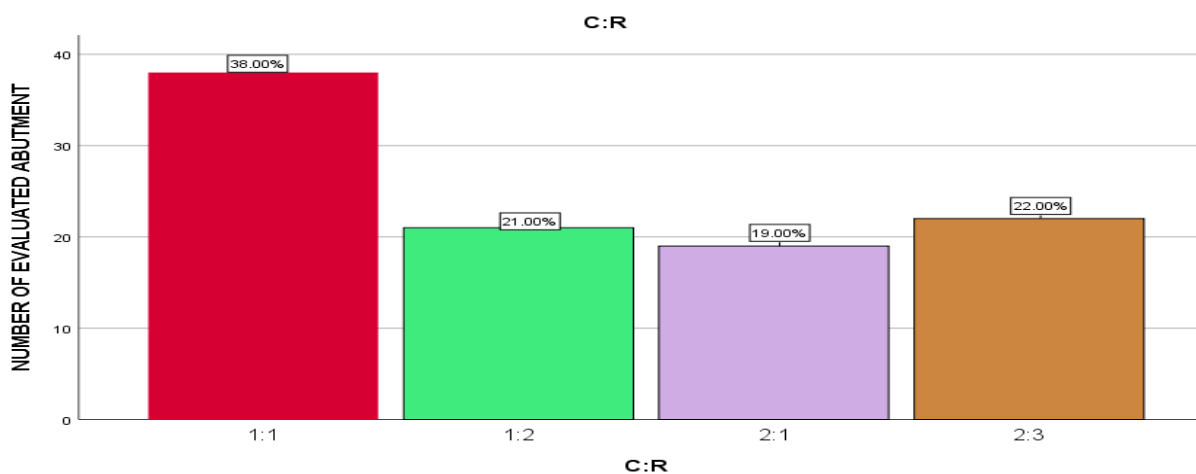


Figure 5: Bar chart showing Crown root (C:R) ratio distribution of FPD abutments. X axis represents crown root ratio; Y axis represents number of evaluated abutment. Majority of the abutment represented a C:R ratio of 1:1.

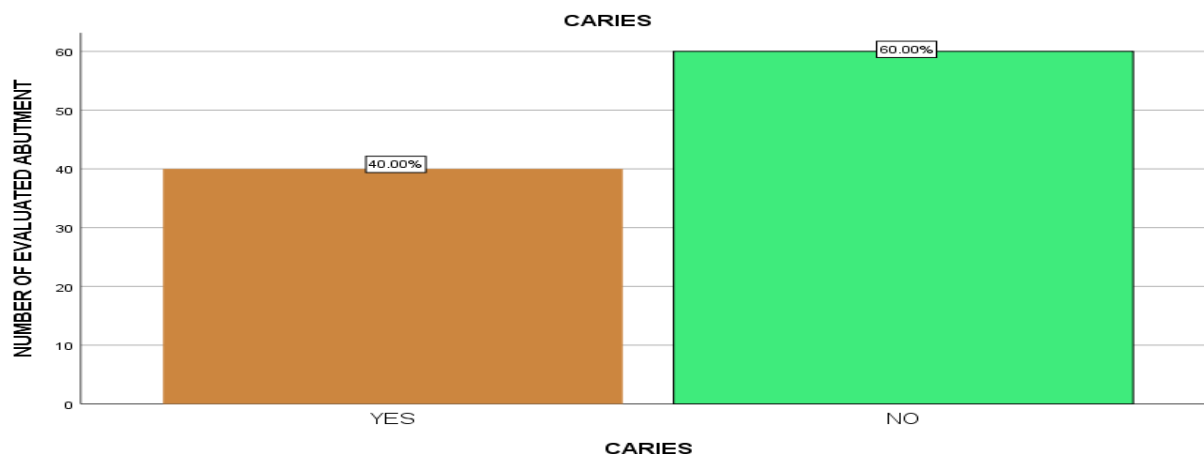

Figure 6: Bar chart showing the distribution of FPD abutments based on their carious state. X axis represents presence or absence of caries;Y axis represents the number of evaluated abutment.Majority of the abutments were healthy and only 40% had carious lesions.

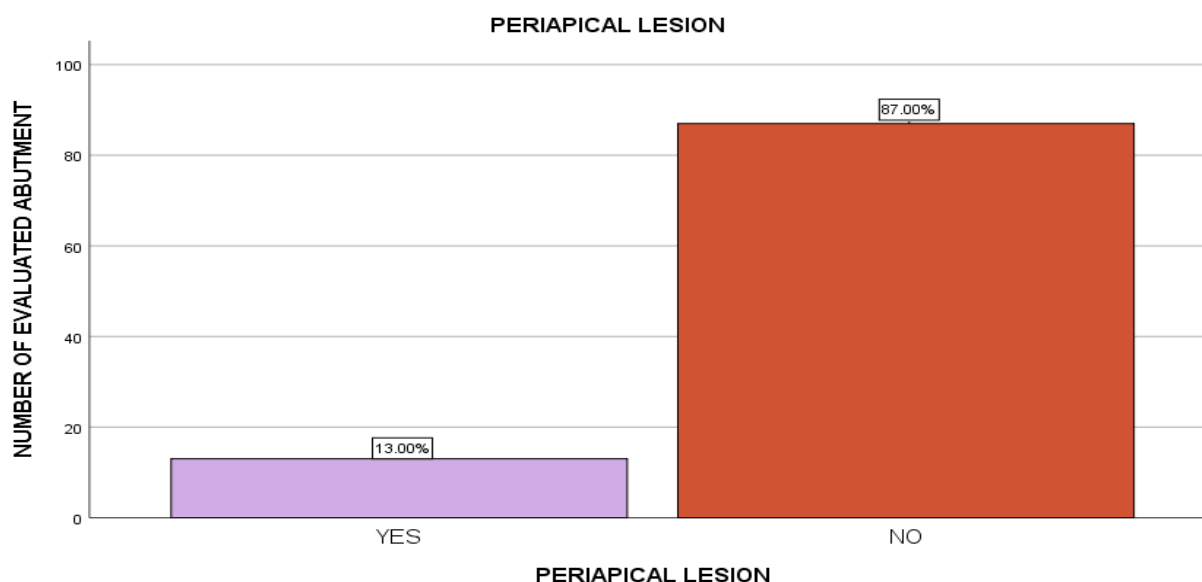


Figure 7: Bar graph showing the distribution of FPD abutments based on periapical lesion. X axis represents presence or Absence of periapical lesions;Y axis represents number of evaluated abutment.Only 13% of the abutments required endodontic therapy whereas 87% demonstrated satisfactory periapical health.

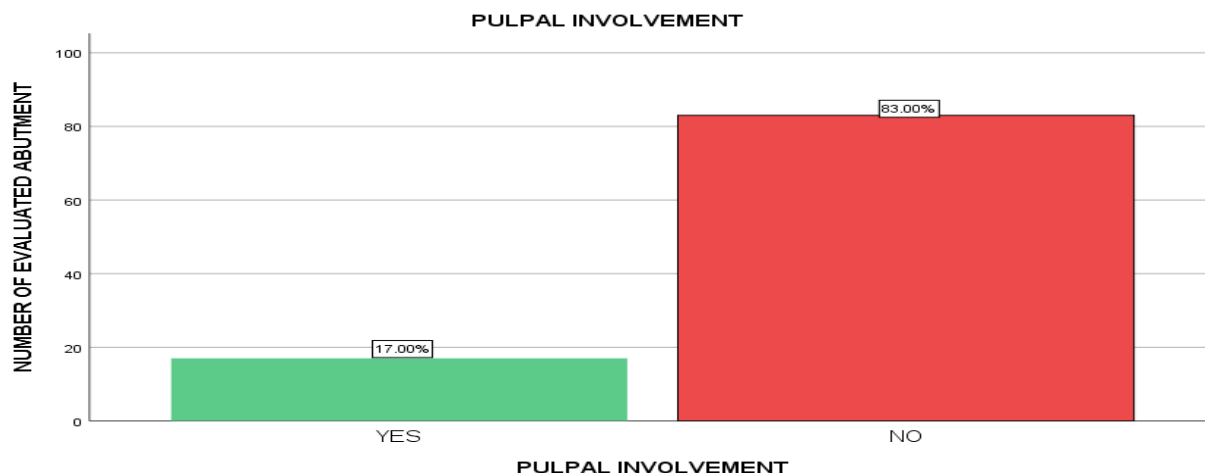


Figure 8: Bar graph showing the distribution of study population based on the pulpal involvement. X axis represents the presence or absence of pulpal involvement;Y axis represents the number of evaluated abutments.Majority of the abutments were healthy and only 17% had pulpal involvement..

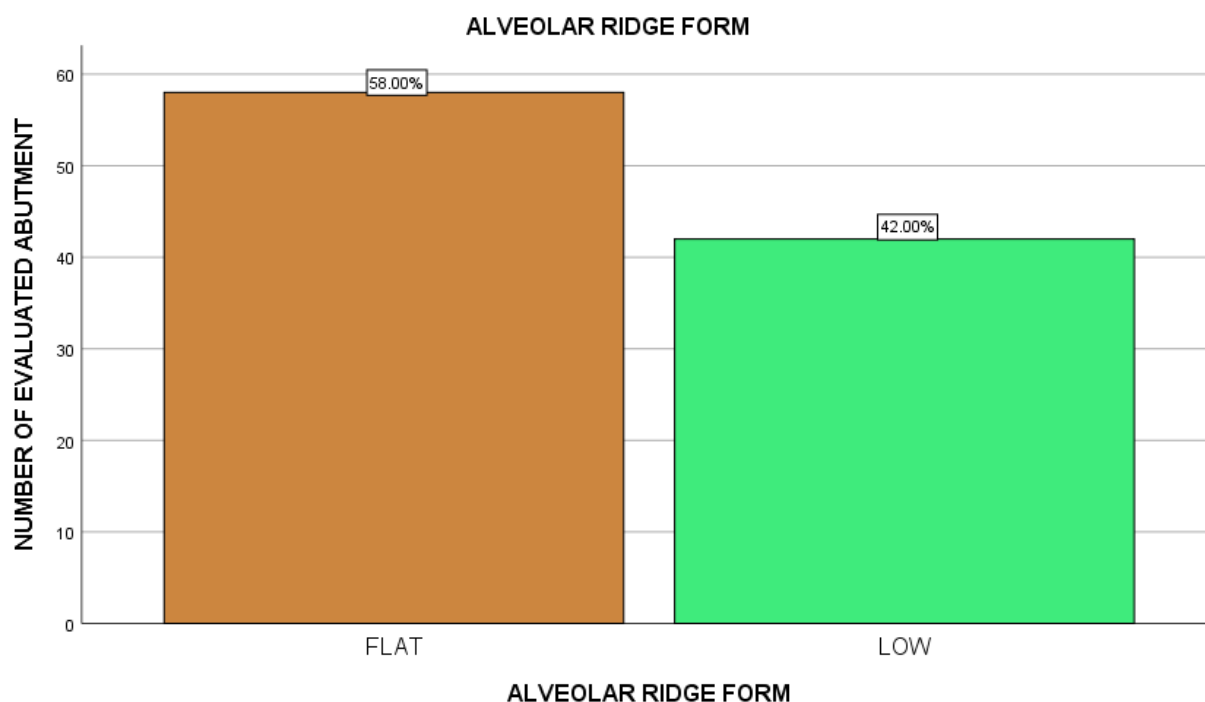


Figure 9: Bar graph showing the distribution of study population based on the alveolar ridge form of edentulous span. X axis represents the alveolar ridge form;Y axis represents the number of evaluated abutments.Majority of the alveolar ridge showed flat ridge 58% whereas 42% showed low ridge.

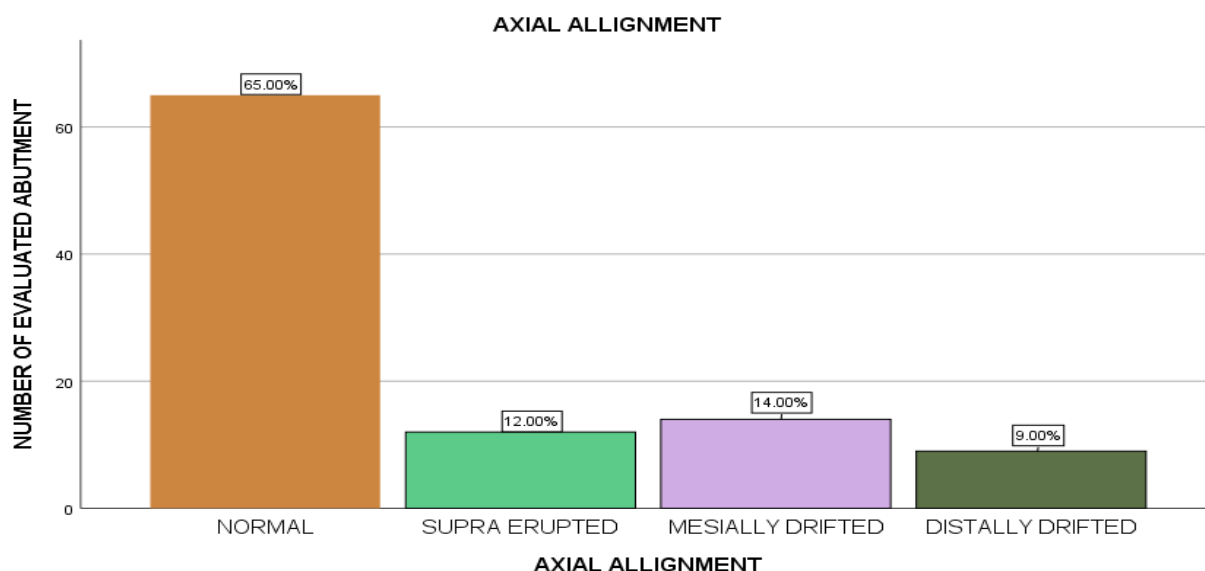


Figure 10: Bar chart showing the distribution of FPD abutments based on the axial alignment.X axis represents the distribution of axial alignment (over a scale of normal or parallel, supraerupted, mesially drifted, distally drifted);Y axis represents the number of evaluated abutment.About 65% of the abutment showed normal alignment.

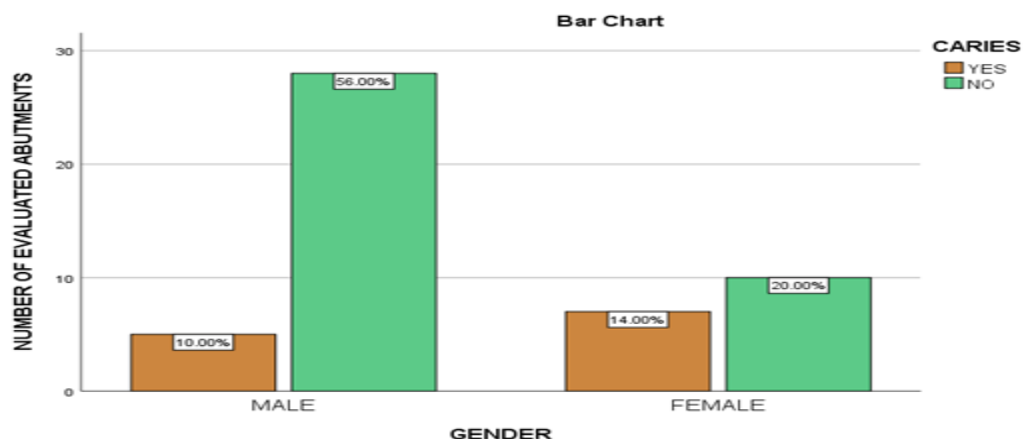


Figure 11:Bar graph depicting the association between the gender and carious lesion in the abutment teeth.X axis represents the distribution of gender and Y axis represents the number of evaluated abutment.From this we infer that majority of the evaluated abutments were healthy without any carious lesion and it was higher in the male population.The P Value <0.05(chi square value) was statistically significant.(0.041) There is a significant association between gender and Carious lesion.

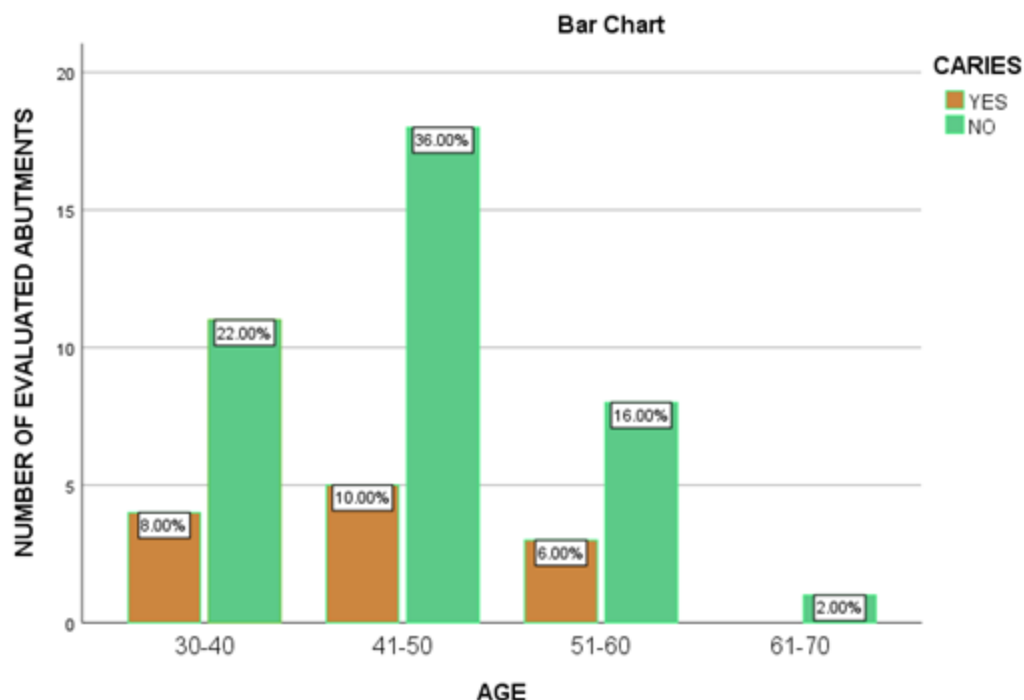


Figure 12: Bar graph depicting the association between the age and carious lesion in the abutment teeth. X axis represents the distribution of age and Y axis represents the number of evaluated abutment. From this we infer that majority of the evaluated abutments were healthy without any carious lesion and it was higher in the age group of 41-50 years. The P Value <0.05 (chi square value) was statistically significant (0.031). There is a significant association between Diabetic status and Tooth wear.