

## **Bewilderment in Bartholins Gland -An Unusual Location of Endometriosis**

**Dr. Sharmila.S<sup>1</sup>, Dr.SivasundariMaharajan<sup>2\*</sup>, Dr G.Rohini<sup>3</sup>, Dr.Sukanya.I<sup>4</sup>**

<sup>1</sup>Third Year Postgraduate, Department of Obstetrics and Gynaecology, Saveetha Medical College and Hospital

<sup>2\*</sup>Professor Department of Obstetrics and Gynaecology, Saveetha Medical College and Hospital

<sup>3</sup>Professor Department of Obstetrics and Gynaecology, Saveetha Medical College and Hospital

<sup>4</sup> Assistant Professor, Department of Obstetrics and Gynaecology, Saveetha Medical College and Hospital

\*Corresponding Author: Dr.SivasundariMaharajan Email id. sivasundarimdr@yahoo.com

### **ABSTRACT**

Endometriosis is a condition in which endometrial glands and stroma grow outside the endometrial cavity most often involving the pelvic cavity mainly the ovaries and dependent peritoneal surfaces. Endometriosis in bartholins gland is an extremely rare presentation. Only six cases have been reported in the world literature so far in women less than 35 years of age. A 46-year-old multiparous lady was admitted in our hospital with the complaint of a persistent swelling in the right vulvar region for past 6 months. The swelling was found to be more prominent during menstruation. Local Examination revealed a 4x6 cm cystic, non-fluctuant and non-tender mass was present in the right labia minora. The initial diagnosis of Bartholin gland cyst was made and the patient was planned for Bartholin cyst marsupialization. Intraoperatively the cyst ruptured during dissection and dark chocolate brown fluid was drained. Pathological examination confirmed the diagnosis of endometriosis. Endometriosis in the Bartholin gland being an underdiagnosed one, it should be considered there is cyclical pain & swelling of the Bartholin gland. Complete Surgical excision and histopathologic examination is necessary for a definitive diagnosis.

**Keywords:** Bartholin cyst, Endometriosis, Marsupialization, cyclical pain

### **INTRODUCTION**

Endometriosis is a condition in which endometrial glands and stroma grow outside the endometrial cavity most often involving the pelvic cavity mainly the ovaries and dependent peritoneal surfaces. It is a benign estrogen dependent disorder. This ectopic tissue responds to the hormonal variation in the cycle similar to uterine endometrium [1]. Endometriosis is a common disease, affecting 6-10% of women with childbearing age mainly latter half of reproductive life between 35-40 years [1]. Endometriotic implants in the vulva and Bartholin's gland are very unusual and only 6 cases of Bartholin's gland endometriosis have been documented. Bartholin glands (major vestibular gland) which are located symmetrically

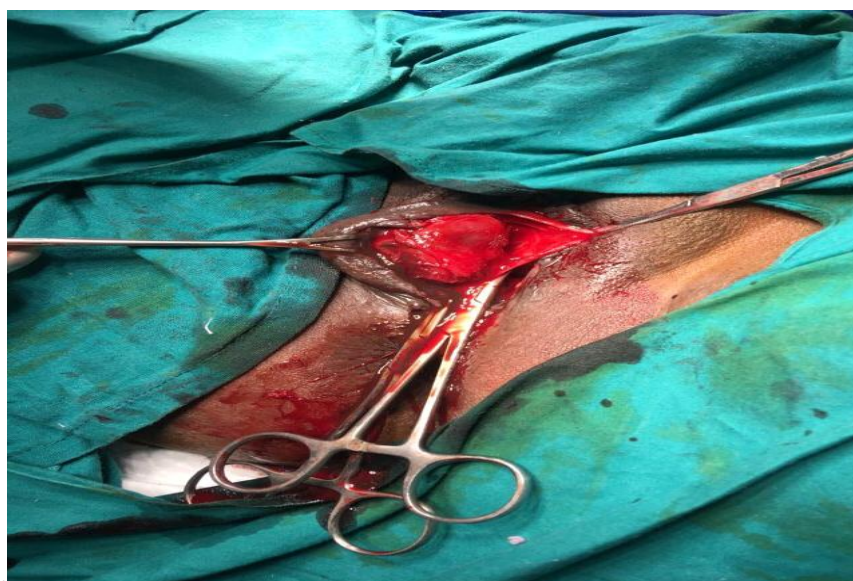at the posterior walls of the labia minora plays a role in vaginal lubrication. Any obstruction of a relatively smaller duct leads to accumulation of secretions and formation of cyst in Bartholin gland [2]. All the six cases reported in the world literature were in women less than 35 years of age. We report a case of Endometriosis in Bartholins gland in a 46-year-old woman for the first time in the world literature.

#### **CASE HISTORY:**

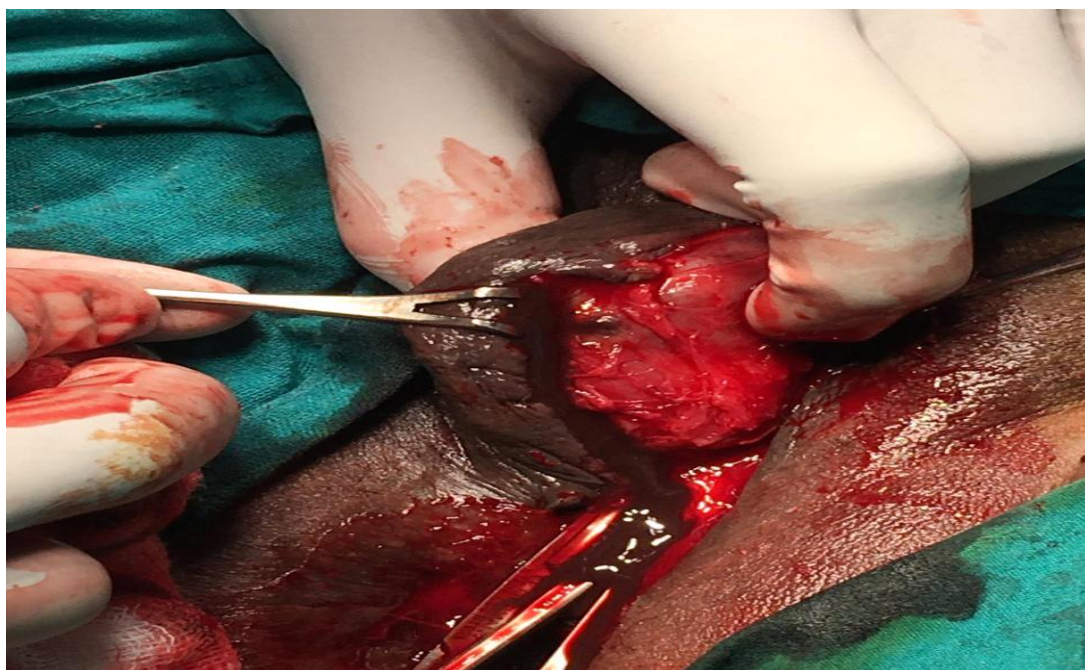
A 46-year-old multiparous woman admitted to our hospital with the complaint of a persistent swelling in the right vulvar region for past 6 months. The swelling was found to be more prominent during menstruation. It was associated with pain and discomfort on walking and doing household activities. Past history of recurrent swelling in the right vulva for the past 6 years subsiding spontaneously was present and no treatment was taken for the same. She had two normal vaginal deliveries with episiotomy with last child birth being 18 years. No history of any discharge from the cyst or fever episodes. No history of dysmenorrhea, dyspareunia or chronic pelvic pain, on examination a 4x6 cm cystic, non-fluctuant and non-tender mass was noted in the right labia minora. There was no warmth, no erythema or any discharge seen. Per vaginum examination revealed normal uterine size with fornices and pouch of Douglas free of mass, nodules and any tenderness. A transvaginal ultrasound revealed normal uterus and ovaries.

The initial diagnosis of Bartholin gland cyst was made and the patient was planned for Bartholin cyst marsupialization. Intraoperatively the cyst ruptured during marsupialization and the dark chocolate brown fluid was drained and clinical diagnosis of endometriosis was made [Fig 1,2]. Postoperative period was uneventful Histopathology report was consistent showing foci of endometriosis in Bartholin glands. She received one dose of DMPA 150 MG postoperatively. Patient is on follow-up and no recurrence of cyst till date

**Figure-1: Chocolate fluid from Bartholin's gland**



**Figure -2: Bartholin's cyst with chocolate fluid with endometriotic spot**



## DISCUSSION

Bartholin cyst is a common occurrence. It is caused by obstruction of the duct, but endometrioma formed within the Bartholin gland is an extremely rare condition. Ectopic endometrium usually results from transplantation of endometrial tissue and most of the Perineal or vulvar lesions of endometriosis are associated with previous episiotomy or surgery due to direct mechanical transplantation of endometrial tissue into the scar which results in perineal endometriosis [2] So far 6 Bartholin endometrioses have been reported in the world literature and none of them had vaginal delivery previously. Spontaneous spreading to the perineum is still not fully understood [3,6-10] As per Gocmen A et al, endometriosis in the Bartholin gland, theoretically can be result of celomic metaplasia ,lymphatic or vascular spread or it can be related to iatrogenic transplantation of endometrial tissues during vaginal delivery or gynaecological surgery[7] Endometriosis in the Bartholin gland may present with repeated cyclic pain and swelling during menstruation. It presents as a dark brown or blue cystic swelling at the posterior part of the vulva [10] Treatment of bartholinendometriotic cystic lesion should be planned according to patient's age, severity of symptoms, extent and involvement of other organs. Management includes complete surgical excision with avoidance of spillage, followed by hormonal treatment to prevent recurrence [1] According to Lan Zhu et al, patients who had hormone treatment before surgery, the histopathologic examination of the specimens showed gland atrophy and interstitial hyperplasia [1]. These cases confirmed the effectiveness of hormone treatment in perineal endometriosis. Medical management with oral contraceptives, progestogens, GnRH-agonist could cause temporary relief from symptoms but no drugs completely cured the disease. In this patient, there was no suspicion of endometriosis initially. The diagnosis of endometriosis in the bartholin gland is rare. Our patient had findings revealed a case of endometriosis outside the pelvis, without any deep intraperitoneal involvement.

## CONCLUSION:

Endometriosis in the Bartholin gland being an underdiagnosed one, it should be considered there is cyclical pain& swelling of the Bartholin gland. Complete Surgical excision and histopathologic examination is necessary for a definitive diagnosis.

## REFERENCES

1. Zhu L, Lang J, Wang H, Liu Z, Sun D, Leng J, et al. Presentation and management of perineal endometriosis. *Int J Gynaecol Obstet.* 2009;105(3):230–2.
2. LC Giudice. Clinical practice. Endometriosis. *N Engl J Med.* 2010;362(25):2389–98.
3. Heijink, T., Bogers, H. & Steensma, A. Endometriosis of the Bartholin gland: a case report and review of the literature. *J Med Case Reports* 14, 85 (2020).
4. Sosnik H, Sosnik K, Halon A. The pathomorphology of Bartholin's gland. Analysis of surgical data. *Pol J Pathol.* 2007;58(2):99–103.
5. Heller DS, Lespinasse P, Mirani N. Endometriosis of the perineum: a rare diagnosis usually associated with episiotomy. *J Low Genit Tract Dis.* 2016;20(3):e48–9.
6. Aydin Y, Atis A, Polat N. Bilateral endometrioma of Bartholin glands accompanying ovarian endometrioma. *J ObstetGynaecol.* 2011;31(2):187–9.
7. Gocmen A, Inaloz HS, Sari I, Inaloz SS. Endometriosis in the Bartholin gland. *Eur J ObstetGynecolReprod Biol.* 2004;114(1):110–1.
8. Hakimi IBY, Kouach J, Moussaoui D, Dehayni M. Endometriosis in the Bartholin Gland: A Case Report. *J Gynecol Obstet.* 2014;2(5):75–6.
9. Matseoane S, Harris T, Moscovitz E. Isolated endometriosis in a Bartholin gland. *N Y State J Med.* 1987;87(10):575–6.
10. Robotti G, Canepari E, Torresi M. Premenstrual inguinal swelling and pain caused by endometriosis in the Bartholin gland: a case report. *J Ultrasound.* 2014;18(1):71–2.