

Prosthodontic Rehabilitation of Young Adult Ectodermal Dysplasia Patient with Immediately Loaded Basal implants: A Case Report

Manu Rathee¹, Neeraj Chhikara², Anamika Ahlamat³, S Divakar⁴, Sujata Chahal⁵

¹Senior Professor and Head, Department of Prosthodontics,
Post Graduate Institute of Dental Sciences, Rohtak, Haryana, India.

Email ID: ratheemanu@gmail.com

²Ex-Senior Resident Student, Department of Prosthodontics,
Post Graduate Institute of Dental Sciences, Rohtak, Haryana, India.

Email ID: chhikara.neeraj17@gmail.com

³Ex-Senior Resident Student, Department of Prosthodontics,
Post Graduate Institute of Dental Sciences, Rohtak, Haryana, India.

Email ID: ahlawatanamika@yahoo.in

⁴Post Graduate Student, Department of Prosthodontics,
Post Graduate Institute of Dental Sciences, Rohtak, Haryana, India.

Email ID: divakarsanthanam17@gmail.com

⁵Post Graduate Student, Department of Prosthodontics,
Post Graduate Institute of Dental Sciences, Rohtak, Haryana, India.

Email ID: sujata.chahal1@gmail.com

ABSTRACT

Hypohidrotic ectodermal dysplasia is an X-linked disease and caused by mutations in the gene EDA, which located at Xq12–q13.1. Partial or complete absence of deciduous and permanent dentition is one of the most frequently occurring oral symptoms; a few teeth may be present but with conical shape. Full mouth rehabilitation in patients with ectodermal dysplasia (ED) is difficult to manage, because the affected individuals are quite young and hence the treatment was made on basis of their age, the development of dentition and jaw. Esthetics, function and comfort are three important concern to be evaluated during rehabilitation. This clinical report describes the rehabilitation of a 19-year-old girl diagnosed with ectodermal dysplasia. Various treatment options were given to patient, from which patient chooses the implant supported fixed prosthesis. After radiographic evaluation, nine basal implants were placed in the maxillary and mandibular arches immediately after extraction and were immediately reconstructed by metal-ceramic implant-supported fixed prostheses. The treatment provided favorable results in terms of function, esthetics

and psychological boost to the patient.

Keywords:- Bicortical Implants; Fixed Partial Dentures; Hypohidrotic Ectodermal Dysplasia; Implant supported prosthesis; Rehabilitation;

Introduction

Ectodermal dysplasia syndromes (EDS) is a large, heterogeneous collection of genetic conditions characterized by a congenital abnormality in two or more of the ectodermal derivatives, such as skin, hair, nails, eccrine glands, and teeth. Hypohidrotic (anhidrotic) ED and hidrotic ED are the two most frequent syndromes in this group⁽¹⁾. The most common phenotype of EDS is hypohidrotic ectodermal dysplasia (HED), which affects around one out of every 100,000 infants. Hypohidrosis, hypotrichosis, and partial anodontia are the most prevalent symptoms of ED syndrome. Frontal bossing, sunken cheeks, saddle nose, thick, everted lips, wrinkled, hyperpigmented skin around the eyes, and wide, low-set ears are all common facial features of ED^(2, 3).

The impact on the oral and maxillofacial region includes decreased growth of the mandible and maxilla, deficient development of the maxillary and mandibular alveolar ridges, significant reduction in salivary secretions, and malformations of shape of primary and permanent teeth such as conical or pegged teeth, hypodontia or complete anodontia, and delayed eruption of permanent teeth⁽⁴⁾.

It is a major challenge for the dental professional to make a treatment plan for HED children because many factors such as patient's age, stage of growth in conjunction with the missing teeth, soft tissue defects, existence of malformed dentition, and psychological status needed to be considered before rehabilitations. There are multiple treatment options for this condition, but the most frequent prosthetic treatment of ED in young patients is removable prosthodontics till the age of adolescence (13 to 18 years)⁽⁵⁾.

When patient enters into the age of adult (above 18 years), the definitive rehabilitation like fixed restorations plays a major role. After considering the patients socioeconomic status and clinical condition both full arch fixed veneer crowns as well as implant supported fixed restorations can be fabricated. The aim of this report is to present a comprehensive, complete, multidisciplinary approach to rehabilitation of a young adult patient with ED by implant-supported full arch fixed prosthesis. The degree of dentoalveolar tissue deficiency can make an implant-supported prosthesis an appropriate method of definitive occlusal restoration in these patients.

Case presentation

A 19-year-old female reported to the Department of Prosthodontics with the chief complaint of non-eruption of her permanent teeth which leads to unaesthetic appearance. Her expectation was to achieve a normal smile. The past medical history revealed that she had been diagnosed with hypohidrotic ED since her early childhood.

Case examination

On extraoral examination, she had dry skin, sparse thin hair on the scalp and eyebrows and prominent lips. On intraoral examination, patient had partial anadontia with decreased vertical height and underdeveloped alveolar ridges. On hard tissue examination, mixed dentition was observed and deciduous teeth (52,53,62,63,71,72,73,75,81,82,83,84,85) were present and permanent teeth (11,21,14,24,34,44) were present. Few conical and peg shaped deciduous teeth were also noted. On soft tissue examination, pale gingiva was seen. On palpation, the edentulous area has reduced residual alveolar height and width due to functional alveolar atrophy (Fig 1. A,B&C).

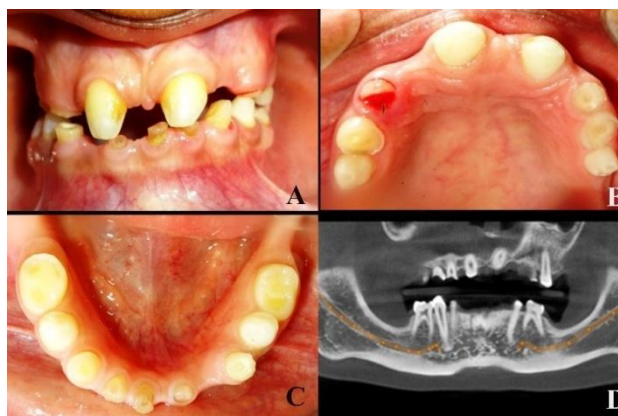


Figure 1: A. Pre-operative intraoral view B. Maxillary occlusal view C. Mandibular occlusal view D. CBCT of maxilla and mandible

Treatment plan

Patient was given different treatment options like fixed partial crowns, implant supported prosthesis, conventional removable prosthesis and overlay dentures. Since patient wanted natural appearance, patient was advised for implant supported fixed restoration. Preoperative CBCT was taken to assess the bone quality and quantity, proximity to anatomical landmarks and relation of tooth/teeth to adjacent side (Fig 1.D). To evaluate the growth, lateral cephalogram and hand radiography were taken. After CBCT evaluation and also considering patient's desire for immediate replacement, the treatment plan envisioned was basal implant placement with immediate loading

protocol to restore function, esthetics and health of the stomatognathic structure which also precludes a supplementary surgical site for graft extraction if required around implant followed by rehabilitation with fixed full veneer prosthesis over it after required tooth preparation on remaining permanent dentition. The treatment plan was explained to the patient and informed consent taken.

Pre-surgical phase

Patient was asked to undergo routine medical examinations like complete blood count, blood pressure, blood sugar levels. After evaluating CBCT, four basal implants in the maxillary arch and five basal implants in mandibular arch were planned.

Surgical phase

Local anesthesia with 2% lidocaine and 1:100,000 adrenaline (XicaineR, ICPA Health Products Ltd., India) was administered in both the maxillary and mandibular arch. Extractions of retained deciduous teeth, 73 to 83 with respect to mandibular arch and 52,53,62,63 with respect to maxillary arch with poor prognosis were done atraumatically to preserve the buccal and lingual cortical bone. Since the alveolar ridge was compromised, a flapless implant surgery was planned. The drilling protocol was initiated immediately after extraction and placement of single piece cortical compressive basal implant (GenXT implants) by flapless surgery with respect to 12, 15, 23, 25, 31, 33, 36, 42 and 46 was done. The remaining extracted site was compressed manually to approximate the marginal gingiva and compaction of alveolar bone. The postoperative instructions and appropriate oral antibiotics and IM analgesics were given. After 1 hour patient was again re-evaluated for bleeding or pain to initiate the prosthetic phase (Fig 2 & 3).

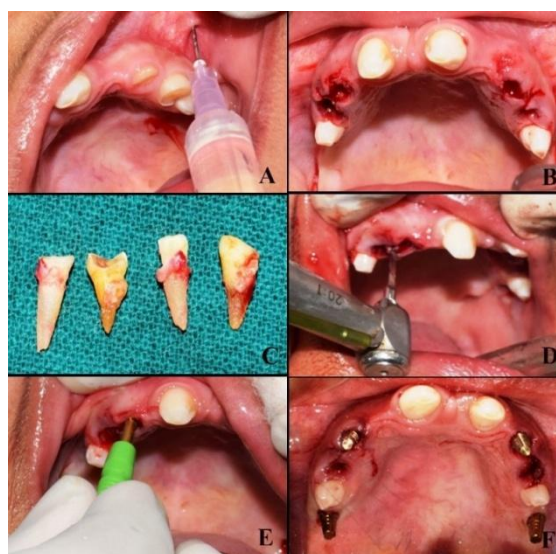

Figure 2: Maxillary implant placement A. Administration of local anesthesia B & C. Extraction of deciduous teeth D. Implant drilling E. Implant placement F. Intraoral occlusal view after implant placement

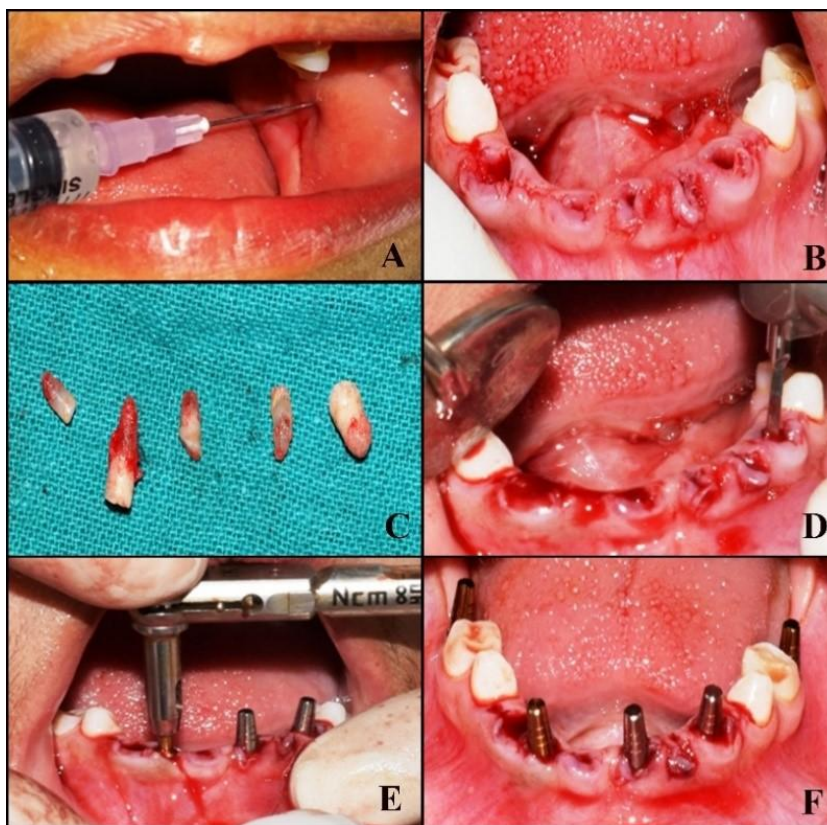


Figure 3: Mandibular implant placement A. Administration of local anesthesia B & C. Extraction of deciduous teeth D. Implant drilling E. Implant placement F. Intraoral occlusal view after implant placement

Prosthetic phase

The tooth preparation were initiated in the remaining permanent teeth (11, 21, 14, 24, 34, and 44) and deciduous teeth (75, 85) with the minimal occlusal and axial reduction (0.5mm and 0.9mm respectively) with a moderate chamfer finish line margin. After placing gingival retraction cord around the prepared teeth and closed tray impression copings over implants, impressions were made by closed tray technique using putty and light body polyvinyl siloxane impression material (Avue Gum Putty & Light Body: Hydrophilic Vinyl Polysiloxane Impression Material) immediately after the surgery. The impression was poured using type II dental stone (KalabhaiKalrockDiestone: Dental Stone Class IV). Facebow record was transferred to a semiadjustable articulator and both the maxillary and mandibular cast was articulated. The metal coping framework was fabricated by conventional waxup, de-waxing and casting (Fig 4. A, B&C).

On second day metal coping trial was performed satisfactorily, followed by bite registration with polyether impression material (Fig 4. D&E). The porcelain layering, firing, glazing, finishing and polishing were done conventionally. On day 3, all implants were functionally loaded by cement retained metal fused to porcelain prosthesis using glass ionomer cement (GIC) with respect to

maxillary arch extending from 15 to 25 and in mandibular arch extending from 36 to 46 with mutually protected occlusion (Fig 4. F). Since the patient need natural look, a mild diastema was left in the midline.

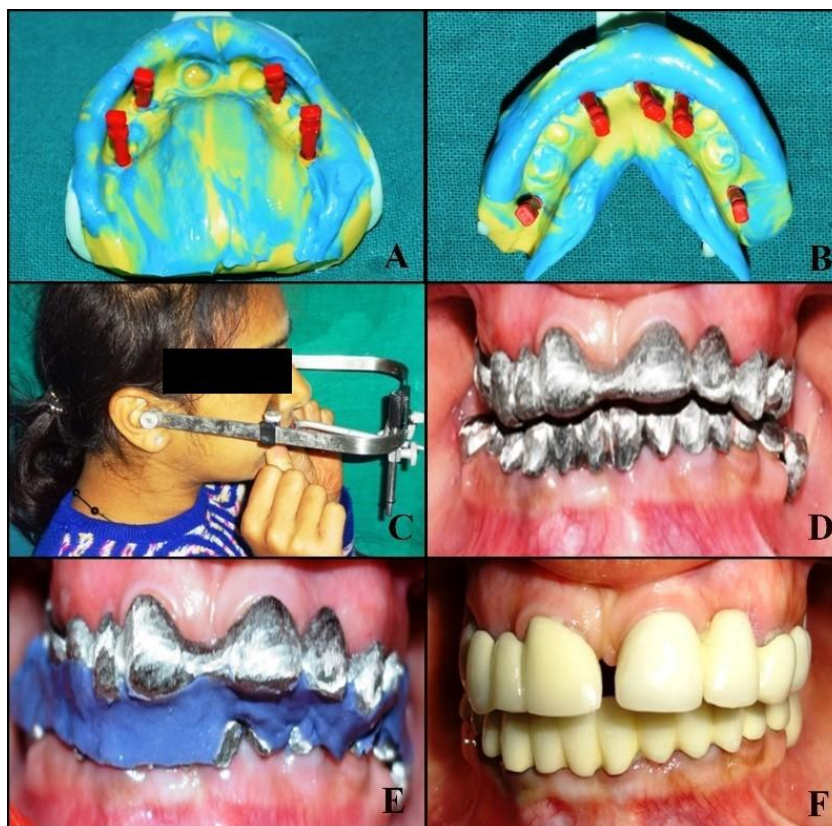


Figure 4: Prosthetic phase A. Maxillary impression B. Mandibular impression C. Facebow transfer
D. Metal framework trial E. Inter-occlusal record F. Final prosthesis in situ

Post-rehabilitative instructions

Postoperative instructions were given to the patient and a panoramic radiograph was taken. Patient was educated and motivated for maintenance of good oral hygiene and regular follow up of 1st week, 1st, 3rd and 6th month. After 6th month, all the implant was successful with no loss of stability. On radiological evaluation, osseointegration was accomplished in all 9 implants with no crestal bone loss. The patient was satisfied with rehabilitation in terms of function, speech and esthetics. Most importantly she has transposed to a confident individual after attaining a normal natural look and smile as she had desired (Fig 5. A,B&C).

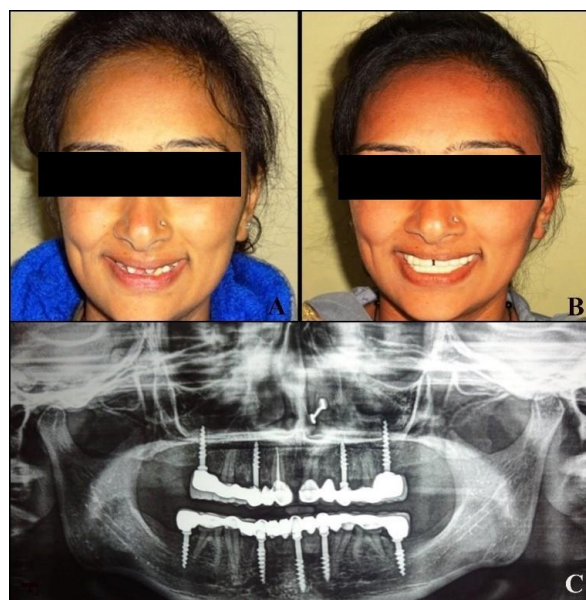


Figure 5: A. Pre-rehabilitative view B. Post-rehabilitative view C. Post-rehabilitative view

Discussion

Individuals and families suffering with a child diagnosed with ED may struggle to get enough assistance or information in order to fully understand the disorder and also to choose appropriate medical and dental examinations and treatment plan for rehabilitation ⁽⁶⁾. The main problem with these patients are lack of teeth and alveolar bone remaining, particularly in the maxilla. Most of these patients are diagnosed in their childhood and removable prosthesis would be the commonest treatment option for initial period until the growth of the children is complete. But, the definitive treatment plan after growth should be individualized and depends on various factors like patient's age, medical history, teeth present, quantity and quality of edentulous alveolar ridge available, esthetics and the patient's attitude ^(7, 8). Hence the definitive rehabilitation would require pre-prosthetic surgeries like bone augmentation, bone grafting which will be time consuming and causes discomfort to the patient due to senile appearance and social exclusion.

The definitive treatment options include fixed partial bridges and implant supported prosthesis. Fixed partial dentures are not possible due to a smaller number of remaining teeth to support the full arch rehabilitation. The implant supported prosthesis is a better alternative treatment modality as it gives natural appearance and enhance the masticatory function and esthetics, compared to the conventional removable prosthesis which would have a psychological impact on patient ^(9, 10). The administration of conventional endosseous implants often compels complex surgical procedures prior to implant placement, including alveoloplasty, sinus lift, and bone grafting. Also these implants had limited options for length and diameter to meet the requirements for all individual oral conditions because of retarded growth of alveolar bone. It also involves loading the implants after

4-6 months of placement leaving the patient with edentulism for considerable duration ⁽¹¹⁾.

The present case report describes a novel technique to use basal implants for full mouth rehabilitation of an ED patient with maxillary and mandibular oligodontia, and severe atrophy of the residual alveolar ridge. Basal implants are bicortical implants which utilizes the basal cortical portion of the jaw bones as they are highly dense and less prone to resorption which offers excellent retention and support to implants. It can be used to support single and multiple unit restorations, and can be placed immediately in the extraction sockets and also in healed bone ⁽¹²⁾. Compared to conventional implants they are narrow in diameter which allows placement in compromised ridges. It also provides other advantages like they can be placed with flap or flapless technique, bypass the mandibular nerve canal easily and for engagement of the cortical bone at the fusion of the pterygoid with the maxilla. The angulation of abutments can also be adjusted up to 15° relative to the implant axis which will avoid the use of multi-unit abutments. Immediate loading of implant with definitive prosthesis can be done as they attain excellent primary stability because of placement in basal bone. But still bone remodelling begins within 72 hours and weakens the peri-implant bone structures, hence metal framework should be fabricated for rigid splinting which will disseminate the masticatory forces from the bone around the implants to other cortical areas as well ⁽¹³⁾.

Conclusion

The ectodermal dysplasia patients usually present with oligodontia (absence of 6 or more teeth) or anodontia (complete absence of teeth), and a prosthetic rehabilitation is usually necessary. A high survival rate (20-year CSR 84.6%) has been observed when dental implants were placed in ED patients, either infants or adults. The definitive treatment plan includes various options like removable, fixed, or implant-supported prostheses or a combination of these options. Based on the remaining alveolar bone availability and the pattern of missing teeth, implants are considered to be the the ideal treatment option for an adult ED patient. A case of rehabilitation of complex partial anodontia has been successfully presented. For the successful treatment planning for a patient with hereditary hypohidrotic ED, a multidisciplinary approach has proved to be necessary. Full mouth rehabilitation improved the function, esthetics and psychological confidence of the patient.

Consent

As per international standard or university standard, patient's written consent has been collected and preserved.

Conflict of Interests

The authors do not have any financial interests in the products or information listed in this case

presentation.

Acknowledgements: Nil.

References

1. Robert Baran, David A. R. de Berker, Mark Holzberg, Bianca Maria Piraccini, Bertrand Richert, Luc Thomas. Baran and Dawber's Diseases of the Nails and their Management. 4 th ed. North America: John Wiley & Sons 2012. p. 220
2. Li S, Xiao X, Wu R, Zeng B, Yu D. Early prosthetic treatment of children with hypohidrotic ectodermal dysplasia: six case reports. *Int J Oral Dent Health*. 2017;3(1):039.
3. Deshmukh S, Prashanth S. Ectodermal dysplasia: a genetic review. *Int J Clin Pediatr Dent*. 2012;5(3):197-202.
4. William G Shafer, Maynard K Hine, Barnet M Levy. A Textbook of Oral Pathology. 7th ed. Philadelphia: Saunders; 1983. p. 805-806.
5. Hussain M, Yazdanie N. Treatment modalities for ectodermal dysplasia patients at a tertiary care hospital. *J Pak Dent Ass*. 2013;22(04):241.
6. Machado M, Wallace C, Austin B, Deshpande S, Lai A, Whittle T et al. Rehabilitation of ectodermal dysplasia patients presenting with hypodontia: outcomes of implant rehabilitation part 1. *J Pros Res*. 2018;62(4):473-8.
7. Smith RA, Vargervik K, Kearns G, Bosch C, Koumjian J. Placement of an endosseous implant in a growing child with ectodermal dysplasia. *Oral Surg Oral Med Oral Pathol*. 1993;75(6):669–73.
8. Bryant SR. The effects of age, jaw site, and bone condition on oral implant outcomes. *Int J Prosthodont*. 1998;11(5):470–90.
9. Wang Y, He J, Decker AM. Clinical outcomes of implant therapy in ectodermal dysplasia patients: a systematic review. *Int J Oral Maxillofac Surg* 2016;45:1035-1043.
10. Rathee M, Bhorla M. Basics of clinical diagnosis in implant dentistry. *J Int Clin Dent Res Org*. 2015;7(3):13.
11. Koyuncuoglu CZ, Metin S, Saylan I. Full mouth rehabilitation of a patient with ectodermal dysplasia with dental implants. *J Oral Implantol*. 2014;40:714-721.
12. Rathee M, Malik S, Jain P, Kaushik S. Basal implants: an alternative treatment modality for geriatric patients - a case report. *J West Bengal Univ Health Sci*. 2020;1(1):85-89.
13. Ghozeizi R, Siadat H, Nikzad S, Shabestari GO, Shayesteh YS. Full mouth rehabilitation of an ectodermal dysplasia patient with implant-supported prostheses: a clinical report. *J Dent (Tehran, Iran)*. 2013 May;10(3):283.