

Fungal Corneal Ulcer Successfully Treated with Topical Fluconazole and Natamycin, and Additional Amniotic Membrane Transplantation: A Case Report

Hanna Aulia Namirah, Hasnah Eka, Junaedi Sirajuddin

Department of Ophthalmology, Faculty of Medicine, Hasanuddin University,
Hasanuddin University Teaching Hospital, Makassar, Indonesia

Abstract

A fungal corneal ulcer, is an infection of the corneal stroma that can cause rapid vision loss and pain. It needs to be treated as soon as possible to preserve vision (Kulkarni et al., 2017). It may be caused by filamentous (*Fusarium* or *Aspergillus species*) or non-filamentous fungi (*Candida species*). American Academy of Ophthalmology, 2016). Case Illustration show a 33-year-old man complaint about having pain and redness on the right eye for the last 3 weeks. The black area suddenly whitened two days later and became wider. Hyperlacrimation, discharge, and glare also exist. No known history of previous trauma. His best-corrected visual acuity (BCVA) was 1/300. Slit-lamp examination revealed an oval-shaped corneal defect at a central zone sized of 5x7.5 mm, grayish-white, dry-appearing stromal infiltrate that has regular feathery margins, ring ulcer, positively fluorescence test, and minimal hypopyon. Fungal septate hyphae are seen on gram staining. He treated with oral ketoconazole, topical fluconazole and natamycin, atropine as a cycloplegic, and additional AMT. Visual acuity then improved and the ulcer became cicatricial in one month. Our case is typical for fungal corneal ulcer by its presentation and microbiological examination. Known for its long and protracted course, there is no definitive therapy established yet and each antifungal agent has its benefits and limitations. However, in our patient, oral administration of ketoconazole, topical natamycin and fluconazole, and AMT for adjunction, had succeeded in eliminating the infection and showing significant changes. Our case reported that a fungal corneal ulcer is successfully treated with combination of topical natamycin and fluconazole and additional AMT.

Keywords: *fungal corneal ulcer, fungal keratitis, fluconazole, natamycin, amniotic membrane transplantation*

INTRODUCTION

A fungal corneal ulcer, or fungal keratitis, is an infection of the corneal stroma that can cause rapid vision loss and pain. Infectious corneal ulcers need to be treated as soon as possible to preserve vision. If left untreated, a fungal infection can lead to perforation of the cornea, loss of vision, and even loss of the eye. The causative fungal species of keratomycosis are ubiquitous organisms (Kulkarni et al., 2017). Fungal keratitis may be caused by filamentous (*Fusarium* or *Aspergillus species*) or nonfilamentous fungi (*Candida species*) (American Academy of Ophthalmology, 2016).

Of the organism that causes keratitis, fungi remain one of the most elusive and challenging organism to diagnose and treat. It has also been shown that infection with fungal keratitis can be more virulent and damaging compared to that of a bacterial origin. Fungal keratitis in the previous retrospective analysis was shown to be more likely to perforate the cornea than bacterial keratitis and lead to irreversible changes (Ansari et al., 2013). Corneal infections are of

exogenous origin, usually as a result of the trauma by the implementation of organic material of plant origin contaminated with microscopic fungi (mycelial fragments, spores) into the surface layers of the eye. If keratitis is not adequately and promptly treated, deeper tissues can be affected and that can lead to damage or even loss of vision (Buchta et al., 2019).

Diagnosis of keratomycosis is based on relatively nonspecific clinical features and microbiological investigation of biological material by classical microscopic and culture techniques, recently supplemented by detection of fungal DNA (PCR, sequencing) (Buchta et al., 2019). A review published in 2012 found no evidence that any particular drug or combination of drugs is more effective than the other in managing fungal keratitis.

Treatment of eye infections is generally cumbersome, long-lasting and not always optimal. One reason is that some filamentous fungi have atypical or variable susceptibility to antimycotics. Additionally, choices of antimycotics are limited in terms of the appropriateness of drug formulation with corresponding pharmacokinetics to ensure adequate availability of the drug in the affected eye structures (Buchta et al., 2019).

CASE REPORT

A 33-year-old man presented with the main complaint of pain in the right eye that had been experienced in the last 3 weeks. Initially, the eye appeared to be reddish and 2 days later, it began to appear whitened in the dark part of that eye. The whitening widened progressively. He also complained about having excessive tears, excessive eye discharge, and glaring vision. There is no known history of previous trauma. History of systemic diseases was denied as well as the history of using glasses. This patient works as a janitor in an office but also works outdoor sometimes. It is assumed that the patient had been exposed to the pathogen at work.

His best-corrected visual acuity (BCVA) was 1/300. Slit-lamp examination revealed found oval-shaped corneal defect at central zone sized 5x7.5 mm, appeared grayish-white, dry-appearing stromal infiltrate that has regular feathery margins, ring ulcer, positively fluorescence test, and minimal hypopyon (less than 1 mm) in the anterior chamber, van Herrick criteria grade 2-3, and brown iris. Other details were difficult to evaluate obstructed by turbidity of the refractory media. Corneal scraping with Gram staining showed of septate hyphae fungal and polymorphonuclear cells. No bacteria were found in the staining. Other techniques, such as potassium hydroxide (KOH) and cultivation, were not performed because of a lack of sufficient material.

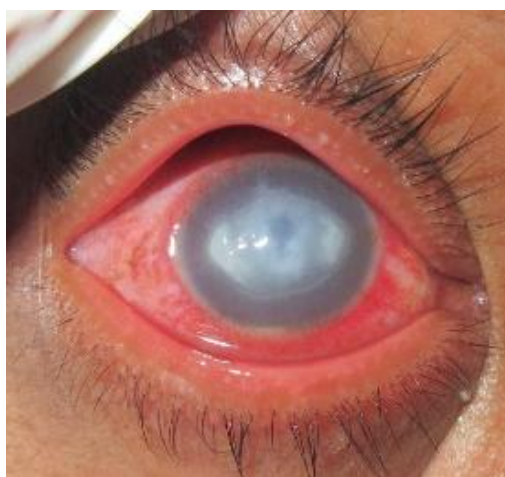

Figure 1. The picture shows an oval-shaped central corneal ulcer with ring ulcer, feathery stromal infiltration, and minimal hypopyon. This picture was taken when the patient initially presented to us.

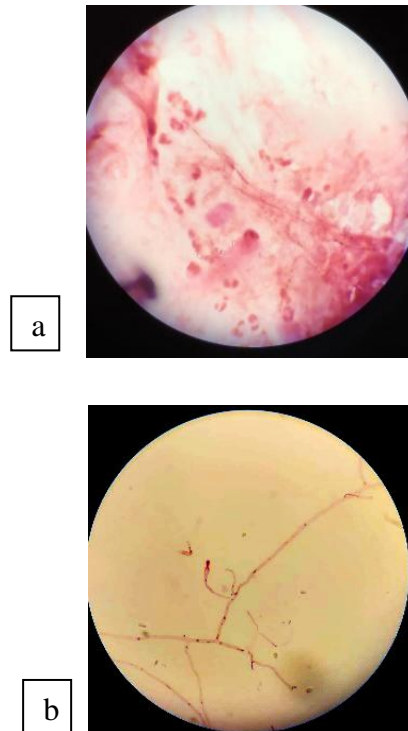
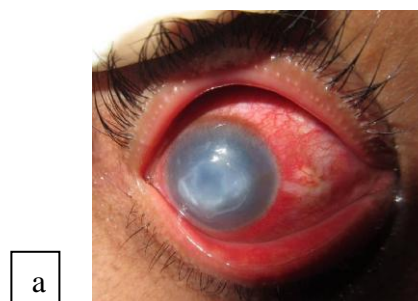

Figure 2. The gram staining of this patient shows lots of polymorphonuclear cells and septate hyphae fungal (magnification 40x (a) and 100x (b))

Based on history, slit-lamp examination, and laboratory findings, the patient was treated with initial therapy such as oral ketoconazole 100 mg twice daily, topical fluconazole one drop every hour, topical natamycin one drop every hour, and cycloplegic twice daily. The topical fluconazole was prepared from an intravenous fluconazole bottle and given without any dilution (200mg/100ml or 2mg/ml).

On the sixth day after initial therapy, the patient was followed up. Visual acuity still the same, 1/300, conjunctival injection had been slightly subsided, the size of the defect had been slightly reduced to 5x6.8 mm, and no more hypopyon (Fig.3). The initial treatment regimen was continued but with less frequent topical antifungal therapy (from once every hour to four times daily). Amnion membrane transplantation (AMT) and bandage soft contact lens (BSCL) were then applied on the 14th days after initial therapy, with a multilayer sandwich technique.



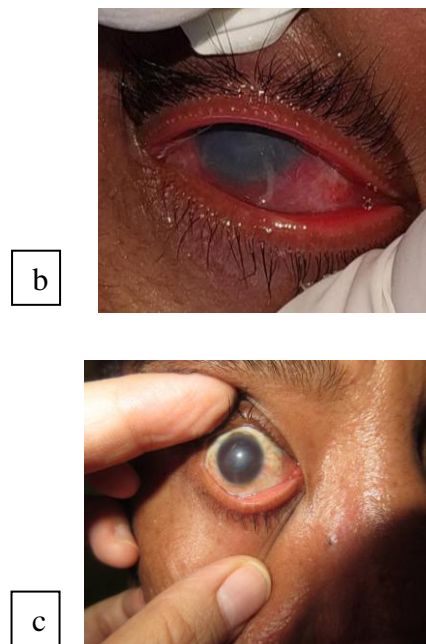

Figure 3.

- a. Fungal corneal ulcer after 6 days of initial treatment. No more hypopyon, reduced size of the corneal defect, and conjunctival injection had been slightly subsided.
- b.

b. Day 1 after AMT and BSCL application.

c. Day 22 after AMT and BSCL application, day 42 after initial therapy. The ulcer became cicatricial and neovascularization had been noted.

On the 26th day after the initial therapy, visual acuity was 1/60. The stromal infiltration subsided gradually, complete epithelization and neovascularization were noted. The topical natamycin and atropine were discontinued but the fluconazole eye drops and artificial tears were still continued. Central corneal opacity still exists on the 42nd day as cicatricial, and the BCVA was 20/80F.

DISCUSSION

The causative fungal species of keratomycosis are ubiquitous organisms, which are responsible for 6-53% of all corneal infections globally. These kinds of infections are frequently encountered resulting in visual disability, especially in tropical countries. Corneal opacification following different kinds of infections is the second most common cause of blindness after cataract (Kulkarni et al., 2017).

The filamentous fungi are responsible for up to one-third of all cases of keratitis in certain parts of the world. *Aspergillus* and *Fusarium* are responsible for one-third of all traumatic keratitis. Other fungal genera which also can cause infections include, *Curvularia*, *Candida*, *Acremonium*, *Paecilomyces*, *Penicillium*, *Alternaria*, *Fonsecaea*, *Pseudallescheria*, *Bipolaris*, *Aureobasidium* (Kulkarni et al., 2017).

Patients with fungal keratitis tend to have fewer inflammatory signs and symptoms during the initial period than those with bacterial keratitis and may have little or no conjunctival injection upon initial presentation. On the other hand, pain in fungal keratitis can be out of proportion to the relatively uninflamed cornea. Filamentous fungal keratitis frequently manifests as a gray-white, dry-appearing infiltrate that has irregular feathery or filamentous margins. Superficial lesions may appear gray-white; elevate the surface of the cornea; and have a dry,

rough, or gritty texture detectable at the time of diagnostic corneal scraping. Occasionally, multifocal or satellite infiltrates may be present, although these are less common than previously reported. Also, a deep stromal infiltrate may occur in the presence of an intact epithelium. An endothelial plaque and/or hypopyon may also occur if the fungal infiltrate(s) is sufficiently deep or large or has penetrated the anterior chamber (American Academy of Ophthalmology, 2019). The amount of decreased vision depends on the location of corneal infiltrate regarding the visual axis, the degree of anterior chamber reaction, and the presence of secretions (Mahmoudi et al., 2018). In this patient the ulcer appearance is typical for fungal keratitis, but with a regular feathery margin, and without satellite lesions. Unfortunately, the lesion location at the central zone obstructs the visual axis, so that complaints of vision became more severe.

The gold standard of laboratory diagnosis is still the routine microbiological method including microscopic examination and culture. Direct microscopic examination of a corneal scraping sample provides great information for diagnosis immediately (Ortega-Rosales et al., 2019). The common approach in patients with suspected infectious keratitis is, to begin with a Gram staining of the corneal scraping material. Studies have shown the sensitivity of Gram staining to be in the range of 36–50 %. Next, wet preparation of the corneal scraping can be examined by potassium hydroxide (KOH), ink-KOH, lactophenol cotton blue, Giemsa, or calcofluor white. KOH is a rapid and inexpensive way to detect fungi with 61–94 % and specificity of 91–97 % of detecting fungal keratitis in different studies (Ansari et al., 2013). In this patient, we conducted Gram staining and it showed septate hyphae which mean that filamentous fungi existed in the sample. Ideally, we should do a KOH staining consider its higher sensitivity and specificity. We didn't do the examination because of the insufficient material. We realize that it becomes the limitation of our study. Even so, the results of gram staining still revealed clear imaging of a type of fungal. Also, when we did a culture examination, unfortunately, the microorganism did not grow due to insufficient corneal scrapping material. A study showed that excessive scraping should be avoided as scarring may occur and thus worsen the BCVA at 3 months (Ansari et al., 2013).

Some studies report that fungal corneal ulcer is difficult to treat and often has a long, protracted course (American Academy of Ophthalmology, 2016). In treating it, each antifungal agent has its benefits and limitations. Careful considerations must be made before the selection of an antifungal agent. No single agent has emerged as the best and most cost-effective treatment (Ansari et al., 2013).

Azoles (including ketoconazole and fluconazole) inhibit ergosterol synthesis at lower concentrations, and, at higher concentrations, they appear to cause direct damage to cell walls. Oral fluconazole and ketoconazole are absorbed systemically with good levels in the anterior chamber and the cornea; therefore, they should be considered in the management of deep fungal keratitis. High cornea levels of ketoconazole and fluconazole have been demonstrated in animal studies. Because of excellent penetration in ocular tissue, these medications, given systemically, are the preferred treatment of keratitis caused by filamentous fungi and yeast (Ross, 2019). However, some studies show that fluconazole is limited by its narrow effectiveness on the filamentous organism, and not as potent as combating yeasts like *Candida* (Ansari et al., 2013; Li et al., 2016). In this patient, we provide oral ketoconazole and topical fluconazole for the deeper stromal infiltration so that drug penetration can be maximized.

Polyenes (including Natamycin) disrupt the cell by binding to fungal cell wall ergosterol and are effective against both filamentous and yeast forms. Natamycin is the only commercially available topical ophthalmic antifungal preparation. It is effective against filamentous fungi,

particularly for infections caused by *Fusarium* (Ross, 2019). Though natamycin tends to be the first-line treatment in areas where *Fusarium* is endemic, it is limited by its inability to cover for other fungal organisms such as *Candida*. This limits the use of natamycin to treatment for superficial fungal keratitis as opposed to deep stromal fungal invasion. The presence of deep lesions may necessitate the addition of systemic therapy, such as oral ketoconazole (Ansari et al., 2013).

The previous study comparing the efficacy of the combination of topical natamycin-fluconazole versus natamycin alone concludes that the treatment efficacy of the combined therapy of natamycin 5% eye drops and fluconazole 0.3% is better than the monotherapy with natamycin 5% alone. This is due to the ability of fluconazole to penetrate into the deeper corneal layers as compared to natamycin which acts at a more superficial layer of the cornea. Combined therapy, hence, provides an additive effect or rather a synergistic effect rather than a monotherapy with natamycin alone (Koul et al., 2018).

The amniotic membrane (AM), is recognized as an effective material that can availably restore integration of the ocular epithelium and prevent corneal perforation. What makes the AM play a therapeutic role is its special 3-layer structure (from inside to outside: the epithelial layer, the thick basement membrane, and the avascular mesenchymal tissue) and its biological viability (anti-inflammatory, antibacterial, antiviral, low immunogenicity, antiangiogenic, and proapoptotic). A meta-analysis study demonstrated that AMT should be considered an effective alternative, which can effectively rebuild the corneal surface and, in a manner, improve patients' vision after corneal ulceration (Liu et al., 2019). We applied AMT to this patient as an adjuvant therapy with the aim of re-epithelization. We used a multilayer sandwich technique instead of an inlay or overlay technique, to fill the defect at the central region and cover the corneal surface.

The therapy given to this patient has succeeded in eliminating the infection and showing significant changes so far. However, corneal cicatricial that occurs after corneal healing, make the visual acuity still not maximized. Therefore, keratoplasty might be considered as a follow-up treatment.

CONCLUSION

Fungal keratitis, though seemingly straightforward, is a complex entity with many considerations when it comes to diagnosis and treatment. With the establishment of an appropriate diagnosis and the provision of effective and timely therapy, better results can occur and complications can be avoided. As seen on this patient, the combination of topical fluconazole and natamycin, associated with AMT is effective in the treatment of fungal corneal ulcers, generating a significant visual acuity improvement.

REFERENCES

1. Kulkarni, V. L., Kinikar, A. G., Bhalerao, D. S., & Roushani, S. (2017). A case of keratomycosis caused by *Fusarium solani* at rural tertiary care center. *Journal of clinical and diagnostic research: JCDR*, 11(9), DD01.
2. American Academy of Ophthalmology. (2016). Fungal Keratitis – Europe. October 2016. Available from: <https://www.aao.org/topic-detail/fungal-keratitis-asia-pacific>
3. Ansari, Z., Miller, D., & Galor, A. (2013). Current thoughts in fungal keratitis: diagnosis and treatment. *Current fungal infection reports*, 7(3), 209-218.

4. Buchta, V., Nekolová, J., Jirásková, N., Bolehovská, R., Wipler, J., & Hubka, V. (2019). Fungal keratitis caused by *colletotrichum dematium*: case study and review. *Mycopathologia*, 184(3), 441-453.
5. American Academy of Ophthalmology. (2019). *External Disease and Cornea*. Basic and Clinical Science Course 2019-2020. Chapter 10, p. 295-7
6. Hange, V. (2020). The Invasive Lower Lip Squamous Cell Carcinoma Mimicking Traumatic Fibroma: Case Report: CASE REPORT. *Journal of Scientific Research in Medical and Biological Sciences*, 1(2), 133-139. <https://doi.org/10.47631/jsrmb.v1i2.40>
7. Mahmoudi, S., Masoomi, A., Ahmadikia, K., Tabatabaei, S. A., Soleimani, M., Rezaie, S., ... & Banafsheafshan, A. (2018). Fungal keratitis: An overview of clinical and laboratory aspects. *Mycoses*, 61(12), 916-930.
8. Ortega-Rosales, A., Quizhpe-Ocampo, Y., Montalvo-Flores, M., Burneo-Rosales, C., & Romero-Ulloa, G. (2019). A case of fungal keratitis due to *Fusarium solani* after an indigenous healing practice. *IDCases*, 18, e00618.
9. Ross, M. (2019). *Fungal Keratitis Treatment & Management*. Medscape.
10. Li, P. H., Chen, C. C., & Liou, S. W. (2016). Candida parapsilosis keratitis treated successfully with topical and oral fluconazole. *Taiwan journal of ophthalmology*, 6(3), 155-157.
11. Koul P., Padha A., Sharma S. (2018). Comparison of the Efficacy of Topical Natamycin 5% and Fluconazole 0.3% Eye Drop Therapy versus Topical Natamycin 5% alone in Deep Fungal Keratitis in Gharwal Region of Uttarakhand, India. *International Journal of Scientific Study*.
12. Liu, J., Li, L., & Li, X. (2019). Effectiveness of cryopreserved amniotic membrane transplantation in corneal ulceration: a meta-analysis. *Cornea*, 38(4), 454-462.